

Autoantibodies in Childhood Post-Varicella Acute Cerebellar Ataxia

Coleen Adams, Paola Diadori, Leeanne Schoenroth, Marvin Fritzler

ABSTRACT: Background: Anti-Purkinje cell antibodies have been reported in cerebellar ataxia following Epstein-Barr virus (EBV) infection. We investigated autoantibody responses, including anti-Purkinje cell antibodies, and the clinical course in eight children who developed post-varicella ataxia, five of their siblings with uncomplicated varicella, one child with post-EBV ataxia, two children with acute disseminated encephalomyelitis (ADEM) and one with neuroblastoma associated ataxia, and in age and gender matched controls. **Methods:** Autoantibodies were tested by indirect immunofluorescence (IIF) on cryopreserved cerebrum and cerebellum sections. Other autoantibodies were measured by conventional IIF protocols using HEP-2 cells as a substrate. Antibodies to myelin associated glycoprotein (MAG), asialo-GM1, β 2 glycoprotein 1, cardiolipin and myelin basic protein (MBP) were measured by ELISA. **Results:** Three of eight children with acute post-varicella ataxia, one child with post-EBV ataxia, one child with ADEM and one child with uncomplicated varicella, had high titer autoantibodies ($>1/160$) that reacted with cerebrum and cerebellar tissue. This reactivity was not seen in one child with ADEM, in one with neuroblastoma and ataxia, in the remainder of the children with uncomplicated varicella or age and gender matched controls. Autoantibodies were not seen in CSF from two children with post-varicella ataxia. The punctate staining seen on cerebrum and cerebellum sections co-localized with rabbit antibodies to the centrosome protein pericentrin. All patients with strong reactivity with cerebrum and cerebellar tissue by IIF had elevated levels of anti-MAG that was not confirmed by absorption assay. No reactivity was seen with asialo-GM1, MBP, β 2 glycoprotein 1 or cardiolipin. None of the sera had autoantibodies directed against endosomes, the Golgi complex, or the paraneoplastic autoantigens Hu and Yo. **Conclusion:** Some children with post-viral ataxia develop antibodies that have strong reactivity with cerebral and cerebellar tissue. Some of the antigenic reactivity co-localized with the centrosome protein pericentrin.

RÉSUMÉ: Autoanticorps dans l'ataxie cérébelleuse aiguë post-varicelle de l'enfance. Introduction: Des anticorps dirigés contre les cellules de Purkinje ont été rapportés dans l'ataxie cérébelleuse suite à une infection par le virus d'Epstein-Barr (EBV). Nous avons évalué la réponse immunitaire, incluant les anticorps dirigés contre les cellules de Purkinje, et l'évolution clinique de huit enfants qui ont développé une ataxie suite à la varicelle, cinq membres de leur fratrie qui présentaient une varicelle sans complication, un présentant une ataxie post-EBV et un ayant une ataxie associée à un neuroblastome. **Méthodes:** Les autoanticorps ont été détectés par immunofluorescence indirecte (IIF) sur des coupes de cerveau et de cervelet congelées. D'autres autoanticorps ont été mesurés par des protocoles IIF conventionnels utilisant des cellules HEP-2 comme substrat. Les anticorps dirigés contre la glycoprotéine associée à la myéline (MAG), l'asialo-GM1, la β 2 glycoprotéine 1, la cardioline, les protéines basiques de la myéline (PBM) ont été mesurés par ELISA. **Résultats:** Trois des huit enfants ayant présenté une ataxie aiguë suite à la varicelle, un enfant ayant présenté une ataxie post-EBV, un enfant ayant présenté une encéphalomyélite disséminée aiguë (EMDA) et un enfant ayant présenté une varicelle sans complication avaient des titres élevés d'autoanticorps ($>1/160$) qui réagissaient avec le tissu cérébral et cérébelleux. Cette réactivité n'était pas observée chez un enfant présentant une EMDA, chez un enfant présentant un neuroblastome et une ataxie, chez les enfants présentant une varicelle sans complication et chez des contrôles appariés pour l'âge et le sexe. Les autoanticorps n'ont pas été observés dans le LCR de deux enfants présentant une ataxie suite à la varicelle. La coloration ponctiforme observée sur les tissus cérébraux et cérébelleux avait la même localisation que les anticorps de lapin dirigés contre la péricentrine, une protéine du centrosome. Tous les patients ayant une forte réactivité avec les tissus cérébraux et cérébelleux par IIF avaient des niveaux élevés d'anti-MAG qui n'ont pas été confirmés par un test d'absorption. Aucune réactivité n'a été observée avec l'asialo-GM1, les PBM, la β 2 glycoprotéine 1 ou la cardioline. Aucun des sérums ne contenait des autoanticorps dirigés contre l'endosome, le complexe de Golgi ou les autoantigènes paranéoplasiques Hu et Yo. **Conclusion:** Certains enfants qui présentent une ataxie post-virale développent des anticorps qui ont une forte affinité pour le tissu cérébral et cérébelleux. Une partie de la réactivité antigénique avait la même localisation que la péricentrine, une protéine du centrosome.

Can. J. Neurol. Sci. 2000; 27: 316-320

The pathogenesis of post-varicella cerebellar ataxia, a relatively benign neurological complication of chickenpox in children, is unknown. Anti-neuronal antibodies have been reported in a case of post-infectious cerebellar ataxia following Epstein-Barr viral (EBV) infection.¹ IgM and IgG antibodies that bind the cytoplasm of cerebellar Purkinje cells was reported in nine children with opsoclonus-myoclonus associated with neuroblastoma or with a prodromal viral illness.² In another study, two

children with ataxia and other central nervous system (CNS) manifestations following *Mycoplasma pneumoniae* infection

From the Alberta Children's Hospital and Faculty of Medicine, University of Calgary, Calgary, Alberta, Canada

RECEIVED NOVEMBER 1, 1999. ACCEPTED IN FINAL FORM JULY 25, 2000.

Reprint requests to: Coleen Adams, Alberta Children's Hospital, 1820 Richmond Rd SW, Calgary, Alberta T2T5C7 Canada

were found to have antibodies directed to centrioles.³ Patients with cerebellar ataxia and paraneoplastic cerebellar degeneration have antibodies to a Golgi-related antigen (Yo) that is primarily localized to Purkinje cells.^{4,5} Our laboratory has cloned several Golgi complex autoantigens and two of them, golgin-95 and golgin-160, reacted with autoantibodies from patients with idiopathic cerebellar ataxia.^{6,7}

Most children with post-infectious ataxia have a mild course, however some are more severely affected. If the mechanisms that lead to the development of post-infectious cerebellar ataxia are more completely understood, then a rational approach to treatment could be considered. We investigated the possibility that autoantibodies to Purkinje cells and specific cell constituents are associated with post-varicella acute cerebellar ataxia. If an auto-immune mechanism is found then immunomodulating therapeutic modalities could be considered.

METHODS

Patients

Children with chicken pox and subsequent cerebellar ataxia who presented to the emergency department, or were referred from pediatricians and family physicians between August 1995 and March 1997, were included in this study. Blood samples from the ataxic patients were obtained at the first assessment of ataxia and at a convalescent stage two weeks later. Control sera were drawn from several different groups including siblings of the ataxic patients who also had chicken pox but no neurological complications. Other children, as outlined in the results, also had blood drawn. Varicella serology included an enzyme linked immunoassay (ELISA) for IgG antibodies at onset and complement fixation titer at onset and two weeks later. The details of the clinical history and the findings on complete general and neurological examination were recorded in a standardized database. In particular, assessment of cerebellar function included documentation of nystagmus, head titubation, dysidiadochokinesis, dysmetria, limb ataxia and truncal ataxia. The latter was graded as: "mild" (unsteady or poor tandem gait), "moderate" (unable to perform tandem gait) or "severe" (unable to walk).

Serological methods

Serum for autoantibody analyses was drawn at the initial and second visit, and stored at -20°C. Age and gender matched control sera were from the serum bank in the Advanced Diagnostics Laboratory at the University of Calgary.⁸ Conventional immunofluorescence (IIF) was performed on commercially available HEp-2 cells (ImmunoConcepts Inc.) using a fluorescein-conjugated goat antihuman IgG (light and heavy chain) as previously described.⁹ Double-labeling and co-localization studies used rabbit antibodies to pericentrin to label centrosomes (Covance), a murine monoclonal antibody to the early endosome antigen EEA-1 (Transduction Laboratories), or a murine monoclonal antibody to the Golgi complex protein β -COP (Sigma).¹⁰ Slides were viewed on a Zeiss Universal microscope fitted with a TEC-470 CCD video camera system (Optronics Engineering) and images were processed with a Sony color video printer and recorded on Sony Type 1010 photography paper.

The reactivity of the patient sera was also tested on sections of monkey (Medica) and human (National Neurological Research Specimen Bank) cerebrum and cerebellum as described by Hawkes et al.¹¹ Autoantibodies directed against Hu and Yo antigens that immunoprecipitated the respective recombinant proteins were obtained from patients with paraneoplastic ataxia.¹²

Elisa

Antibodies to myelin associated glycoprotein (MAG), myelin basic protein (MBP) and asialo-GM1 were tested by ELISA using commercially available kits (Advanced Biological Products) and by following the supplier's protocol. Antibodies to cardiolipin and β 2-glycoprotein 1 were assayed by ELISA kits and protocol provided by Innova. To determine if staining of brain sections was due to anti-MAG activity, 500 μ l of sera were pre-adsorbed with purified MAG (Sigma) for one hour at 4°C, centrifuged at 5000 x g to remove precipitates and then retested by IIF.

Immunoprecipitation of recombinant proteins obtained by *in vitro* transcription and translation

To determine if antibodies in patients with post-infectious ataxia reacted with recombinant Golgi, endosome, Hu and Yo proteins, the recombinant proteins were produced by *in vitro* transcription and translation (TnT) of purified cDNAs and then used in immunoprecipitation (IP) studies as previously described.^{6,7}

Serological results

Eight children with post-varicella ataxia were enrolled in this study. The age range was four years to 11 years, six months (median seven years six months). Five siblings with uncomplicated chicken pox (including one monozygotic twin), one child with post-EBV ataxia, two children with acute disseminated encephalomyelitis (ADEM), and one with neuroblastoma and ataxia were also enrolled. Serum from three of the eight children with post-varicella ataxia, one with post-EBV ataxia, one child with ADEM and one sibling with uncomplicated varicella demonstrated reactivity with cerebrum (Figure 1) and cerebellum (Figure 2) tissues. The reactivity on monkey and human brain tissue was the same but because monkey brain tissues had superior cellular preservation, we show the results on monkey tissue. In two of the sera (two with post-varicella ataxia), this reactivity was seen on both acute and convalescent sera. The reactivity was predominantly a punctate pattern although axonal and other staining was also observed. The end point IIF titers on cerebellum were >1/160 but were not greater than 1/80 on cerebrum. Co-localization studies with antibodies directed against the centrosome protein pericentrin showed that some of the punctate staining of ataxia sera co-localized with this protein (Figure 2). In addition, staining of the cytoplasm of Purkinje cells was seen with both the ataxia sera and rabbit antibodies to pericentrin (Figure 2). This reactivity was seen to a lesser extent in cerebrum (Figure 1). Serum from one patient with ADEM demonstrated reactivity similar to the sera from children with post-varicella ataxia. There was no reactivity with cerebellar tissue in serum from one of two children with ADEM, in the serum of one child with neuroblastoma-associated ataxia, in serum from four of five

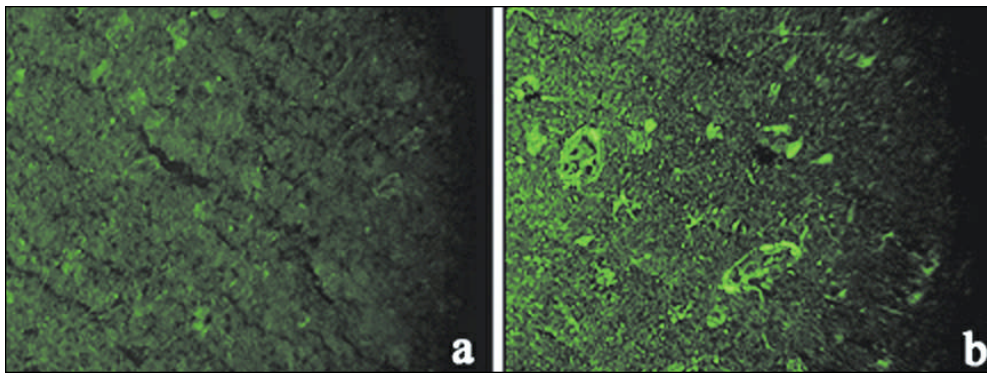


Figure 1: Indirect immunofluorescence using monkey cryopreserved cerebrum as substrate. (a) Serum from a child with varicella infection but no ataxia shows low intensity staining of the tissue. This is considered a negative reaction, also typical of other controls used including normals. (b) Serum from a child with ataxia after varicella infection shows strong punctate staining and staining of other unidentified tissue elements including the cytoplasm of some cells. All sera diluted 1/20. Original magnification x100.

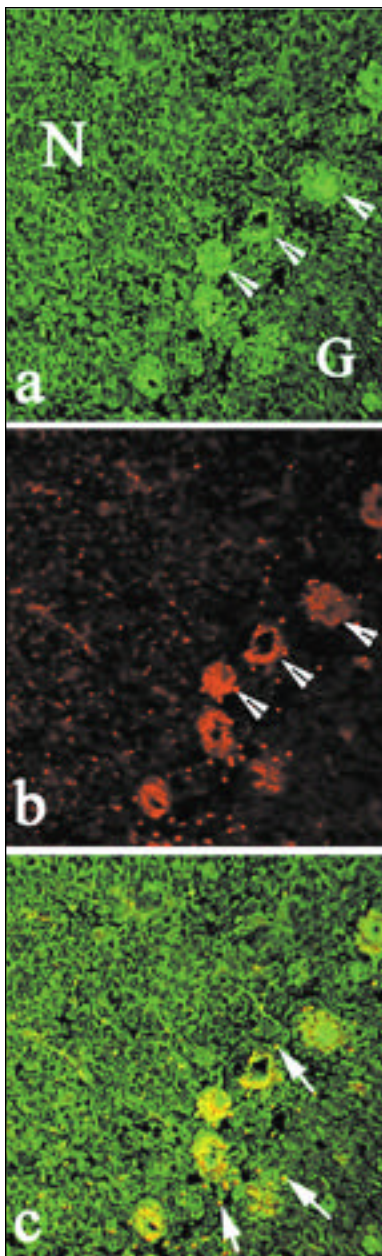


Figure 2: Representative results of the indirect immunofluorescence pattern of staining using monkey cryopreserved cerebellum as substrate. (a) Serum from a child with ataxia after varicella infection shows strong punctate staining of cells in the nuclear (N) layer, the granular (G) layers and Purkinje cells (arrowheads). Anti-Yo antibodies were used to identify Purkinje cells. (b) Rabbit antibodies to the centrosome protein pericentrin produce punctate staining of centrosomes and also the cytoplasm of Purkinje cells (arrowheads). (c) Merged images (a) and (b) demonstrate that some of the punctate staining exhibited by the human serum co-localizes with the rabbit antibodies to pericentrin (arrows). Original magnification x100.

children with uncomplicated varicella, and in the serum of none of the age and gender matched controls. All sera that demonstrated intense staining of cerebellar tissue also had antibodies to MAG I as tested by ELISA. However, the absorption studies did not confirm that any of the staining observed by IIF was due to anti-MAG activity. Cerebro-spinal fluid (CSF) was not tested for anti-MAG activity. None of the sera had antibodies to asialo-GM1, β 2 glycoprotein I, MBP or cardiolipin. Anti-Yo, anti-Hu, anti-Golgi or anti-endosome antibodies were not found in any of the children with ataxia, the paired sibling sera or normal controls. Undiluted CSF from two subjects did not demonstrate specific Purkinje cell reactivity.

Clinical results

Of the eight children with post-varicella ataxia, one was mildly affected, five were moderately affected and two were severely affected. Both of the latter two had drowsiness and vomiting requiring intravenous fluids. One child who was unresponsive to the antiemetics metoclopramide and ondansetron did improve significantly with dexamethasone (0.5mg/kg/d). Investigation in the two severely affected children included cranial computerised tomography (CT) and lumbar puncture (LP). PCR analysis of the CSF for *Varicella zoster* was negative in one child. The other children did not have cranial CT or LP. Of the eight children with post-varicella ataxia, seven were followed until recovery. Complete recovery was observed at a mean of 19 days (7-30 days) range. The other child also had complete recovery but timing was not documented.

DISCUSSION

Clinical features

There are 3 million cases of chicken pox each year in the United States and 90% of chicken pox occurs in children 1-14 years of age.¹⁴ Encephalitis accounts for 20% of hospital admissions due to varicella.¹⁵ A cerebellar syndrome, manifest primarily as ataxia, is associated with post-infectious and post-vaccinal states. This syndrome is common following varicella but also appears in measles, rubella and EBV viral infections. The clinical features usually begin abruptly five to six days following resolution of the rash in measles, rubella and EBV or within a week of the chicken pox eruption. The course is usually mild, but when severe, vomiting, dehydration and drowsiness are typical features. Impairment of consciousness is rare, and pyramidal signs and seizures are usually absent. The disease is monophasic and most of the children recover completely. CNS complications of chicken pox may be delayed for up to 21 days.¹⁶ Vaccination for varicella is now available.

Outcome in our patients with post-varicella ataxia was very good. All had complete resolution of ataxia and the mean time to normal gait was 19 days. A previous study reviewed the course and outcome of 73 children with acute cerebellar ataxia and reported that 26% were due to varicella. All children with post varicella ataxia recovered completely.¹⁶

Auto-immune status of patients with para-infectious ataxia

There is only one report of virus isolation in varicella-associated cerebellar ataxia.¹⁷ In this report, two children with post-varicella acute cerebellar ataxia had viral antigens detected by immunofluorescence in the CSF. The finding of oligoclonal bands in the CSF and development of cerebellar ataxia in patients with varicella infections suggests that autoantibodies may be responsible for at least part of the clinical picture.² A number of autoantibodies have been reported in post-infectious cerebellar syndromes. Ito et al¹ reported anti-neuronal antibodies in acute cerebellar ataxia following EBV infection.¹ Serum IgG and IgM antibodies reacted with both nuclear and cytoplasmic elements of Purkinje cells. The IgM reactivity gradually reduced. There was no identifiable neoplasm and the ataxia gradually improved. The anti-neuronal antibodies in the patient probably appeared after the EBV infection and suggests a role for autoimmune mechanisms in the pathogenesis of acute cerebellar ataxia. Sera from nine children with opsoclonus-myoclonus syndrome (three associated with neuroblastoma and six with a prodromal illness) had IgM and IgG binding to the cytoplasm of cerebellar Purkinje cells and to some axons in white matter. Western blot analysis showed a distinctive pattern of binding to several neural proteins, including a 210 kDa antigen identified as the high molecular weight subunit of neurofilament.² Also two children with CNS manifestations (including ataxia) following *Mycoplasma pneumoniae* infection were reported to develop anti-centriole antibodies.³ Of interest in the present report, sera from children with post-varicella ataxia showed strong punctate staining of cerebrum and cerebellum that co-localized with pericentrin, a component of centrosomes.

Auto-immune status of patients with paraneoplastic ataxia

Several different anti-neuronal antibodies have been identified in patients with paraneoplastic syndromes including paraneoplastic cerebellar degeneration (PCD).¹⁸⁻²⁰ IgM and IgA autoantibodies directed against Purkinje cells were observed in some PCD patients.^{4,18-20} In other studies, two auto-antigen systems referred to as Hu and Yo have become important markers in the identification of patients with malignancy who present with symptoms of cerebellar disease.^{12,21} Equally important, it is believed that in the paraneoplastic syndromes the autoantibodies participate in the pathogenesis of the disease. This conclusion is based on observations that the cerebellar signs are not due to invasion of the cerebellum by tumor and that passive transfer of anti-Yo antibodies to rodents results in the binding to the cognate antigen in Purkinje cells (but no neurological findings or Purkinje cell loss).^{21,22} Another report has shown that selective removal of the autoantibodies from the circulation of a PCD patient provided improvement of cerebellar signs.²³

In post-infectious encephalomyelitis or ADEM it is postulated that host myelin components, especially MBP became immunogenic, either by molecular mimicry with viral proteins or by release of sequestered neuronal antigens during a viral invasion, stimulating T cell reactivity.^{24,25,26} T cells cloned from the CSF of a patient with post-viral encephalomyelitis had a high frequency of MBP reactive T cells in the CSF that were not found in other inflammatory CNS disease.²⁷ In the present study, anti-MBP antibodies were not observed in any children but we did not assess T cell immune response to MBP.

Our observation that two children had fairly rapid response to corticosteroid treatment suggests that inflammatory responses play a role in the pathogenesis in at least some symptoms associated with post-viral ataxia. The other alternative is that cerebral or cerebellar oedema is improved by the dexamethasone. Although we did not find autoantibodies in the CSF of two children studied, it is possible that the brain-reactive autoantibodies observed in the serum were able to cross the blood brain barrier where they were absorbed by the target tissue. This hypothesis is supported by the observation that these sera had antibodies that produced intense staining of human and monkey brain tissues. Also, antibodies to both neuronal and cytoplasmic elements of Purkinje cells have been previously reported in post-infectious ataxia and opsoclonus-myoclonus.^{1,2,3} This provides circumstantial evidence that there is ample antigen to adsorb antibodies that may be produced peripherally or intrathecally.

In conclusion, increased fluorescence of cerebellar tissue was observed when exposed to serum from three of eight patients with post-varicella ataxia and in one patient with post-EBV ataxia, in one with ADEM and in one with uncomplicated varicella. Of interest, this IIF staining co-localized to centrosomes. We do not have conclusive proof that these antibodies account for the ataxia and symptoms observed in these children.

ACKNOWLEDGEMENTS

The authors thank Mrs. Joan Miller for technical support and the Alberta Children's Hospital Research Foundation for financial support of this research.

REFERENCES

1. Ito H, Sayama S, Kanazawa N, et al. Antineuronal antibodies in acute cerebellar ataxia following Epstein-Barr virus infection. *Neurol* 1994; 44:1506-1507.
2. Connolly AM, Pestronk A, Metha S, Pranzatelli MR, Noetzel MJ. Serum autoantibodies in childhood opsoclonus-myoclonus syndrome: an analysis of antigenic targets in neural tissues. *J Pediatr* 1997; 130:878-884.
3. Cimolai N, Mah D, Roland E. Anticentriolar autoantibodies in children with central nervous system manifestations of *Mycoplasma pneumoniae* infection. *J Neurol Neurosurg Psychiatry* 1994; 57:638-639.
4. Vincent A, Honnorat J, Antoine JC, et al. Autoimmunity in paraneoplastic neurological disorders. *J Neuroimmunol* 1998; 84:105-109.
5. Hida C, Tsukamoto T, Wano H, Yamamoto T. Ultrastructural localization of anti-Purkinje cell antibody - binding sites in paraneoplastic cerebellar degeneration. *Arch Neurol* 1994; 51:555-558.
6. Chan EKL, Fritzier MJ. Autoantibodies to Golgi apparatus antigens. In: Conrad K, Humbel R-L, Meurer M, Shoenfeld Y, Tan EM, eds. *Pathogenic and Diagnostic Relevance of Autoantibodies. Proceedings 4th Dresden Symposium on Autoantibodies.* Scottsdale: Pabst Scientific Publishers, 1998; 85-110.
7. Selak S, Chan EKL, Schoenroth L, Senecal J-L, Fritzier, MJ. Early endosome antigen-1 (EEA1): A predominant endosomal antigen in patients with neurological diseases. *J Invest Med* 1999; 47:311-318.
8. Arnett FC, Reveille JD, Goldstein R, et al. Autoantibodies to fibrillarin in systemic sclerosis (scleroderma): an immunogenetic, serological and clinical analysis. *Arthritis Rheum* 1996; 39:1151-1160.
9. Fritzier MJ. Autoantibody testing: Procedures and significance in systemic rheumatic diseases. In: Jasmin G, Simard R, eds. *Methods and Achievements in Experimental Pathology.* New York: S. Karger, 1986; 225-260.
10. Kreis TE, Pepperkok R. Coat proteins in intracellular membrane transport. *Curr Opin Cell Biol* 1994; 6:533-537.
11. Hawkes R. Antigenic markers of cerebellar modules in mice. *Biochem Soc Trans* 1992; 20:391-395.
12. Sakai K, Ogasawara T, Hirose G, Jaeckle KA, Greenlee JE. Analysis of autoantibody binding to 52-kd paraneoplastic cerebellar degeneration - associated antigen expressed in recombinant proteins. *Ann Neurol* 1993; 33:373-380.
13. Sriram S, Steinman L. Postinfectious and postvaccinal encephalomyelitis. *Neurol Clin* 1984; 2:341-353.
14. Straus SE, Ostrove JM, Inchauspé G, et al. Varicella-zoster virus infections: biology, natural history, treatment and prevention. *Ann Intern Med* 1988; 108:221-237.
15. Fleischer G, Henry W, McSorley M, Arbeter A, Plotkin S. Life-threatening complications of varicella. *Am J Dis Child* 1981; 135:896-899.
16. Connolly AM, Dodson WE, Prenskey AL, Rust RS. Course and outcome of acute cerebellar ataxia. *Ann Neurol* 1994; 35:673-679.
17. Peters ACB, Versteeg J, Lindeman J, Bots GTAM. Varicella and acute cerebellar ataxia. *Arch Neurol* 1978; 35:769-771.
18. Anderson NE, Rosenblum MK, Graus F, Wiley RG, Posner JB. Autoantibodies in paraneoplastic syndromes associated with small-cell lung cancer. *Neurology* 1988; 38:1391-1398.
19. Anderson NE, Rosenblum MK, Posner JB. Paraneoplastic cerebellar degeneration: clinical-immunological correlations. *Ann Neurol* 1988; 24:559-567.
20. Peterson K, Rosenblum MK, Kotanides H, Posner JB. Paraneoplastic cerebellar degeneration. I. A clinical analysis of 55 anti-Yo antibody positive patients. *Neurology* 1992; 42:1931-1937.
21. Posner J. Paraneoplastic cerebellar degeneration. *Can J Neurol Sci* 1993; 20:S117-S122.
22. Tanaka K, Tanaka M, Onodera O, et al. Passive transfer and active immunization with the recombinant leucine-zipper (Yo) protein as an attempt to establish an animal model of paraneoplastic cerebellar degeneration. *J Neurol Sci* 1994; 127:153-158.
23. Nitschke M, Hochberg F, Dropcho E. Improvement of paraneoplastic opsoclonus-myoclonus after protein A column therapy. *N Engl J Med* 1995; 332:192(letter).
24. Fritzier MJ, Salazar M. The diversity and origin of rheumatologic autoantibodies. *Clin Microbiol Rev* 1991; 4:256-269.
25. Barnett LA, Fujinami RS. Molecular mimicry: a mechanism for autoimmune injury. *FASEB J* 1992; 6:840-844.
26. Johnson RT, Hirsch RL, Griffin DE, Wolinsky JS. Clinical and immunological studies of measles encephalomyelitis. *Trans Am Neurol Assoc* 1981; 106:42-45.
27. Hafler DA, Benjamin DS, Burks J, Weiner HL. Myelin basic protein and proteolipin protein reactivity of brain and cerebrospinal fluid-derived T cell clones in multiple sclerosis and post-infectious encephalomyelitis. *J Immunol* 1987; 139:68-72.