

Research Note

Human *Gongylonema* infection in Iran

G.H. Molavi¹, J. Massoud¹ and Y. Gutierrez^{2*}

¹Department of Medical Parasitology and Mycology, School of Public Health and Health Research Institute, Tehran University of Medical Sciences, Tehran, Iran: ²Department of Clinical Pathology, Cleveland Clinic, Cleveland, Ohio, USA

Abstract

The first human infection with *Gongylonema* in Iran is reported in a 35-year-old Iranian woman with complaints of one year duration and treated as a psychotic patient. Two worms, a male, and a female, were retrieved, described, and identified as *G. pulchrum* based on their morphological characteristics.

Gongylonema is a genus of nematodes belonging to the Superfamily Spiruroidea with about 25 species in many wild and domestic mammals and ten species of birds, worldwide (Jelinek & Loscher, 1994). One species, *G. pulchrum*, known as the 'gullet worm' because of its location in the upper digestive system, has been reported in humans as sporadic cases in many places around the world, including ten times in the United States (Eberhard & Busillo, 1999; Wilson *et al.*, 2001). The majority of known cases are from the former Soviet Union, Europe and the Middle East.

Recently, the first human infection with *Gongylonema* in Iran was found. The symptoms the patient manifested were interpreted as delusional and were treated as psychotic in nature. Eberhard & Busillo (1999) stressed that one of the important clinical features of *Gongylonema* infections in humans is the fact that these patients may be mistakenly considered as suffering from delusional parasitosis.

A 35-year-old, healthy woman was referred to the School of Public Health and the Institute of Health Research, Tehran, University of Medical Sciences, Iran, with a one year history of feeling a migratory creeping sensation in the neck region and upper part of the digestive tract. No other symptoms were observed and the patient was treated for psychotic symptoms by a local physician. Preliminary examination of the neck, mouth and larynx showed no abnormalities, except for the sensation of a moving object in the throat. Under the

suspicion of a helminth infection the patient was prescribed empirically a single dose of 400 mg of albendazole and after 9 h a reexamination of the patient showed two delicate, white, thread-like worms moving actively within the squamous epithelium of the right side of the lingual frenulum. Two living worms were retrieved with difficulty because of their activity. No other treatment was recommended and the patient was free of all complaints three months later.

The extracted worms were whitish, slender, cylindrical with tapered ends, consistent with nematodes and highly motile. The two adult worms, a male and a female, were placed, still alive, in normal saline solution for a few hours at 4°C in the refrigerator to allow relaxation, transferred to a solution of lactophenol (phenolic acid 20 ml; lactic acid 20 ml; glycerin 20 ml and distilled water 20 ml) for 4 h, and examined microscopically and measured.

In the cephalic portion, the cuticle shows the characteristic cuticular plates, arranged irregularly in three longitudinal bilateral rows extending about 2 mm posteriorly (fig. 1A, B and C). Lateral alae are prominent and extend from a short distance beyond the cervical papillae to the posterior end of each worm (fig. 1A and C). These structures are characteristic of the genus *Gongylonema* (Baylis, 1925a; Beaver *et al.*, 1984). The mouth is small, surrounded by a cuticular rim and small papillae next to the labia (fig. 1B and C); the short, narrow cylindrical pharynx is 30 µm long and made of cuticular walls (fig. 1B and C). No *en face* studies were made to observe the arrangement of the minute oral papillae surrounding the labia. The pharynx continues into a short muscular oesophagus (fig. 1B and C) and then a larger

*Fax: 0098 216 646 2227
E-mail: molavig@yahoo.com

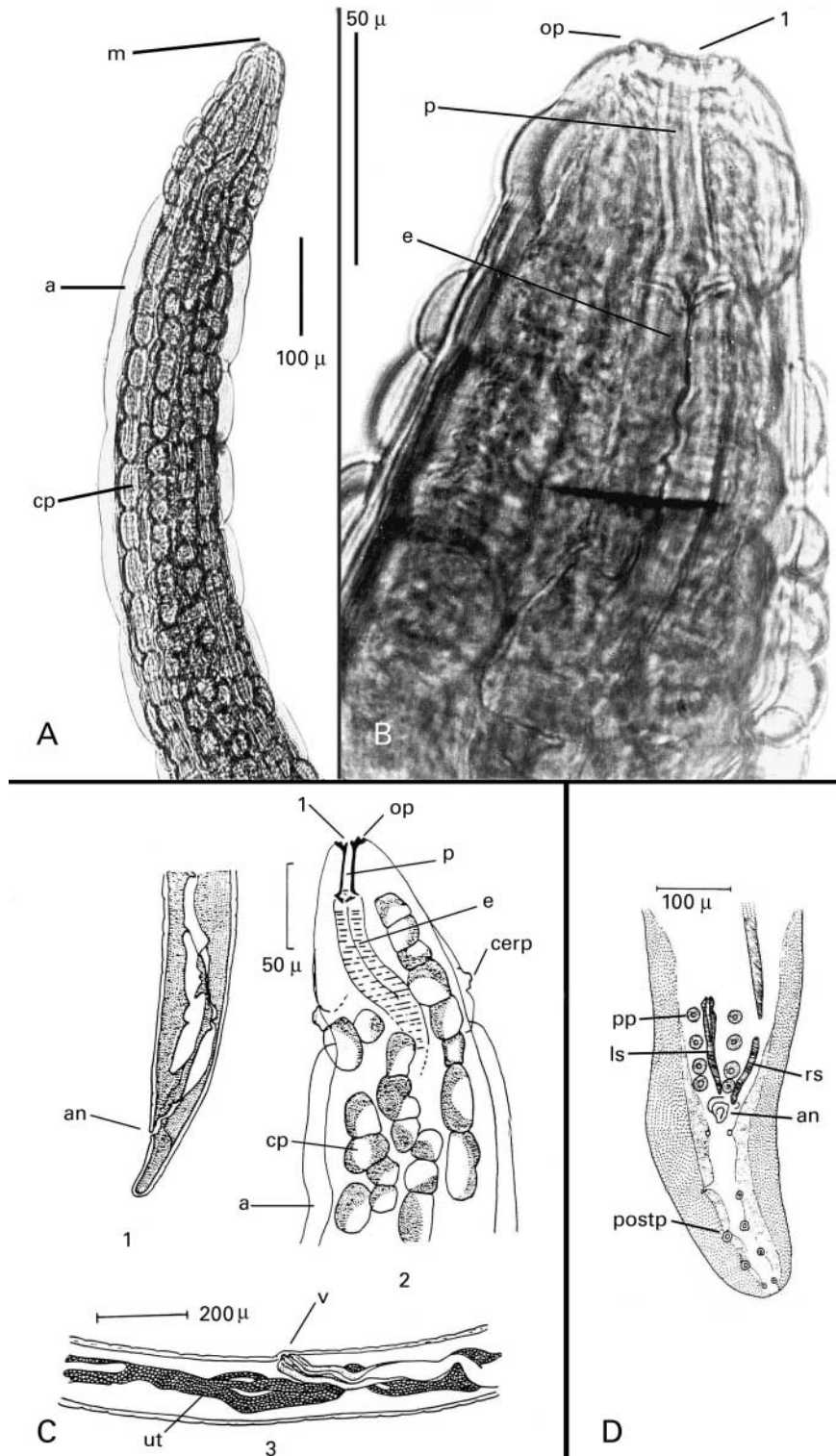


Fig. 1. *Gongylonema pulchrum*. A. Cephalic end (similar in both male and female). B. Cephalic end illustrating the lips, oral papillae, pharynx and proximal portion of muscular oesophagus. C. Posterior end of the female (1); cephalic end of both male and female (2); and the vagina and uteri of the female (3). D. Posterior end of male. Abbreviations: a. lateral alae; an. anus; cerp. cervical papillae; cp. cuticular plates; e. oesophagus; l. lips; ls. left spicule; m. mouth; op. oral papillae; p. pharynx; pp. pre-anal papillae; postp. post-anal papillae; r. right spicule. u. uteri with eggs; v. vagina.

glandular portion. Two cervical papillae, one on each of the lateral aspects of the worm are located about 100 μm from the anterior end (fig. 1C).

The male is 17 mm in length by 0.13 mm wide; the left spicule is 540 μm long and the right spicule 100 μm ; a gubernaculum is present (fig. 1D). The posterior end of the male is broadly twisted and has wide lateral alae with four pairs of pedunculated perianal papillae about 20 μm in diameter and five pairs of smaller post-anal papillae (fig. 1D). The female is 30 mm by 0.13 mm and the eggs in the uterus are 45 by 30 μm with well developed larvae (fig. 1C). The posterior end of the worm is straight and tapers to a blunt tip; the vulva is located towards the posterior half of the body (fig. 1C).

The life cycle of *G. pulchrum* requires insects, usually dung beetles or cockroaches, as intermediate hosts. Mammalian or avian hosts acquire the infection after feeding on insects or by accidental ingestion during foraging. Larvae enter the stomach mucosa and then migrate to the oesophageal epithelium and upper digestive tract. Adult worms live in tunnels bored into the squamous epithelia of the oesophagus, mouth, hard palate and tonsils, where they migrate and lay eggs. When the epithelium eventually desquamates, eggs pass out with the faeces into the environment. Intermediate hosts become infected when they ingest infective eggs with faeces of the definitive hosts. Larvae migrate to the insect's body cavity, connective tissues and muscles, where they become encapsulated. Human infections result from accidental or intentional ingestion of food contaminated with whole, or parts of infected insects, more than likely roaches (Beaver *et al.*, 1984; Gutierrez, 2000). Water containing larvae released from dead, disintegrating insects may be another source of infection (Dismuke & Routh, 1963). Histological lesions produced by larvae and migrating worms both in humans and animals are unknown, except for those of *G. neoplasticum*, which produces stomach tumours in the rat. Regarding the patient in the present case, there is no indication that she intentionally ingested any potential intermediate hosts, nor is there a history of behaviour that may have constituted a risk of contact with arthropods. In Iran, the prevalence of *G. pulchrum* in cattle has been reported as 45% (Eslami & Farokhzadegan, 1972) and in sheep as 21% (Eslami & Nabavi, 1976).

The clinical presentation in the majority of patients with *Gongylonema* infections is the sensation of something migrating within the epithelia of the oral cavity (lips, cheeks, hard palate, tonsils) sometimes for months. Direct observation of the affected area often reveals a small blister or nodule, sometimes containing the worms. This clinical picture was also the presentation of the patient reported here, but there was no visual indication of parasites and this led the physician to treat her symptoms as psychotic in origin. Eggs of *Gongylonema* are found in the stools of the definitive host, but they are usually not reported in humans because they are not looked for and the majority of human infections consist of a single worm, which does not produce eggs. Those rare instances of a single male–female infection produce such a low number of eggs that detection in the clinical laboratory is difficult. *Gongylonema* eggs have been found in stool examinations on two previous occasions. In Japan, a patient was found to have 42% peripheral eosinophilia though no symptoms

consistent with *Gongylonema* infection were elicited, and neither were adult worms found (Wilde *et al.*, 2001). The other instance occurred in Gambia where 13 of 1548 individuals showed *Gongylonema* eggs in their stools (Garin *et al.*, 1978). These individuals were considered as having spurious parasitism due to the consumption of viscera from infected animals

The fact that mature male and female worms were retrieved in the present study is also of interest, because the majority of *Gongylonema* infections in humans yield single females, a few yield males, and in even fewer instances two or more worms occur. This therefore provided an opportunity to study the morphological characteristics of the parasite and address the question of its classification. *Gongylonema pulchrum* is a nematode with a low host-specificity capable of infecting numerous species of animals where they grow to different sizes (Baylis, 1925b; Lichtenfels, 1971). A review (for this study) of 25 available reports of *Gongylonema* infections in humans where the worms were studied shows that of 32 worms recovered, 8 were males, 23 were females, and in one case the sex was not reported. The eight males ranged in size from 19 to 67 mm in length and 0.10 to 0.27 mm in width. The 23 females ranged from 24 to 136 mm in length and 0.17 to 0.50 mm in width. In most of these reports the species was determined to be *G. pulchrum*, even though only single females were recovered and that the size of the worms was always smaller than those reported for the species in their natural hosts: 62 mm by 0.3 mm for the male and 145 mm by 0.5 mm for the female (Baylis, 1925a; Beaver *et al.*, 1984). The size variability of *G. pulchrum* in hosts other than their natural ones has prompted the suggestion that there are possibly distinct races adapted to different hosts in nature (Baylis, 1925a). Specimens of *G. pulchrum* recovered from natural and experimental infections of eight species of hosts, whose worms are in the National Parasite Collection in Beltsville, Maryland, USA (Lichtenfels, 1971), showed that worms varied from 10 to 51 mm for the males and 13 to 130 mm for the females. In recent experimental infections of rabbits with *G. pulchrum*, the growth of worms to adult size took about 10 weeks for males and 20 weeks for females (Kudo *et al.*, 2005). This may contribute to the variability in the size of worms recovered from humans, as both larval stages and immature adults produce symptoms that result in seeking medical help. These sizes, plus those reported for worms obtained from humans are consistent with the size of the present specimens and thus they are identified as *G. pulchrum*.

References

- Baylis, H.A. (1925a) On the species of *Gongylonema* (Nematoda) parasitic in ruminants. *Journal of Comparative Pathology and Therapy* **38**, 46–55.
- Baylis, H.A. (1925b) On *Gongylonema* collected in Italy during October 1924, with some observations on the genus. *Journal of Tropical Medicine and Hygiene* **28**, 71–76.
- Beaver, P.C., Jung, R.C. & Cupp, E.W. (1984) *Clinical parasitology*. 9th edn. 825 pp. Philadelphia, Lea & Febiger.

- Dismuke, J.C. & Routh, C.F.** (1963) Human infection with *Gongylonema* in Georgia. *American Journal of Tropical Medicine and Hygiene* **12**, 73–74.
- Eberhard, M.L. & Busillo, C.** (1999) Human *Gongylonema* infection in a resident of New York City. *American Journal of Tropical Medicine and Hygiene* **61**, 51–52.
- Eslami, A. & Farokhzadegan, F.** (1972) Les nematodes du tube digestif des bovines en Iran. *Revue d'Élevage et de Médecine Vétérinaire des Pays Tropicaux* **25**, 527–529.
- Eslami, A. & Nabavi, M.** (1976) Species of gastrointestinal nematodes of sheep from Iran. *Bulletin de la Société de Pathologie Exotique* **69**, 92–95.
- Garin, Y., Languillat, G., Beauvais, B., Tursz, A. & Lariviere, M.** (1978) Le parasitisme intestinal au Gabon oriental. *Bulletin de la Société de Pathologie Exotique* **71**, 157–164.
- Gutierrez, Y.** (2000) *The diagnostic pathology of parasitic infections with clinical correlations*. 2nd edn. 769 pp. New York, Oxford University Press.
- Jelinek, T. & Loscher, T.** (1994) Human infection with *Gongylonema pulchrum*: a case report. *Tropical Medicine and Parasitology* **45**, 329–330.
- Kudo, N., Kuratomi, K., Hatada, N., Ikadai, H. & Oyamada, T.** (2005) Further observations on the development of *Gongylonema pulchrum* in rabbits. *Journal of Parasitology* **95**, 750–755.
- Lichtenfels, J.R.** (1971) Morphologic variation in the gullet nematode, *Gongylonema pulchrum* Molin. 1857, from eight species of definitive hosts with a consideration of *Gongylonema* from *Macaca* spp. *Journal of Parasitology* **57**, 348–355.
- Wilde, H., Suankratay, C., Thongkam, C. & Chaiyabutr, N.** (2001) Human *Gongylonema* in Southeast Asia. *Journal of Travel Medicine* **8**, 204–206.
- Wilson, M.E., Lorente, C.A., Allen, J.E. & Eberhard, M.L.** (2001) *Gongylonema* infection in the mouth in a resident of Cambridge, Massachusetts. *Clinical Infectious Diseases* **32**, 1378–1380.

(Accepted 6 March 2006)
2006 Cambridge University Press