

Bilateral breast reconstruction

J. J. Disa, C. M. McCarthy

*Department of Surgery, Cornell University, Plastic and Reconstructive Surgery Service,
Memorial Sloan-Kettering Cancer Center, Weill Cornell Medical College, New York, NY, USA*

Abstract According to the American Cancer Society, more than 211 000 women in the USA were diagnosed with invasive breast cancer in 2005, (American Cancer Society. www.cancer.org. 2005). Nearly 65 000 of these women had postmastectomy reconstruction – a 100% increase from just over a decade ago, (American Society of Plastic Surgeons. www.plasticsurgery.org. 2005). A significant proportion of these women, will elect to undergo bilateral mastectomy for treatment and/or prophylaxis of breast cancer. Contemporary techniques provide numerous options for bilateral, postmastectomy reconstruction. Procedure selection will be based on a range of patient variables, including: availability of local, regional, and distant donor tissues for bilateral reconstruction, size and shape of the desired breasts, surgical risk, and most importantly, patient preference. Ultimately, the individualized selection of a reconstructive technique for each patient is a predominant factor in achieving a reconstructive success.

Keywords: Autogenous tissue reconstruction; Bilateral; Breast; Implant reconstruction; Postmastectomy reconstruction; Symmetry

Introduction

Bilateral breast reconstruction may be indicated in women with bilateral breast cancer, women with unilateral cancer and a high risk of developing a contralateral cancer, or in women who choose bilateral prophylactic mastectomy. In this setting, women may consider bilateral breast reconstruction in an attempt to improve their outward appearance and ultimately improve their inner sense of sexual desirability and femininity.

The surgical objective of bilateral, postmastectomy reconstruction is to satisfy the patient with regards to her expectations for an overall result. Thus, the ideal reconstructive technique will fashion symmetrical breast mounds with natural contours and consistencies, and minimal scarring.

One advantage of bilateral breast reconstruction is that a patient's reconstructed breast need not match a contralateral, native breast, but rather a contralateral, reconstructed breast. The surgeon will strive to reconstructive bilateral breast mounds, symmetric with respect to volume and positioning on the chest wall. Previous reports have suggested that both breast symmetry and overall cosmesis may be superior in patients with bilateral reconstructions, due to the fact that the degree of breast ptosis is symmetrical [1,2]. When mastectomies are asynchronous or asymmetric, however, the reconstructions may not be as symmetric despite the fact that similar reconstructions are performed on each side.

Contemporary reconstructive techniques provide numerous options for bilateral, postmastectomy reconstruction. These options include: single-stage reconstruction with a standard or adjustable implants, tissue expansion followed by placement of permanent implants, combined autologous tissue/implant reconstruction, or autogenous tissue reconstruction alone. Although bilateral, autogenous tissue reconstruction is generally thought to produce the most natural looking and feeling breasts, the relative magnitude

Correspondence to: J. J. Disa, MD, Plastic and Reconstructive Surgery Service, Memorial Sloan-Kettering Cancer Center, 1275 York Avenue, Room C-1189, New York, NY 10021, USA.

Received: 14/12/05
Accepted: 20/04/06
First published online 19/12/06
BCO/379/2006/FO

of these procedures is great. Many women will instead opt for bilateral, prosthetic reconstruction, choosing a less invasive operative procedure with a faster recovery time. Individualized selection of a reconstructive technique for each patient is critical to success.

The following is an overview of current bilateral, breast reconstruction techniques. Indications, contraindications, advantages, and disadvantages of autogenous tissue and prosthetic breast reconstruction in the setting of bilateral breast reconstruction will be discussed.

Prosthetic reconstruction

Bilateral implant reconstruction has the distinct advantage of combining a lesser operative procedure with the capability of achieving excellent results (Fig. 1). It may be that outcomes following bilateral implant reconstruction are so favorable because the implant reconstruction needs only to match the contralateral implant rather than a natural, ptotic breast. The use of tissue expansion provides donor tissue with similar qualities of skin texture, color, and sensation compared to the native breasts. Donor-site morbidity is eliminated with use of a bilateral implants; and, by using the patient's mastectomy incisions to place the prostheses, no new scars are introduced.

Prosthetic reconstruction techniques include: single-stage reconstructions with either standard or adjustable, permanent prostheses, two-stage tissue expander/implant reconstructions; and, combined implant/autogenous tissue reconstructions. Immediate, single-stage breast reconstruction with a standard implant is best suited to the occasional patient with adequate skin at the mastectomy sites and small, non-ptotic breasts. Selection criteria for single-stage, adjustable implant reconstruction is similar; yet, it is the preferred technique when the ability to adjust the volume of the device postoperatively is desired. In

small-breasted women where the skin deficiency is minimal, the implants can be partially filled at the time of reconstruction and gradually inflated to the desired volume postoperatively. Disadvantages of this technique include the placement of remote ports and the need for their subsequent removal.

While satisfactory results can be obtained with single-stage reconstruction, in the vast majority of patients, a far more reliable approach involves two-stage expander/implant reconstruction. Tissue expansion is used when there is insufficient tissue after mastectomy to create the desired size and shape of each breast in a single stage. Tissue expanders are placed under the skin and muscles of the chest wall at the primary procedure (Figs. 2 and 3). Postoperatively, tissue expansion is performed over a period of

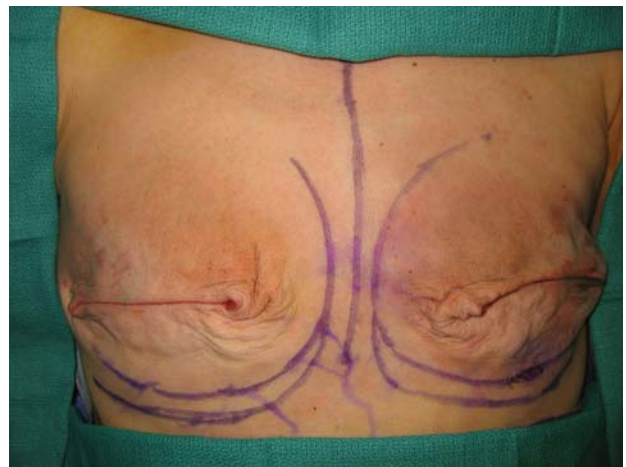


Figure 2.

Textured surface, integrated valve, bidimensional shaped tissue expander with Magnasite® (Inamed Aesthetics, Santa Barbara, California) fill port locating device.

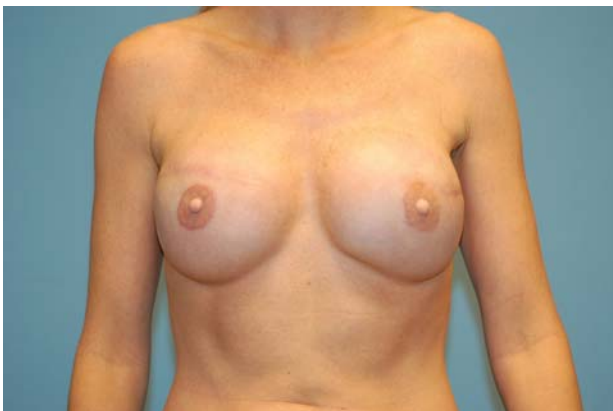

Figure 1.

Bilateral breast reconstruction with silicone gel implants after nipple areola reconstruction.

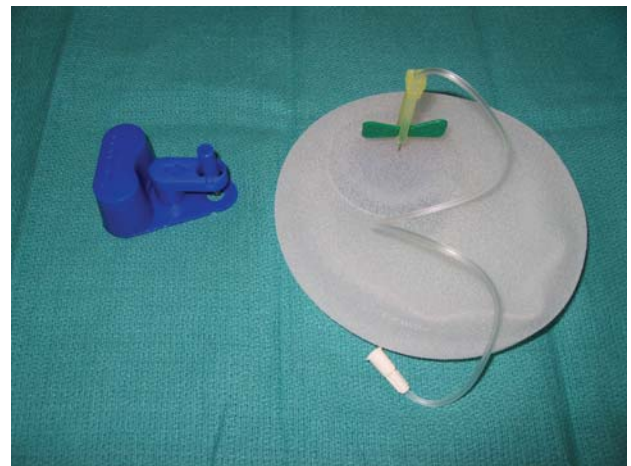


Figure 3.

Intraoperative appearance of bilateral mastectomy defect. Original position of inframammary folds and planned lower position of new inframammary fold are marked.

weeks or months, the soft tissues stretched until the desired breast volume is achieved. Anatomic expanders are used to preferentially expand the lower pole of the breast facilitating creation of breast ptosis. Exchange of the temporary expanders for permanent implants occurs at a subsequent operation. At this second procedure, access to the implant pockets enables adjustments to improve the final breast form. Capsulotomies are often performed at this second stage. By releasing the surrounding scar capsule, breast projection and breast ptosis can be increased. Similarly, precise positioning of the inframammary folds can be addressed.

Currently, both saline and silicone gel implants are available for use in breast reconstruction. While the stigma surrounding the use of silicone filled implants still exists, issues of silicone safety have been carefully investigated. To date, there is no definitive evidence linking breast implants to cancer, immunologic diseases, neurologic problems, or other systemic diseases. The use of silicone gel implants generally allows for a softer, more natural-appearing breast. Alternatively, the use of saline filled implants allows for minor volume adjustments to be made at the time of implant placement. And while saline filled implants may offer the greatest piece of mind for some patients in terms of safety, implant palpability, and rippling is more likely.

Combined autogenous tissue/implant reconstruction

Nearly every patient who undergoes a mastectomy is a candidate for some form of implant-based reconstruction. Implant reconstruction alone is contraindicated, however, in the presence of an inadequate skin envelope. A large skin excision at the time of mastectomy, due to previous biopsies or locally advanced disease, may preclude primary coverage of a prosthetic device.

Similarly, previous chest wall irradiation and/or postmastectomy radiotherapy are considered by many, a relative contraindication for implant-based breast reconstruction. Following bilateral mastectomies in patients who have had prior, unilateral chest wall irradiation, the ipsilateral latissimus dorsi myocutaneous flap can provide additional, non-radiated soft tissue, which because of its volume and pliability, facilitates the process of tissue expansion. The skin island is designed under the bra-line or along the lateral margin of the muscle and the flap is tunneled anteriorly into the mastectomy defect. Although the latissimus dorsi myocutaneous flap is extremely reliable, the tissue bulk is usually inadequate. Thus, a permanent implant is often placed beneath the flap to provide adequate volume. Most

commonly, implant-based reconstruction alone will be performed on contralateral, non-radiated breast will provide the best symmetry in most cases (Fig. 4).

The latissimus dorsi flap is advantageous in that it can provide additional vascularized skin and muscle to the breast mound in a single operative procedure. In cases in which large amounts of new skin are required at the mastectomy site, a temporary tissue expander can be placed to enlarge the latissimus dorsi skin island following inset of the flap. The combination of a latissimus dorsi flap and tissue expansion may be particularly appropriate in cases in which the remaining mastectomy skin is of insufficient quality or quantity to tolerate tissue expansion. This is typically the case in the inset of delayed reconstruction after mastectomy and postoperative radiation therapy. Its disadvantages include the creation of new chest scars, a back donor scar, and the fact that the transfer of autogenous tissue does not, in this setting, eliminate the need for an implant.

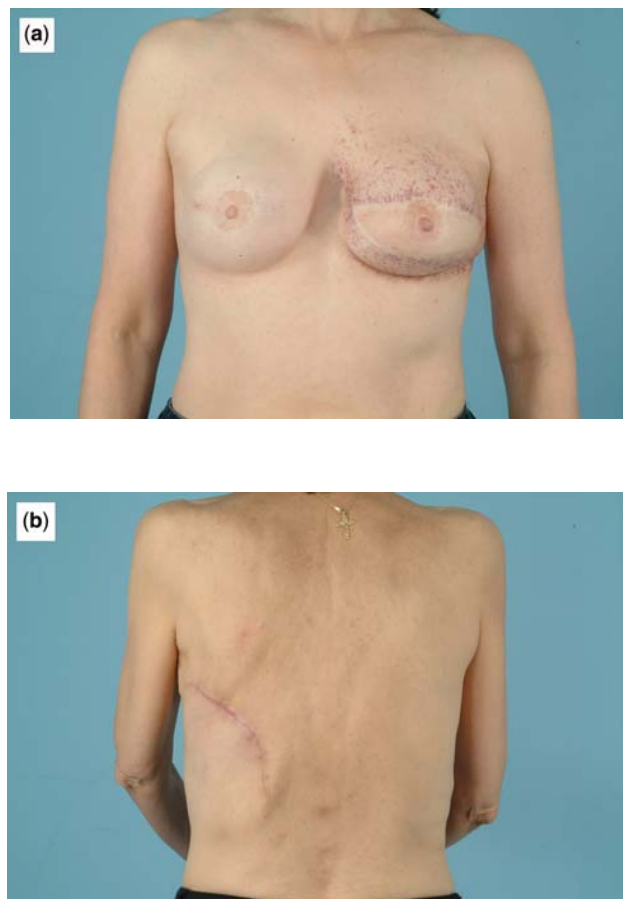


Figure 4. (a) Delayed, left, combined latissimus-dorsi/ expander-implant reconstruction. Note radiation induced skin changes native skin flaps. Right expander/implant reconstruction. (b) Posterior view Note donor-site scar left thorax.

Advantages/disadvantages

Prosthetic breast reconstruction is a relatively simple technique that is generally well tolerated. Complications are generally centered on the breast with minimal systemic health implications, and minimal overall patient morbidity. Thus, bilateral implant reconstruction can often be performed on patients who might not be suitable candidates for the more lengthy, complex surgical procedures required for bilateral, autogenous tissue reconstruction.

While bilateral, expander/implant reconstruction is technically easier than bilateral autologous reconstruction and has a shorter hospitalization with a quicker recovery, it does require multiple procedures [3,4]. Patients who undergo tissue expander/implant breast reconstruction will experience varying degrees of discomfort and chest wall asymmetry during the expansion phase. In addition, patients must make more frequent office visits for percutaneous expansion.

The breast mounds achieved with implant reconstruction will be generally more rounded and less ptotic. Late complications include device malfunction and capsular contracture [2]. While capsular contracture occurs to some extent around all implants; in some, the degree of contracture will increase in severity over time. A pathologic capsular contracture, implant deflation, and/or rupture may require revisional surgery years following completion of reconstruction.

Autogenous tissue reconstruction

Bilateral, breast reconstruction with autologous tissue can generally achieve more durable, natural-appearing results than reconstruction based on prosthetic implants alone (Fig. 5). The breast mound reconstructed with autologous tissue is closer in consistency to the native breast. Because surgical scars fade and tissue firmness subsides with time, the results of autologous breast reconstruction tend to improve as the patient ages rather than deteriorate as with prosthetic reconstruction. Complete restoration of the breast mound in a single stage is possible in most patients.

Numerous options exist for bilateral, autogenous tissue reconstruction. Reconstructive techniques using the lower abdominal donor site include: the pedicled transverse rectus abdominis myocutaneous (TRAM) flap, the free TRAM flap, the free muscle-sparing TRAM flap, the deep inferior epigastric perforator (DIEP) flap and the superficial inferior epigastric artery (SIEA) flap. Other autogenous tissue alternatives include: the latissimus dorsi flap, gluteal flaps, the Rubens fat pad flap, and perforator flaps from the gluteal and lateral thigh donor sites.

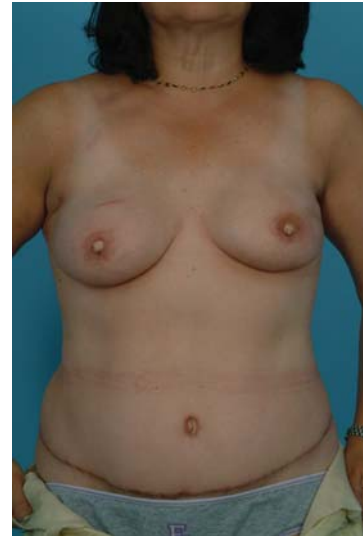

Figure 5. Bilateral, free transverse rectus abdominis myocutaneous (TRAM) flap reconstruction was performed immediately following bilateral skin-sparing mastectomies. Bilateral nipple areolae reconstruction has been completed.

The TRAM or related flap is the most frequently used method for autogenous breast reconstruction. One of the advantages of the TRAM flap procedure is the provision of adequate soft-tissue bulk to provide bilateral breast reconstruction from a single donor site (Fig. 6). Bilateral TRAM flaps are designed so that the skin islands are oriented transversely across the lower abdomen and the resulting 'abdominoplasty-like scar' is camouflaged. In addition, in contrast to bilateral latissimus or gluteal flap reconstruction, bilateral TRAM flap harvest does not require any repositioning during surgery.

One caveat of reconstruction with the TRAM or related flap, however, is that due to the anatomy of the flap, bilateral reconstruction is only an option if both sides are reconstructed at the same time. For example, after a TRAM or related flap has been harvested, its donor site may not be used again. Thus, women who have had a TRAM for unilateral reconstruction must seek other options if contralateral reconstruction becomes necessary.

The blood supply of the *pedicled* TRAM flap is derived from the superior epigastric artery via a series of choke vessels within the rectus abdominis muscle. The rectus muscles serve as vascular carriers for large ellipses of lower abdominal skin and fat. After each flap is harvested, subcutaneous tunnels joining the each abdominal donor site to ipsilateral mastectomy defects are created in order to accommodate each flap. The abdominal donor sites are then closed by reapproximating the remaining anterior rectus sheaths and by closing the remaining skin like a modified abdominoplasty. Although bilateral

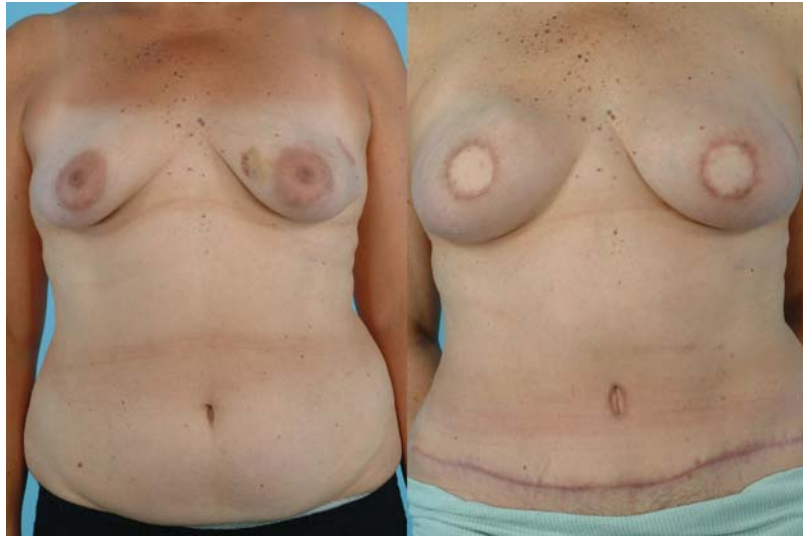

Figure 6.

(Left) Pre-operative photo. (Right) Bilateral, free DIEP flap reconstruction was performed immediately following bilateral skin-sparing mastectomies. Bilateral nipple areolae reconstruction has not been completed.

breast reconstruction with a pedicled TRAM is feasible, antagonists claim that the risk of morbidity from bilateral muscle harvest, including abdominal weakness and the propensity toward future back pain, is not acceptable in the current realm of reliable microsurgical capability.

Compared with bilateral, pedicled TRAM flaps, bilateral, microvascular free TRAM flaps allow for a more reliable transfer of large tissue portions with less disruption of the abdominal wall. Similarly, because the blood supply to a free TRAM is based upon the more dominant inferior epigastric vascular pedicle, the procedure can be used with a greater degree of safety in patients with risk factors such as tobacco use, diabetes, and obesity. Microvascular anastomoses are generally performed to the thoracodorsal or internal mammary vessels.

The muscle-sparing TRAM flap, which is limited to the portion of muscle that encompasses the lateral and medial rows of perforating vessels, is a modification of the TRAM flap which theoretically minimizes even further, violation of the abdominal wall and the risk of donor-site morbidity. The DIEP flap is a further refinement of the conventional muscle-sparing free TRAM flap. The overlying skin and subcutaneous tissues are perfused by transmuscular perforators originating from the deep inferior epigastric artery. When a perforating vessel is found, it is dissected away from the surrounding muscle and traced to its origin from the vascular pedicle. Because no muscle is harvested, donor-site morbidity is further minimized and thus, this flap choice is an excellent option for bilateral reconstruction (Fig. 5). Harvest of the DIEP flap can be a tedious dissection, however, which can prolong a potentially lengthy operation [5].

Further options in autologous tissue reconstruction

A patient desiring of a bilateral TRAM or related flap must have adequate tissues in the lower abdomen to be considered a candidate. Although the characteristic infraumbilical fat deposit in the female can provide substantial soft-tissue bulk, in bilateral TRAM flap reconstruction, the amount of available abdominal donor tissue for each breast will be reduced by up to one half. Thus, one of the primary reasons for use of an method of reconstruction includes inadequate abdominal fat in a patient with a slender body habitus. Additionally, a patient's lifestyle must allow for the potential diminution of truncal strength. Finally, high-risk abdominal scars may predispose to flap necrosis and/or wound healing problems at the abdominal donor site.

In a situation where a patient is an inappropriate TRAM flap candidate, yet still desires bilateral, autogenous reconstruction, alternate flap options include: bilateral Rubens flaps, bilateral gluteal myocutaneous flaps, or bilateral perforator flaps from the gluteal and lateral thigh donor sites. These free flaps are much less commonly employed and have distinct disadvantages when compared with flaps from the abdominal donor site.

Advantages/disadvantages

Bilateral, autogenous reconstruction is more complex than implant-based reconstruction and requires a much lengthier, more invasive surgical procedure. Postmastectomy reconstruction with a TRAM or related flap generally requires a 5–7 day hospitalization and a 4–6 week convalescence. Because of the

magnitude of the procedure, complications do occur. Fortunately, major complications are uncommon.

Data has accumulated over the past decade that shows that muscle- and fascia-sparing techniques, such as the use of DIEP flaps, result in measurably better postoperative truncal strength. Postoperative abdominal hernia, or more commonly, abdominal wall laxity remains a persistent issue for some patients choosing TRAM reconstruction. Interestingly, muscle-sparing techniques do not appear to decrease the risk of abdominal bulging or hernia formation.

Use of the free TRAM flap decreases the rate of complications compared to pedicled TRAM flaps. The incidence of both fat necrosis and partial flap loss is close to 5% in most series, as compared to 15–20% in pedicled flaps [6,7]. The rate of total flap loss is 1–2% in most series and is comparable to those published for the pedicled TRAM flaps. Smoking, chest wall irradiation, significant abdominal scarring, and obesity are associated with an increased complication rate [8]. Common secondary adjustments include liposuction of the flap for improved contour, abdominal scar revision and hernia repair, and fat necrosis excision.

Conclusion

Bilateral, autologous tissue reconstruction is advocated by some because of superior esthetic results. The permanency of the esthetic results and the lack of dependency on permanent prostheses are distinct advantages. Bilateral, prosthetic reconstruction, however, has the capability of producing excellent results in the properly selected patient. Bilateral, implant reconstruction is a much less invasive technique, is generally well tolerated and eliminates potential donor-site morbidity.

The overriding goal of bilateral breast reconstruction is to satisfy the patient with respect to her own self-image and expectations for the esthetic result. Individualized selection of a reconstructive technique for each patient is a predominant factor in achieving a reconstructive success.

References

1. Clough. Prospective evaluation of late cosmetic results following breast reconstruction: II. TRAM flap reconstruction. *Plast Reconstr Surg* 2001; **107**: 1710–1762.
2. Krueger EA, Wilkins EG, Strawderman M, Cederna P, Goldfarb S, Vicini FA, *et al.* Complications and patient satisfaction following expander/implant breast reconstruction with and without radiotherapy. *Int J Radiat Oncol Biol Phys* 2001; **49**: 713–721.
3. Spear SL, Mardini S, Ganz JC. Resource cost comparison of implant-based breast reconstruction versus TRAM flap breast reconstruction. *Plast Reconstr Surg* 2003; **112**: 101–105.
4. Kroll SS, Evans GR, Reece GP, Miller MJ, Robb GL, Baldwin BJ, *et al.* Comparison of resource costs of free and conventional TRAM flap breast reconstruction. *Plast Reconstr Surg* 1996; **98**: 74–77.
5. Blondeel N, Vanderstraeten GG, Monstrey SJ, Van Landuyt K, Tonnard P, Lysens R, *et al.* The donor site morbidity of free DIEP flaps and free TRAM flaps for breast reconstruction. *Br J Plast Surg* 1997; **50**: 322–330.
6. Watterson PA, Bostwick III J, Hester Jr TR, Bried JT, Taylor GI. TRAM flap anatomy correlated with a 10-year clinical experience with 556 patients. *Plast Reconstr Surg* 1995; **95**: 1185–1194.
7. Kroll SS, Netscher DT. Complications of TRAM flap breast reconstruction in obese patients. *Plast Reconstr Surg* 1989; **84**: 886–892.
8. Nahabedian MY, Dooley W, Singh N, Manson PN. Contour abnormalities of the abdomen after breast reconstruction with abdominal flaps: the role of muscle preservation. *Plast Reconstr Surg* 2002; **109**: 91–101.