

Carotid Dissection: Technical Factors Affecting Endovascular Therapy

Felipe C. Albuquerque, Patrick P. Han, Robert F. Spetzler, Joseph M. Zabramski, Cameron G. McDougall

ABSTRACT: Background and Purpose: To delineate factors associated with the successful endovascular treatment of extracranial carotid dissections, the authors review their management of 13 cases. **Methods:** The records of 12 patients with 13 dissections were assessed with reference to mechanism of dissection, preoperative symptoms, presence of a pseudoaneurysm, treatment success, and etiology of treatment failure. Patients were followed prospectively and included six men and six women, ranging in age from 27 to 62 years. **Results:** Angioplasty and stenting were performed successfully in 11 of 13 procedures (10 of 12 patients). Follow-up in these 10 patients demonstrated excellent patency through the stented segment in nine of the 11 treated vessels. Two patients, both of whom suffered their original dissection as a result of endarterectomy, required further angioplasty and stenting for stenosis outside the previously treated arterial segment. Regarding the treatment failures, a stent deployment device could not navigate a tortuous loop in one, while a microwire could not be advanced beyond a pseudoaneurysm in the second. Six patients had pseudoaneurysms, four of which were treated only with stenting across the dissected arterial segment. All pseudoaneurysms treated in this fashion resolved. No permanent complications occurred as a result of endovascular therapy. **Conclusions:** Angioplasty and stenting can be performed safely to manage carotid dissection. A pseudoaneurysm or tortuous anatomy can preclude therapy although the former typically resolves if angioplasty and stenting are feasible. Dissections secondary to endarterectomy may be associated with a higher rate of restenosis after stenting and may require further treatment.

RÉSUMÉ: Dissection de la carotide: facteurs techniques affectant le traitement endovasculaire. Introduction et Objectif: Les auteurs reviennent le traitement de 13 cas de dissection de la carotide extracrânienne afin d'identifier les facteurs associés au succès du traitement endovasculaire. **Méthodes:** Les dossiers de 12 patients présentant 13 dissections ont été révisés quant au mécanisme de la dissection, aux symptômes préopératoires, à la présence d'un pseudoanévrisme, au succès du traitement et à l'étiologie de l'échec du traitement. Les patients, six hommes et six femmes âgés de 27 à 62 ans, ont été suivis prospectivement. **Résultats:** L'angioplastie et la pose de prothèses endovasculaires ont été effectués avec succès lors de 11 des 13 interventions (10 patients sur 12). Le suivi de ces 10 patients a montré une excellente perméabilité au niveau de la prothèse endovasculaire chez neuf des 11 vaisseaux traités. Deux patients, qui avaient tous deux présenté une dissection suite à une endartérectomie, ont nécessité une nouvelle angioplastie et la mise en place d'une prothèse endovasculaire pour une sténose hors de la zone traitée antérieurement. En ce qui concerne les échecs, l'appareil de déploiement d'une prothèse endovasculaire n'a pas pu être guidé à travers une bouche d'une artère tortueuse dans un cas, alors qu'un microguide n'a pas pu être inséré au-delà d'un pseudoanévrisme dans le second. Six patients étaient porteurs de pseudoanévrismes, dont quatre ont été traités seulement par la mise en place d'une prothèse endovasculaire au niveau du segment artériel disséqué. Le traitement a été un succès dans tous ces cas et aucune complication permanente résultant du traitement endovasculaire n'est survenue. **Conclusions:** On peut traiter avec sécurité la dissection de la carotide par angioplastie et pose d'une prothèse endovasculaire. La présence d'un pseudoanévrisme ou d'une artère tortueuse peut entraver le traitement, bien qu'un pseudoanévrisme puisse se résorber avec l'angioplastie et la pose d'une prothèse endovasculaire lorsque c'est possible. Les dissections secondaires à une endartérectomie peuvent être associées à un taux de resténose plus élevé après la pose d'une prothèse endovasculaire et peuvent nécessiter une autre intervention.

Can. J. Neurol. Sci. 2002; 29: 54-60

Dissections of the cervical carotid artery occur spontaneously or as the result of trauma.¹⁻¹⁰ Spontaneous lesions account for 5% to 20% of ischemic cerebrovascular accidents (CVA) affecting patients under 60 years of age.⁶⁻¹⁰ Population-based analysis in the United States and France document an annual incidence of spontaneous carotid dissection in the range of 2.5 to 3 per 100,000.¹¹ Traumatic injuries to the carotid artery occur in 0.5% cases of head trauma and are associated with rates of mortality and significant morbidity approaching 40% and 80%, respectively.^{1,3,7-9} The first line of treatment is medical therapy, utilizing antiplatelet agents or anticoagulants in an effort to

reduce the likelihood of embolic and thrombotic complications.⁵⁻⁹ Surgical treatment of carotid dissections may be considered when symptoms persist despite medical therapy and when the lesion fails to resolve angiographically. Enlargement of an

From the Division of Neurological Surgery, Barrow Neurological Institute, St. Joseph's Hospital and Medical Center, Phoenix, Arizona USA.

RECEIVED FEBRUARY 28, 2001. ACCEPTED IN FINAL FORM AUGUST 14, 2001.

Reprint requests to: Cameron G. McDougall, c/o Neuroscience Publications, Barrow Neurological Institute, 350 West Thomas Road, Phoenix, AZ 85013-4496 USA

associated pseudoaneurysm and progressive vessel narrowing are other potential indications for surgical intervention. In addition, surgical repair or endovascular treatment may be required when anticoagulation or antiplatelet medications are contraindicated.^{1,2,4,12-14} While stent placement without the use of perioperative anticoagulants or antiplatelet agents may be associated with a higher risk of thrombosis or restenosis, these complications need to be weighed against the potential risk of stroke in the symptomatic patient harboring an untreated lesion. Such patients may also be candidates for direct surgical repair or vessel ligation as well as endovascular occlusive techniques such as balloon or coil occlusion of the offending artery.

Surgical treatment comprises a variety of techniques, including direct surgical repair, proximal carotid ligation, extracranial-intracranial carotid artery bypass, and carotid endarterectomy (CEA).^{1,2,4,12-15} A high cervical dissection, poor collateral circulation, and damaged tissue planes all contribute to the difficulty of these open techniques. The advent of endovascular methods offers the ability to re-establish patency from within the lumen of the damaged vessel, thereby reducing the likelihood of neurological injury from embolism or thrombosis. We report the results of percutaneous angioplasty and stenting (PTAS) in the treatment of 13 cases of carotid dissection, specifically assessing those factors that contribute to the success or failure of endovascular therapy.

MATERIALS AND METHODS

Over a five-year period at our institution, 12 patients (six men and six women) harboring 13 extracranial carotid dissections were treated with attempted angioplasty and stenting. All patients had failed conservative medical management or demonstrated either clinical or radiographic evidence of progressive disease. The patients' records and angiographic studies were reviewed to determine the mechanism of dissection, presenting symptoms, and factors associated with successful and failed endovascular therapy. The presence or absence of a pseudoaneurysm, location of the dissection, date and findings of follow-up neuroimaging, and overall clinical outcomes were also reviewed.

Endovascular Technique (Figure 1)

Patients were routinely placed on oral antiplatelet agents three days before PTAS, or they were given an intravenous agent such as ReoPro (Abciximab; Centocor B.V., Leiden, The Netherlands) when emergency conditions precluded oral pretreatment. Light sedation was administered to enhance the patient's comfort while still permitting a neurological examination throughout the procedure. An anesthesiologist was present to monitor the patient's comfort and hemodynamic fluctuations that could occur during angioplasty near the carotid bifurcation. In one patient (Patient 9), direct angioplasty and stenting were performed

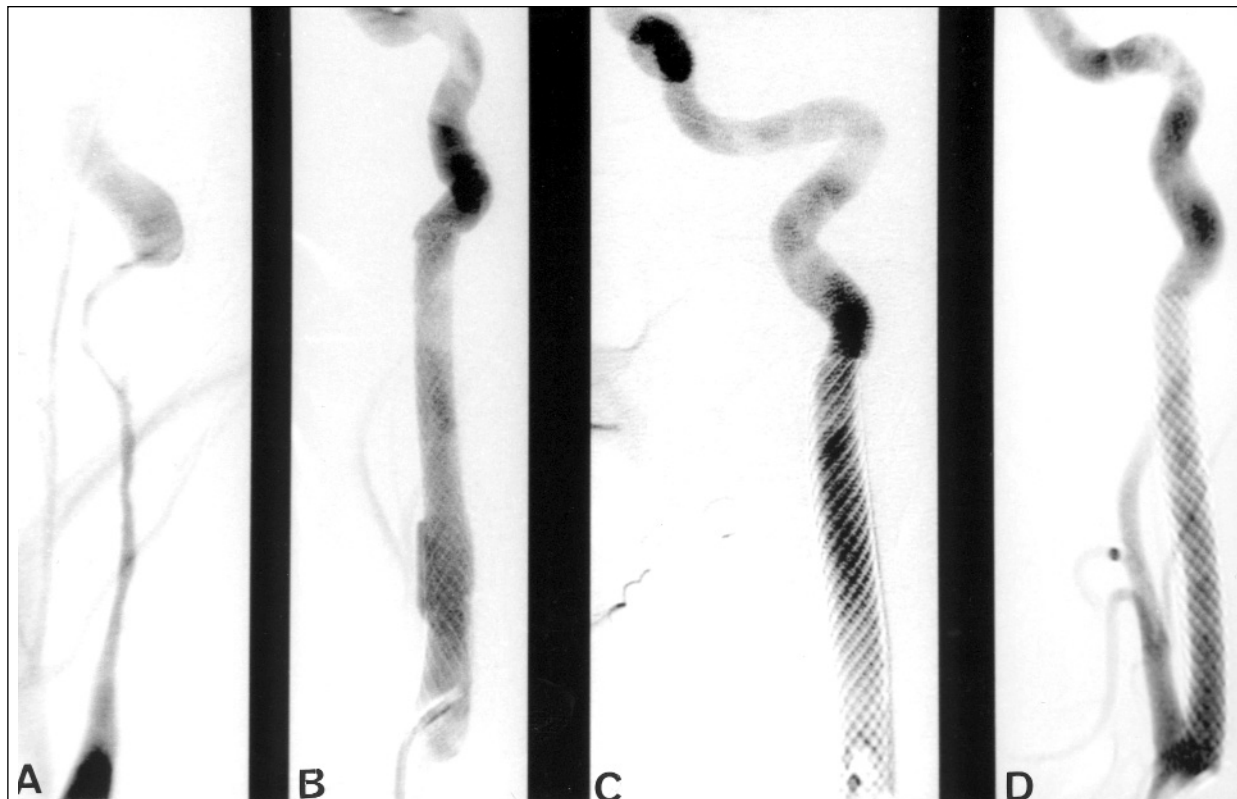


Figure 1: Illustrative case: This 43-year-old woman with a history of fibromuscular dysplasia presented with stroke. (A) Angiography of the left internal carotid artery (ICA) demonstrated a long dissection. The right ICA demonstrated a dissection of similar length (not shown). (B) Angiography immediately after stenting (of the left ICA) demonstrated improved vascular contour and wide patency. Follow-up at (C) three months and (D) one year confirmed continued wide patency and normalization of the vessel architecture. The right-sided lesion continues to show wide patency at one year as well.

Table: Summary of patient characteristics

Patient	Age/Sex	Type	SXs	Tx Indication	Site	PA	PTAS	Result	F/U
1	60M	S	Pain, CN	FMT	L ICA	Yes	No	Bypass	None
2	45M	S	CVA	FMT	L ICA	Yes	Yes	Good	1 yr
3	27M	S	Pain, CN	FMT	L ICA	No	Yes	Good	2 mos
4	58M	T	Bruit	RP	L ICA	No	Yes	Good	2 yrs
5	56F	T	Bruit	RP	L ICA	Yes	Yes	Good	6 mos
6	62M	T	Bruit	RP	R CCA	No	Yes	ReTX	1 yr
7	43F	S	CVA	FMT	R ICA	Yes	Yes	Good	1yr
7		S	CVA	FMT	L ICA	No	Yes	Good	1 yr
8	52F	T	None	RP	R CCA	Yes	Yes	Good	10 mos
9	57M	T	CVA	AND	L CCA	No	Yes	ReTX	1 yr
10	46F	S	TIA	FMT	R ICA	Yes	No	Bypass	None
11	44F	T	CVA	AND	R ICA	No	Yes	Good	4 mos
12	44F	S	CVA, TIA	FMT	L ICA	No	Yes	Good	2 mos

SXs=symptoms; PA=pseudoaneurysm; PTAS=percutaneous angioplasty and stenting; S=spontaneous; CN=cranial neuropathy, ICA=internal carotid artery; CVA=cerebrovascular accident; T=traumatic; CCA=common carotid artery; ReTX = required further angioplasty and stenting; TIA=transient ischemic attack; Tx=treatment; FMT=failed medical therapy; RP=radiographic progression; AND=acute neurological deterioration

through an open incision in the lateral neck after CEA failed. The remaining cases were performed through a transfemoral approach.

After vascular access was obtained, a bolus dose of heparin was administered to achieve an activated clotting time of 200 to 250 seconds. Diagnostic images were obtained to confirm the exact site of stenosis and to permit measurements necessary for selecting the appropriate angioplasty balloons and stents. Predilation of the artery was required in cases of severe stenosis. We favored self-expanding stents (Wallstent, Snyder USA, Inc., Minneapolis, MN; or Smart Stent, Johnson and Johnson, Miami, FL) because of their relative ease of deployment and low risk of permanent deformation. After the stent was deployed, a second, larger angioplasty balloon was often used to achieve complete apposition of the stent to the vessel wall and to improve the level of arterial patency. While larger than the pre-dilation balloon, the post-stenting balloon is not larger than the measured diameter of the normal artery. This lessens the risk of vessel or pseudoaneurysm rupture from overdilatation. Heparin was allowed to dissipate, and patients were monitored in the intensive care unit overnight. Antiplatelet therapy was continued indefinitely after successful PTAS.

RESULTS

Angioplasty and stenting were successful in 11 of 13 procedures (10 of 12 patients). Patients presented with symptoms of stroke, bruit, cranial neuropathy, and transient ischemic attack (TIA) in descending order of frequency (Table). Trauma, including two cases each of dissections after CEA and angiography, accounted for six of the cases referred to our service for endovascular therapy. The remaining six patients

developed their dissections spontaneously. Of this group, fibromuscular dysplasia accounted for two cases while the remaining four were idiopathic. Six patients had pseudoaneurysms, four of whom underwent successful PTAS and the pseudoaneurysms resolved. Dissections involved the internal carotid artery in 10 cases and the common carotid artery in the remaining three. Follow-up, either through ultrasonography or angiography, was obtained in all patients who underwent successful endovascular therapy and ranged from two months to two years.

Percutaneous angioplasty and stenting could not be performed in two patients. In the first (Patient 1), the stent device could not be deployed beyond a proximal, tortuous arterial loop (Figure 2). The second failure (Patient 10) involved a proximal pseudoaneurysm and severely narrowed distal arterial segment. The microwire persisted in entering the pseudoaneurysm and failed to engage the true vessel lumen (Figure 3). Despite treatment failure, neither patient suffered clinically as a result of the attempted endovascular therapy and both were referred for bypass surgery. One of these patients suffered a wound infection and died suddenly of unknown causes six months after surgery. The other sustained a minor stroke after her bypass but made an excellent recovery.

Both patients (Patients 6 and 9) who required repeat PTAS suffered their original dissections as a result of endarterectomy. Both underwent a second session of PTAS during a six-month follow-up visit for angiography. In both patients, restenosis occurred outside the originally stented segment (Figure 4). Patient 6 needed a third stenting procedure at a one-year follow-up visit when angiography revealed recurrent stenosis between the two previously stented segments. Angiography at one year in Patient 9 demonstrated that the patency of the stented segment

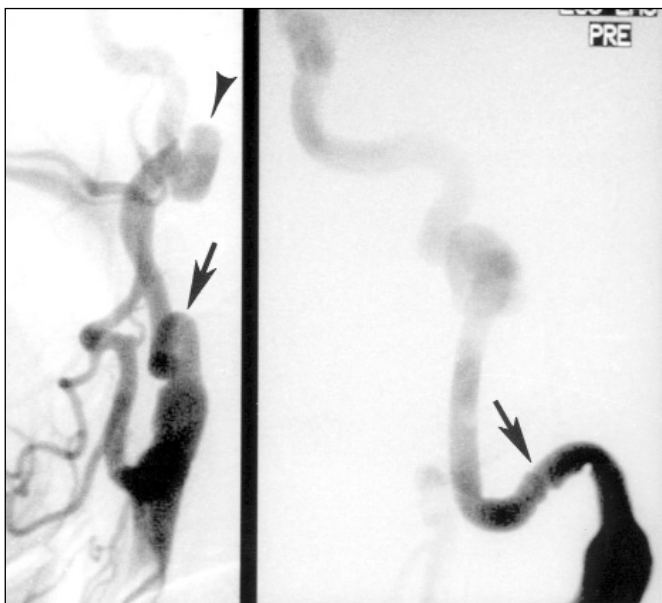


Figure 2: Oblique views of left common carotid artery demonstrating a high cervical dissection and associated pseudoaneurysm (arrowhead) of the internal carotid artery. Note the proximal arterial loop (arrows) which precluded stent deployment.

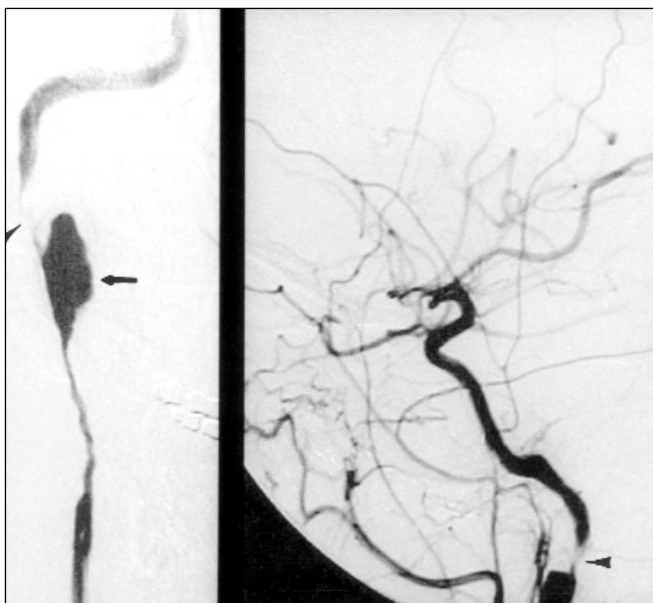


Figure 3: Anteroposterior and lateral views of the right internal carotid artery demonstrating a pseudoaneurysm (arrow) and very narrow distal arterial lumen (arrowheads). The microwire persisted in entering the pseudoaneurysm and could not engage the normal arterial lumen distally, thereby preventing stenting of the dissected segment.

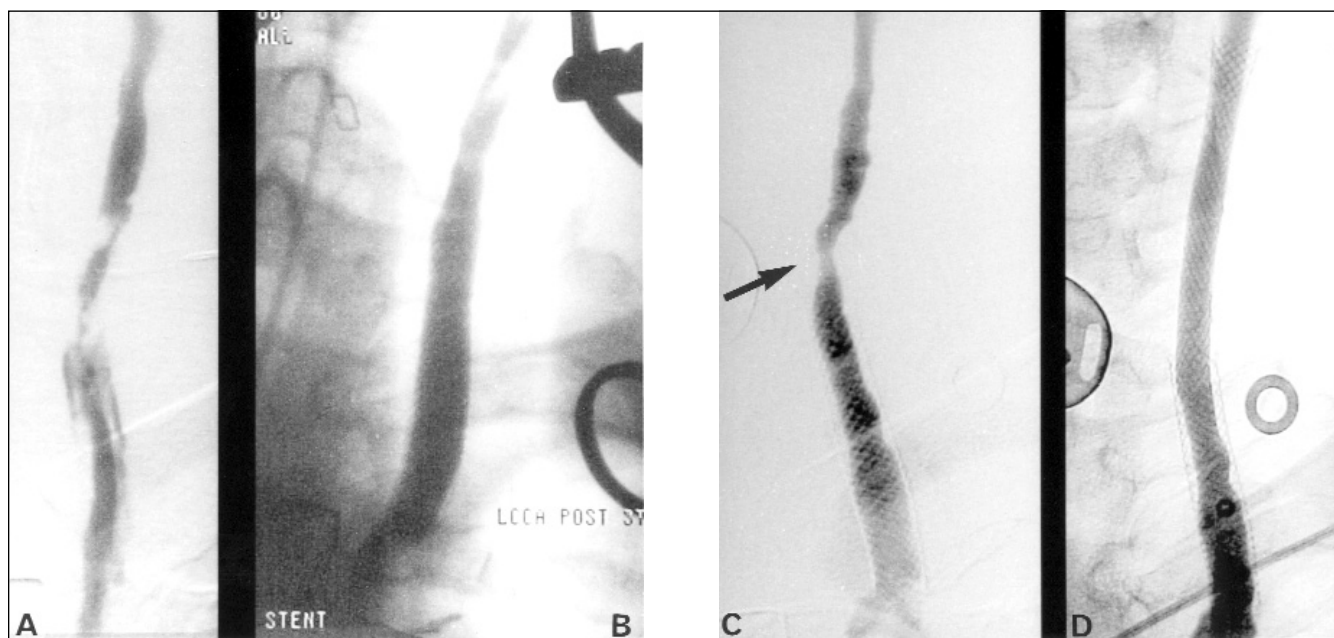


Figure 4: (A) Immediately following his second carotid endarterectomy, Patient 9 demonstrated a complex dissection of the proximal common carotid artery. (B) Following direct angioplasty and stenting through the cervical incision, normal patency of the proximal vessel was re-established. Mild irregularity of the distal common carotid artery remained. (C) Follow-up at six months, however, revealed stenosis (arrow) of the vessel just distal to the originally stented segment. A second stent was placed at that time. (D) One-year follow-up demonstrated wide patency through both stented segments.

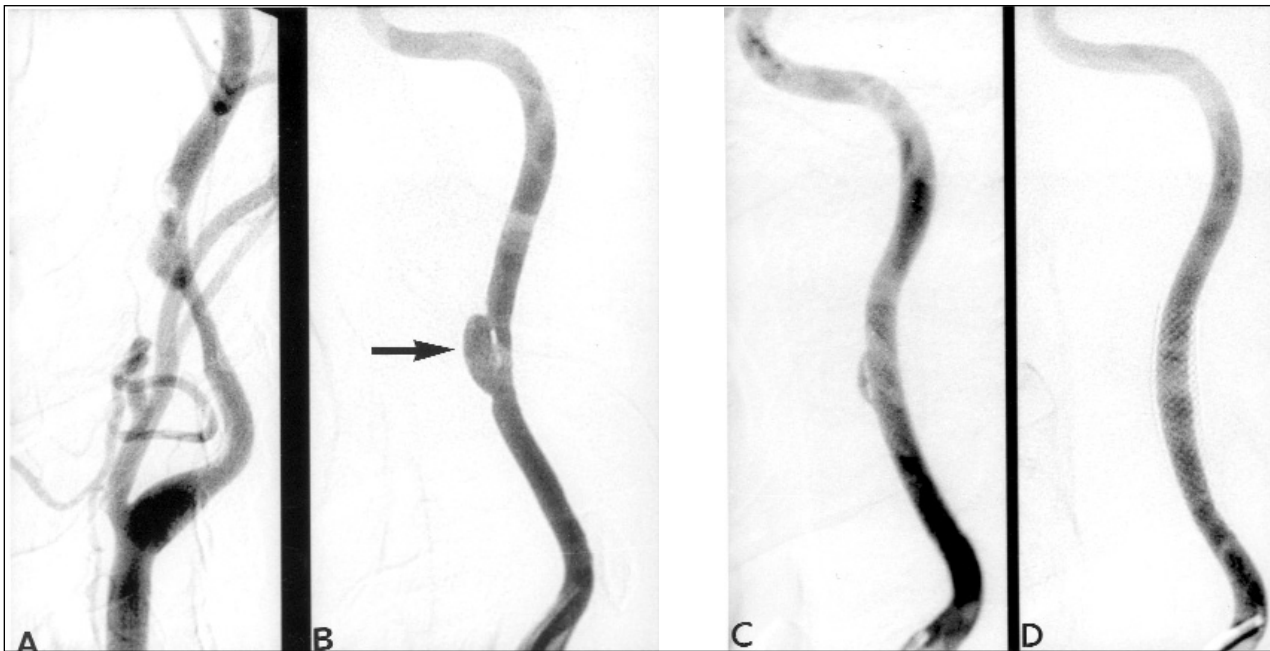


Figure 5: (A and B) Following a trial of medical therapy, Patient 2's pseudoaneurysm (arrow) failed to resolve. After stenting, (C) immediate and (D) one-year follow-up angiography, however, demonstrates progressive remodeling of the vessel and resolution of the pseudoaneurysm. Figure B and D from Spetzler RF, Koos WT (eds) (with contributions from Richling B): *Color Atlas of Microneurosurgery*, 2nd edition, Volume III: Intra- and Extracranial Revascularization and Intraspinal Pathology, Stuttgart, Georg Thieme Verlag, 1999. With permission from Georg Thieme Verlag.

was normal, obviating the need for further therapy. Patient 6 experienced transient ischemic attacks (TIA)s, which resolved with further stenting, while Patient 9 remained asymptomatic despite the restenosis. Re-treatment in Patient 9 was undertaken despite the lack of symptoms because of the radiographic progression of the patient's stenosis.

One of the two patients (Patient 11) who suffered a dissection as a result of angiography was referred to our service during follow-up assessment of a previously clipped aneurysm. She demonstrated moderate-to-severe vasospasm on intracranial angiography. After dissection of her right internal carotid artery, intracranial flow was markedly restricted with limited filling of the cortical branches of the middle cerebral artery (MCA), suggesting thrombosis of this segment. She suffered an immediate hemiparesis during angiography. Stenting her internal carotid artery lesion caused the dissection to progress into the petrous carotid segment, necessitating the placement of a stent there as well. When blood flow through the cervical carotid improved, intracranial angiography confirmed thrombotic occlusion of the trifurcation of the MCA. Despite significant improvement in blood flow through the MCA after transarterial thrombolysis, the patient failed to make a significant neurological recovery. Follow-up ultrasonography at four months demonstrated a widely patent internal carotid artery throughout the stented segment.

DISCUSSION

Despite the relative ease of performing PTAS to treat carotid dissections, a number of complications are unique to this

therapy.^{2,4,6,12,16-24} If the stent is sized improperly or misplaced, it may fail to improve vessel patency. Additional stents may need to be placed, thereby compounding the overall risk of the procedure. Thrombotic debris can embolize during the performance of angioplasty. The frequency of this complication is reduced by systemic heparinization during PTAS and by administering antiplatelet medications before surgery. In the event of embolization, intra-arterial thrombolysis may be required. Vessel rupture is a rare complication of PTAS for carotid dissection but can produce devastating consequences. Gradual inflation of the angioplasty balloons and smooth unsheathing of the stent deployment device minimize its occurrence.

Restenosis can occur after PTAS of a carotid dissection during either the chronic or acute phase after treatment. Thrombosis is usually the cause of acute occlusion while myointimal hyperplasia produces restenosis in a subacute and chronic manner.¹⁷ Myointimal hyperplasia is usually asymptomatic because the smooth muscle proliferation within the vessel lumen rarely produces emboli. Rather, it generates symptoms of ischemia only when blood flow through the stented segment becomes critically slow.¹⁷

Results of other series of carotid dissection managed endovascularly underscore the efficacy of this treatment strategy. Liu et al⁶ reported normal vessel patency over a 3.5-year mean follow-up period in six of seven patients treated with PTAS for a variety of indications including radiographic progression of the lesion and ischemic symptoms. The authors also documented resolution of two of four pseudoaneurysms with stenting alone.⁶ In a series of six patients treated endovascularly for carotid

dissection, Duke et al¹² reported no ischemic complications as a result of PTAS and normal patency in follow-up ranging from two to seven months. Patients in this series were treated with PTAS largely based on radiographic criteria that included enlargement of an associated pseudoaneurysm and progression of the dissection.¹² Finally, Bejjani et al² reported no procedure-related complications in a series of five patients treated endovascularly for either progressive symptoms despite medical therapy or because of the severity of the original dissection. All patients in this series, moreover, experienced an improvement in their ischemic symptoms within 24 hours of stenting.²

Despite these promising results, our series has delineated a number of clinical and radiographic states that can complicate endovascular treatment of carotid dissections. Patients who suffer carotid dissection as a result of CEA may have a higher risk of restenosis after stenting. Interestingly, both of our patients with this complication demonstrated new stenoses in regions outside both the original operative and stented segments. Restenosis through the stented segment may occur as a result of the underlying atherosclerotic disease and scarring of the vessel wall, both of which may increase the recoil forces placed upon the stent.²⁵ Myointimal hyperplasia, either as the result of a prior CEA or because of stent placement, can also account for restenosis in a subacute fashion while progression of atherosclerosis may predispose to chronic renarrowing through the stented segment. In our two cases, restenosis occurred in a subacute fashion and was smooth in appearance. These features suggest that myointimal hyperplasia somehow occurred in segments once considered normal. It is possible that unrecognized surgical scarring or injury during the initial endovascular treatment predisposed the vessel to intimal hyperplasia in previously untreated segments.

The presence of a pseudoaneurysm or tortuous arterial anatomy, as seen in elderly patients, can also complicate the endovascular treatment of carotid dissection. In the former, the guidewire may persistently enter the channel leading to the pseudoaneurysm and not engage the true vessel lumen. In the latter, optimal placement of the guiding catheter and stent deployment device may not be attainable. The two treatment failures in this series occurred secondary to these complicating factors. In both cases, eventual surgical bypass was complicated, confirming the technically demanding nature of open operative procedures for the treatment of carotid dissection.

The four treated pseudoaneurysms in this series resolved after stenting albeit not acutely in all cases. Patient 2 demonstrated gradual remodeling of the affected arterial segment with eventual obliteration of the aneurysm (Figure 5). This outcome supports the previously held supposition that stenting across the orifice of an aneurysm can redirect flow away from the aneurysm, producing its eventual thrombosis.^{21,22} In cases of large pseudoaneurysms, other treatment strategies, such as using covered stents or coiling through a previously placed porous stent, may be necessary to obliterate the lesion.^{6,23} Our series, however, supports conservative management of small pseudoaneurysms. In such cases, one may wish to defer other treatments such as coil embolization for several months in the hope that vessel remodeling will eventually produce thrombosis of the aneurysm, as occurred in Patient 2.

In cases like Patient 11, who deteriorated acutely because of

her dissection and associated intracranial thrombosis in the setting of moderate-to-severe vasospasm, endovascular treatment of carotid dissection may be considerably more complex. In such cases, one must be prepared to undertake other therapeutic maneuvers such as thrombolysis and intracranial angioplasty. Restoration of blood flow can reverse neurological deficits, but it can also propagate thrombus and subject the patient to other complications such as intracranial hemorrhage and vessel rupture. Undoubtedly, neurologically unstable patients are more prone to complications from the treatment of carotid dissection and may not recover neurological function even after successful angioplasty and stenting if other concomitant disease states exist, as was the case for Patient 11.

In conclusion, while medical therapy is the optimal treatment for carotid dissection, endovascular techniques are a safe and effective means of managing refractory cases. Percutaneous angioplasty and stenting offers the advantages of restoring cerebral blood flow and preventing embolic and flow-related complications. Select cases may pose a greater degree of technical difficulty or require multiple therapeutic interventions, including lesions that occur after CEA or patients who have deteriorated neurologically in an acute fashion. Although pseudoaneurysms can preclude treatment, they often resolve through a process of gradual vessel remodeling when stenting is successful. Tortuous arterial anatomy is another factor that can complicate or prevent the use of PTAS in the treatment of carotid dissection.

REFERENCES

1. Anson J, Crowell RM. Cervicocranial arterial dissection. *Neurosurgery* 1991;29:89-96.
2. Bejjani GK, Monsein LH, Laird JR, et al. Treatment of symptomatic cervical carotid dissections with endovascular stents. *Neurosurgery* 1999;44:755-761.
3. Biousse V, D'Anglejan-Chatillon J, Touboul P-J, Amarenco P, Bousser M-G. Time course of symptoms in extracranial carotid artery dissections. A series of 80 patients. *Stroke* 1995;26:235-239.
4. Coric D, Wilson JA, Regan JD, Bell DA. Primary stenting of the extracranial internal carotid artery in a patient with multiple cervical dissections: technical case report. *Neurosurgery* 1998;43:956-959.
5. Guillon B, Lévy C, Bousser M-G. Internal carotid artery dissection: an update. *J Neurol Sci* 1998;153:146-158.
6. Liu AY, Paulsen RD, Marcellus ML, Steinberg GK, Marks MP. Long-term outcomes after carotid stent placement for treatment of carotid artery dissection. *Neurosurgery* 1999;45:1368-1374.
7. Mokri B, Piepgras DG, Houser OW. Traumatic dissections of the extracranial internal carotid artery. *J Neurosurg* 1988;68:189-197.
8. Schievink WI, Michels VV, Piepgras DG. Neurovascular manifestations of heritable connective tissue disorders. A review. *Stroke* 1994;25:889-903.
9. Schievink WI, Mokri B, O'Fallon WM. Recurrent spontaneous cervical-artery dissection. *N Engl J Med* 1994;330:393-397.
10. Sturzenegger M, Huber P. Cranial nerve palsies in spontaneous carotid artery dissection. *J Neurol Neurosurg Psychiatry* 1993;56:1191-1199.
11. Schievink WI. Spontaneous dissection of the carotid and vertebral arteries. *N Engl J Med* 2001;344:898-906.
12. Duke BJ, Ryu RK, Coldwell DM, Brega KE. Treatment of blunt injury to the carotid artery by using endovascular stents: an early experience. *J Neurosurg* 1997;87:825-829.
13. Pozzati E, Giuliani G, Poppi M, Faenza A. Blunt traumatic carotid dissection with delayed symptoms. *Stroke* 1989;20:412-416.

14. Richardson JD, Simpson C, Miller FB. Management of carotid artery trauma. *Surgery* 1988;104:673-680.
15. Early TF, Gregory RT, Wheeler JR, et al. Spontaneous carotid dissection: duplex scanning in diagnosis and management. *J Vasc Surg* 1991;14:391-397.
16. Chalmers RTA, Brittenden J, Bradbury AW. The use of endovascular stented grafts in the management of traumatic false aneurysms: a caveat. *J Vasc Surg* 1995;22:337-338.
17. Crawley F, Brown MM, Clifton AG. Angioplasty and stenting in the carotid and vertebral arteries. *Postgrad Med J* 1998;74:7-10.
18. Dorros G, Cohn JM, Palmer LE. Stent deployment resolves a petrous carotid artery angioplasty dissection. *AJNR Am J Neuroradiol* 1998;19:392-394.
19. Griewing B, Brassel F, Schminke U, Kessler C. Angioplasty and stenting in carotid artery dissection. *Eur Neurol* 1998;40:175-176.
20. Hong MK, Satler LF, Gallino R, Leon MB. Intravascular stenting as a definitive treatment of spontaneous carotid artery dissection. *Am J Cardiol* 1997;79:538.
21. Horowitz MB, Miller G, III, Meyer Y, Carstens G, III, Purdy PD. Use of intravascular stents in the treatment of internal carotid and extracranial vertebral artery pseudoaneurysms. *AJNR Am J Neuroradiol* 1996;17:693-696.
22. Hurst RW, Haskal ZJ, Zager E, Bagley LJ, Flamm ES. Endovascular stent treatment of cervical internal carotid artery aneurysms with parent vessel preservation. *Surg Neurol* 1998;50:313-317.
23. Marotta TR, Buller C, Taylor D, Morris C, Zwimpfer T. Autologous vein-covered stent repair of a cervical internal carotid artery pseudoaneurysm: technical case report. *Neurosurgery* 1998;42:408-413.
24. Perez-Cruet MJ, Patwardhan RV, Mawad ME, Rose JE. Treatment of dissecting pseudoaneurysm of the cervical internal carotid artery using a wall stent and detachable coils: case report. *Neurosurgery* 1997;40:622-626.
25. Lanzino G, Mericle RA, Lopes DK, et al. LN. Percutaneous transluminal angioplasty and stent placement for recurrent carotid artery stenosis. *J Neurosurg* 1999;90:688-694.