

# The Neurapraxic Lesion: A Clinical Contribution to the Study of Trophic Mechanisms

A. J. McCOMAS, P. B. JORGENSEN and A. R. M. UPTON

**SUMMARY:** *Four patients with neurapraxic lesions are described; in spite of the absence of impulse activity in muscle fibers no other signs of denervation could be detected. These observations are interpreted as indirect evidence for the role of a non-impulsive (axoplasmic flow) system in certain trophic phenomena. The relationship of the present findings to the spectrum of neuropathic lesions is considered.*

**RÉSUMÉ** *Quatre patients avec des lésions neurapraxiques sont décrits; en dépit de l'absence d'une activité impulsive dans les fibres du muscle, aucun autre signe de dénervation ne pouvait être détecté. Ces observations sont interprétées comme évidence indirecte pour le rôle d'un système non-impulsif (flux d'axoplasme) dans certains phénomènes trophiques. Le rapport des conclusions présentes au spectre des lésions neuropathiques est ci-considéré.*

One of the most debated issues in modern neurobiology is the nature of the trophic influence which excitable cells in synaptic contact are able to exert upon each other. Two possible mechanisms have been recognized; one is impulse activity and the other is the passage of special messenger molecules from one cell to the other. In the case of the system most frequently studied, that comprising motoneuron and muscle fiber, the evidence presently available appears to be equally in favor of chemically- and impulse-mediated mechanisms. Nevertheless valid objections may be raised against most of the experimental strategies which have been used — for example, the isolated cord preparation, tenotomy, chronic stimulation, and the use of pharmacological agents such as local anaesthetics, colchicine, curare and botulinum toxin. In this short report it would be inappropriate to pursue these objections, particularly as some have been considered in detail elsewhere (Guth, 1968; Gutmann, Schiaffino and Hanzlikova, 1971) and the whole field of trophic phenomena has formed the subject of a recent symposium (Drachman, 1974). Instead, evidence of a different type will be presented which strongly supports the concept of a chemical mechanism as being sufficient for several important trophic effects of nerve on muscle. This evidence has come from the study of patients with electrophysiological evidence of impulse conduction block in peripheral nerves. Since the clinical and EMG findings in such patients indicated that the axons remained in continuity distal to the lesions, we refer to the latter as 'neurapraxic' (Seddon, 1943); they correspond to the

'first degree' nerve injuries of Sunderland (1951). Four examples will be cited; in two patients the nerves were injured by compression of the limbs, a common cause of a 'true' neurapraxic lesion. The third example is of rather greater neurological interest for it demonstrates the presence of neurapraxic features in a frequently occurring nerve entrapment syndrome. In all these patients it will be shown that, in the absence of nerve impulses, the muscle fibers were still able to maintain functional sole-plates and normal impulse generating mechanisms; fibrillation activity remained suppressed and the muscle fibers showed little or no evidence of atrophy. In addition, the non-excited muscle fibers appeared unable to attract and accept a new innervation. The inference is that, in such cases, an adequate trophic influence had been continued through the persistence of a non-impulsive mechanism, that is, the chemical pathway.

The fourth patient is of importance for an additional reason; she illustrates that following nerve injury, the distal part of an axon may lose its excitability without necessarily undergoing degeneration or demyelination. In the Discussion it will be shown that the significance of neurapraxic lesions in trophic phenomena has an interesting historical background; it is curious that so little attention should have been paid to it in the recent controversy.

## METHODS

Standard electrophysiological techniques were used for the recording of orthodromically-conducted sensory nerve potentials (McComas, Sica and Upton, 1974) and for the study of muscles with coaxial needle

From the Department of Medicine (Neurology) and the Medical Research Council's Developmental Neurobiology Research Group; McMaster University Medical Centre, 1200 Main St. W., Hamilton, Ontario.

Reprint requests to Dr. A. J. McComas, McMaster University Medical Centre, 1200 Main St. W., Hamilton, L8S 4J9, Ontario, Canada.

electrodes (Disa type 9013L0501). In addition the motor unit counting technique of McComas, Fawcett, Campbell and Sica (1971) was applied to the thenar and hypothenar muscles; a full account of this application has been given elsewhere (Sica, McComas, Upton and Longmire, 1974).

## RESULTS

*Case 1. Median and ulnar nerve palsy.* Miss G. L. was an 11-year-old school girl who, two months before the EMG examination, had caught her left arm between the rollers of a clothes wringer; the arm had been drawn in to the mid-forearm level. Immediately after the accident she had noticed numbness of the whole hand and muscle weakness; the latter affected all the intrinsic muscles of the left hand together with the extensors of the fingers and wrist. Both sensation and muscle strength were improving up to the time of study and there was no evidence of muscle atrophy.

The electrophysiological findings are set out in Tables 1-3 and Fig. 1. It can be seen that although all the amplitudes of the sensory responses in the affected hand were within the normal ranges the values for the radial and median nerves were only about half of those for the corresponding nerves of the normal side (Table 2). All these measurements were obtained by stimulating the appropriate digits and recording from the nerves at the wrist. On the basis of the motor unit counting technique only about 142 thenar and 131 hypothenar motor units could be excited by stimulation of the median and ulnar nerves respectively at the wrist (Table 1). None of the potentials of the 11 thenar motor units studied with the stimulation technique were enlarged, which suggested that little, if any, collateral reinnervation of muscle fibres had taken place. Of the 12 hypothenar motor units examined, only 2 had large potentials. When the median and ulnar nerves were stimulated at the elbow the amplitudes of the evoked M waves were reduced to roughly one third of those when stimulation was applied to the wrist (Fig. 1). The

normal configurations of the M waves following proximal stimulation made it unlikely that temporal dispersion could have been responsible for the reductions in amplitude. Lastly, exploration of thenar muscles with coaxial needle electrode revealed no evidence of fibrillation activity (Fig. 1, lower).

Comparison of these motor unit counts with the control mean values (Table 1) allowed the following interpretation of the results to be

made. In only about 11 and 13 percent respectively of ulnar and median motor axons had there been impulse conduction through the region of maximum damage in the forearm. In a further 22 and 29 percent of axons respectively there was inexcitability at the site of trauma but normal excitability beyond it (the true 'neurapraxic' lesion). Finally, 66 percent of ulnar nerve axons and 58 percent of median nerve axons either could not be ex-

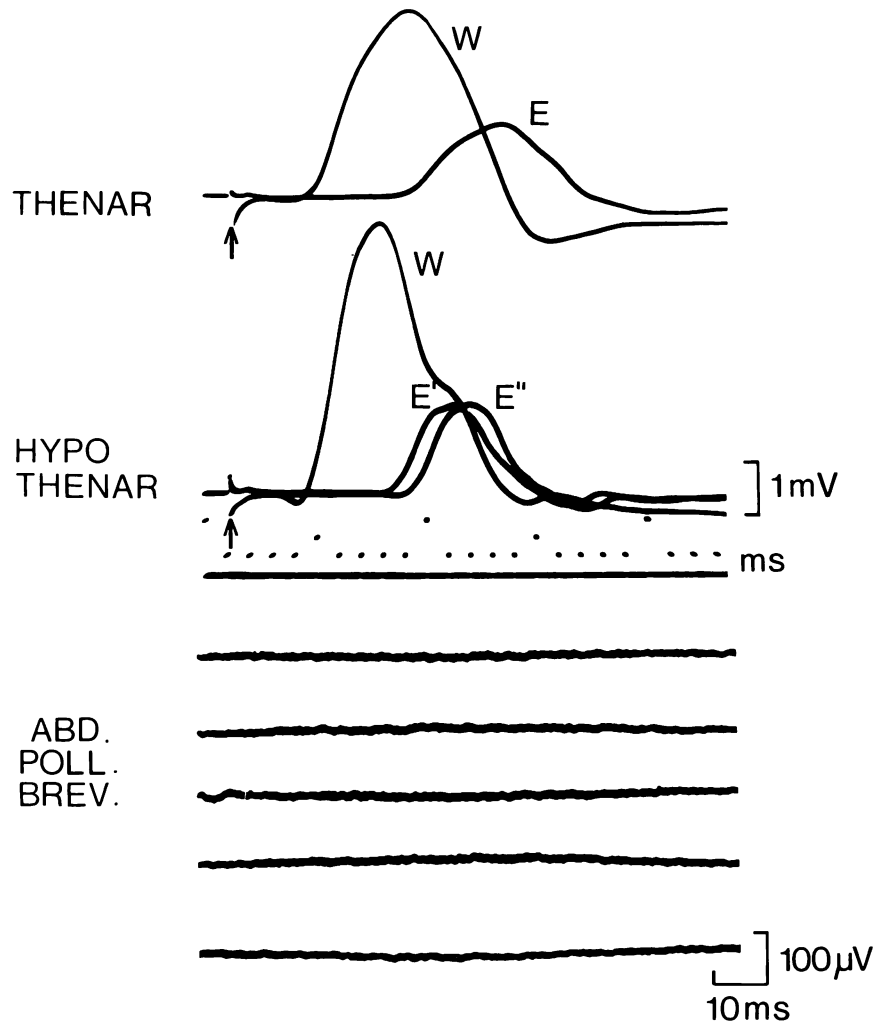


Figure 1 — Muscle findings in Case 1. At top are superimposed traces showing responses evoked in thenar muscles following stimulation of median nerve at wrist (response W) and at elbow (response E). Both stimuli delivered after 1 ms delay (arrow).

Middle section displays recordings from hypothenar muscles after stimulation of ulnar nerve at wrist (response W) and below and above elbow (responses E' and E'' respectively).

Lower. Serial sweeps of recordings from abductor pollicis brevis with coaxial needle electrode; no spontaneous activity visible.

Table 1

		Case 1		Case 2		Case 3		Case 4		Controls
		(L)	(R)	(L)	(R)	(L)	(R)	(L')	(L'')	( $\bar{X} \pm S.D.$ )
Thenar	Units	142*	370	—	71*	0*	73*	0*	73*	347 $\pm$ 95
	Response (mV)	4.0	7.6	6.0	3.5	0*	2.2*	0*	2.2*	12.7 $\pm$ 5.0
Hypothenar	Units	131*	470	—	180*	25*	203*	25*	203*	384 $\pm$ 89
	Response (mV)	4.8*	10.8	—	12.6	1.4*	6.5	1.4*	6.5	13.9 $\pm$ 5.0

Numbers of motor units and maximum evoked potentials of thenar and hypothenar muscles in 4 patients (see text) and in controls. The left arm of Case 4 was examined 34 weeks after the initial observations (results L' and L'' respectively). Low values indicated by asterisk.

Table 2

Nerve	Case 1		Case 2		Case 3		Case 4			Controls
	(L)	(R)	(L)	(R)	(L)	(R)	(L')	(L'')	(R')	( $\bar{X} \pm S.D.$ )
Radial I	25	40	25	20	7*	10	25	30	20	24 $\pm$ 7.5
Median I	29	57	52	40	15	7*	45	45	25	35 $\pm$ 12.6
	20	38	45	36	26	7*	20	35	25	30 $\pm$ 10.4
	20	38	47	45	20	10*	35	48	32	35 $\pm$ 12.1
	15	—	35	27	6*	3*	16	16	18	20 $\pm$ 8.9
Ulnar	16	—	27	20	5*	6*	12	10	26	18 $\pm$ 8.9
	15	16	24	23	10	12	14	14	13	17 $\pm$ 6.3

Amplitudes (uV) of sensory nerve potentials recorded with surface electrodes at wrist following stimulation of appropriate digits. Results in Case 4 were obtained at initial examination (L', R') and 34 weeks later (L''). Low values indicated by asterisks.

Table 3

Nerve	Case 1		Case 2		Case 3		Case 4			Controls
	(L)	(R)	(L)	(R)	(L)	(R)	(L')	(L'')	(R)	( $\bar{X} \pm S.D.$ )
Radial I	38*	45	47	52	44	53	50	39*	59	52 $\pm$ 7.2
Median I	41	46	53	53	38*	33*	54	42	50	52 $\pm$ 6.5
	48	64	58	55	—	41*	63	48	63	57 $\pm$ 5.5
	48	56	58	55	*	39*	56	54	63	56 $\pm$ 5.5
	50	—	58	55	43*	32*	56	43*	63	57 $\pm$ 5.9
Ulnar	42*	—	58	55	60	62	63	50	63	58 $\pm$ 5.0
	44*	53	50	50	55	61	54	51	58	54 $\pm$ 5.5

Maximum impulse conduction velocities (m/s) of digital nerves. Results in Case 4 were obtained at initial examination (L', R') and 34 weeks later (L''). Low values indicated by asterisks.

cited distal to the level of the lesion or else neuromuscular transmission was ineffective.

*Case 2. Right anterior interosseous nerve palsy.* Mr. S. M. was a 23-year-old student who had cut the flexor aspect of the right little finger on the metal lid of a pharmaceutical container. The wound was deep enough to have severed the tendon of the flexor digitorum profundus;

the wound was therefore explored on the day of the accident and the cut ends of the tendon were sutured together. To further promote healing, a plaster slab was applied over the dorsal aspects of the semiflexed little finger, the hand and the distal two thirds of the forearm. The slab was firmly bandaged in position and the arm was put into a sling. The patient was aware of some swelling of the hand soon after the operation.

One week later he was allowed to discard the sling; the arm felt tight within its bandaging. Four weeks after the injury the slab was removed; the patient then found that he was unable to flex the ends of his right thumb and index finger. There was no loss of sensation and his hand was otherwise normal. Eight weeks later (12 weeks after injury) clinical examination revealed some wasting of forearm flexor muscles

with weakness of the flexor digitorum profundus (particularly of the part supplying the index finger) and flexor pollicis longus. In contrast to the other affected muscles, the paralyzed pronator quadratus was noticeably enlarged. No sensory loss could be demonstrated. An electromyographic investigation was carried out, the results of which are shown in Tables 1-3 and Fig. 2. On examination with a coaxial electrode, the following results were obtained:

*R. Flexor pollicis longus:* profuse fibrillation activity (Fig. 2, upper); occasional fasciculation potentials; no volitional discharges.

*R. Flexor digitorum profundus:* considerable fibrillation activity; occasional fasciculation potentials; very reduced interference pattern on volition (Fig. 2, middle).

*R. Flexor digitorum sublimis:* no spontaneous electrical activity; full interference pattern and normal action potentials during voluntary effort.

*R. Pronator quadratus:* no spontaneous activity and no potentials detected during attempted muscle contraction (Fig. 2, lower).

Further testing showed that all the median sensory nerve fiber responses were normal in the right arm (Tables 2 and 3) as was the thenar motor unit population (Table 1). These last results indicated that the main trunk of the right median nerve was intact and that the paralysis of the flexor muscles in the forearm must have resulted from localized damage to the anterior interosseous nerve. It is probable that this nerve had been compressed by the upper margin of the bandage around the forearm. Electrical stimulation over the anterior interosseous nerve in the distal half of the forearm, beyond the presumed site of injury, yielded evoked potentials from pronator quadratus (noted but not photographed). No treatment was given

and during the ensuing four months some recovery had gradually taken place in the paralyzed muscles, though this was still far from complete. It is of interest that in the

pronator quadratus, no fibrillations were detected on 3 separate occasions and that the return of voluntary activity coincided with shrinkage of the muscle to its former size.

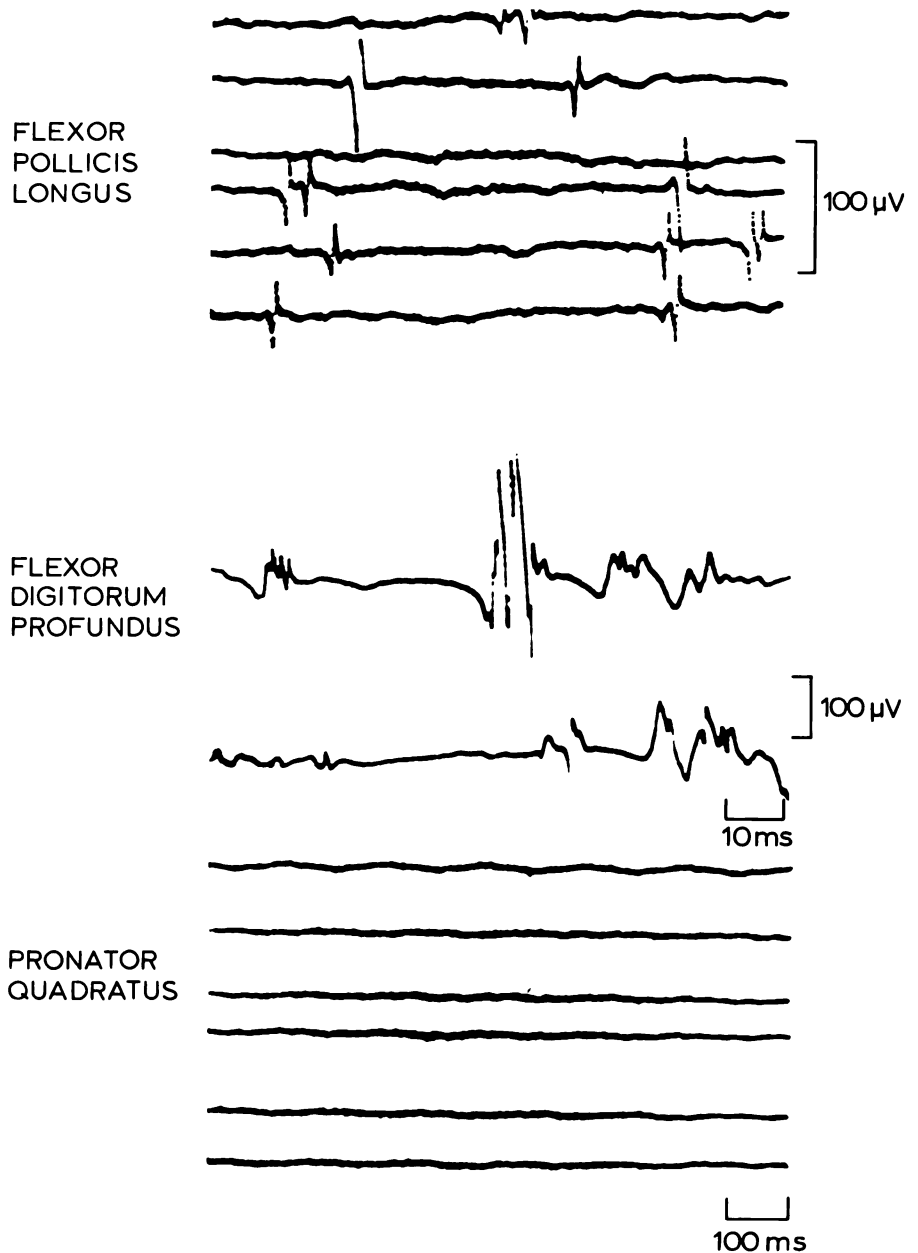


Figure 2 — Muscle findings in muscles of right arm of Case 2. At top is record during attempted contraction of flexor pollicis longus, showing profuse fibrillation potentials and absence of volitionally-induced activity.

Middle section displays the very reduced interference pattern recorded during maximum contraction of flexor digitorum profundus.

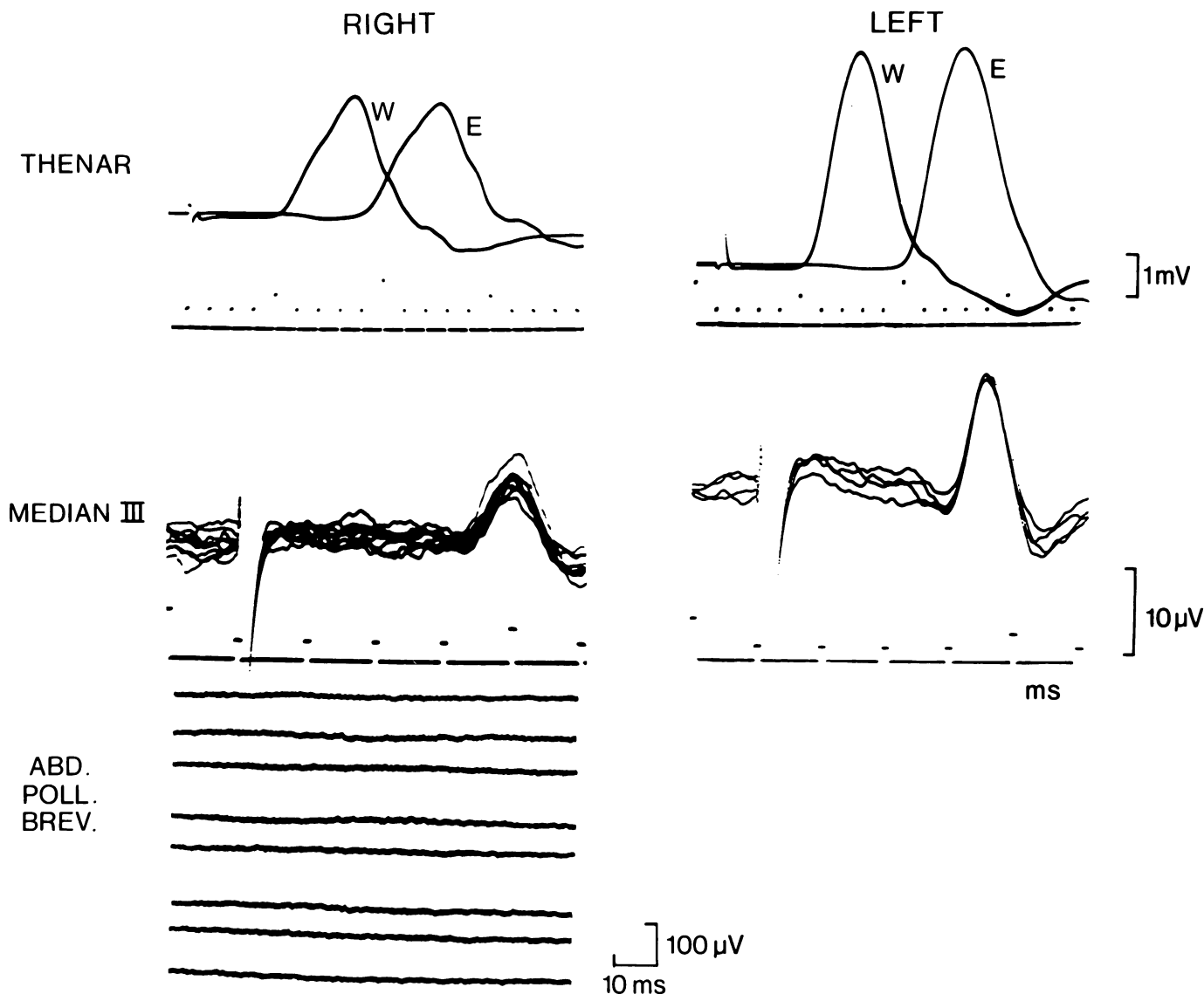
Lower section shows absence of volitional or spontaneous activity during attempted use of the pronator quadratus muscle.

*Case 3. Carpal tunnel syndrome.* Mr. G. G. was a 39-year-old factory worker with a one-month history of numbness and tingling in the middle and ring fingers of the right hand. There was no history of pain or stiffness in the neck. On examination, Tinel's and Phalen's signs were both negative. There was quite marked weakness of the right abductor pollicis brevis but no evidence of

thenar muscle atrophy. Sensation to light touch and pinprick was diminished over the middle finger and radial border of the ring finger.

The electrophysiological findings are set out in Tables 1-3 and displayed in Fig. 3. The clinical diagnosis of a right carpal tunnel syndrome was confirmed by the presence of small sensory nerve responses to stimulation of digital

branches of the median nerve together with slowing of impulse conduction across the wrist. In keeping with this diagnosis was the marked reduction in the numbers of functioning motor units in the thenar muscles of the right hand, with about 71 units remaining. In spite of the fact that roughly 80 percent of the thenar muscle fibers were functionally denervated, there was no clinical



*Figure 3* — Electrophysiological findings in Case 3. At top are superimposed traces showing responses evoked in left and right thenar muscles following stimulation of median nerves at wrists (responses W) and at elbows (responses E).

Middle section displays sensory fiber potentials recorded in median nerves at wrists after stimulation of corresponding middle fingers.

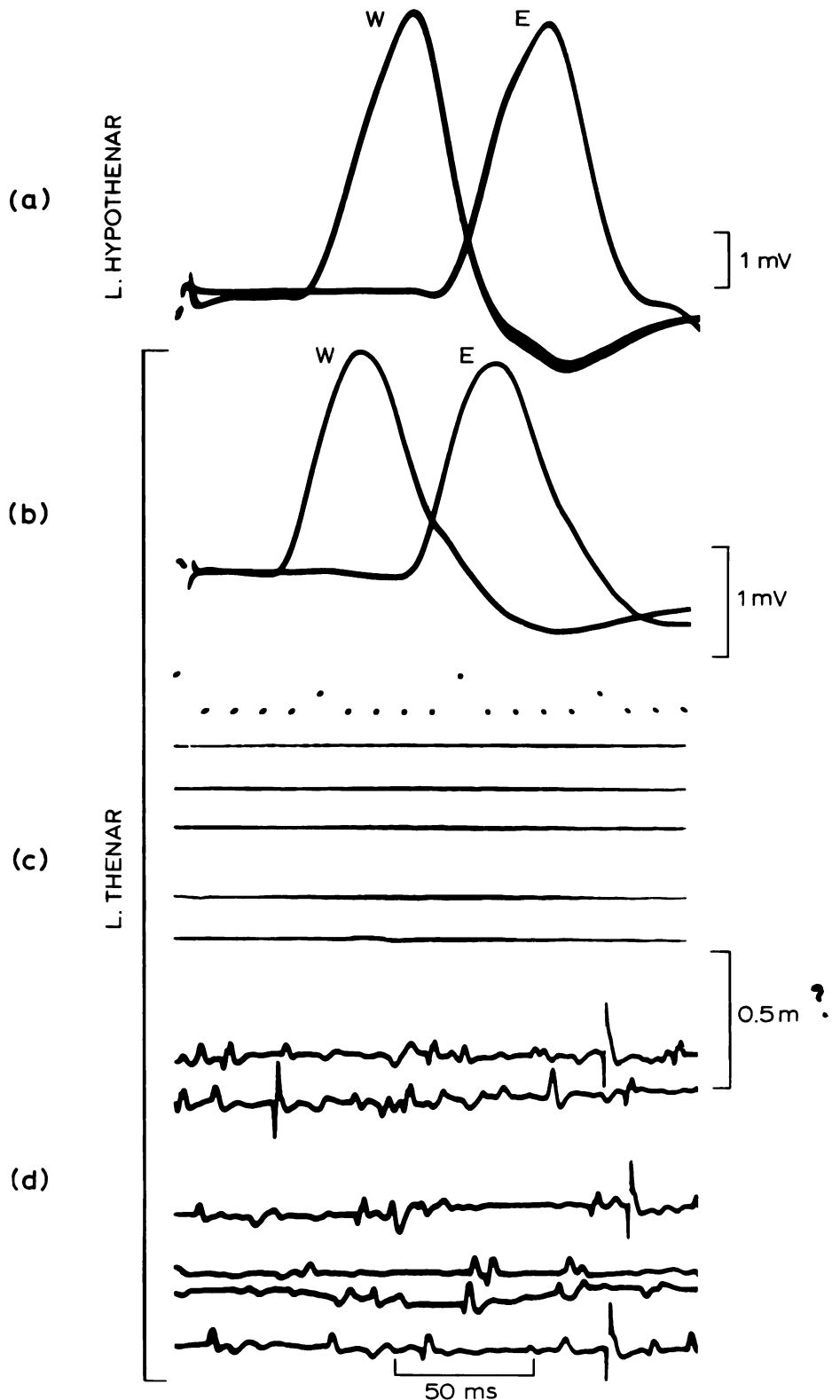
Lower. Serial sweeps of recordings from right abductor pollicis brevis with coaxial needle electrode; no spontaneous activity visible.

Notice the larger sizes of the evoked motor and sensory responses on the left side in the top and middle sections, also the greater delay in the conducted sensory potential on the right.

cal sign of atrophy, no fibrillation potentials could be detected, and — on the basis of the normal sizes of the 10 motor unit potentials studied, no reinnervation of muscle fibres had taken place. Although there had been no history of neck symptoms it is likely that this patient was an example of a 'double crush' syndrome (Upton and McComas, 1973) since, in the right arm, there was evidence of chronic muscle denervation outside the median nerve territory. Thus the hypothenar count was also reduced (180 units; lower limit of normal range — 250 units) and, on coaxial needle electromyography, large prolonged muscle action potentials were encountered in the deltoid and extensor digitorum muscles. Since the hypothenar results were not associated with impulse slowing in the cubital tunnel segment of the right ulnar nerve it was likely that a C8 or T1 root lesion was involved instead. Similarly, the results in the extensor digitorum and deltoid made the added presence of C6 and C7 root lesions probable. The sensory nerve results were of additional interest for they suggested that a carpal tunnel syndrome was developing in the clinically asymptomatic left hand also and that this was associated with C6 and C8 root lesions.

*Case 4. Cervical root lesion.* Mrs. F. N. was a 48-year-old housewife with a long and complicated history of

pain in her neck and lower back, who had undergone five operations without obtaining any symptomatic



*Figure 4* — Electrophysiological findings in muscles of the left arm in Case 4 (second EMG examination). At top (section a) are potentials evoked in hypothenar muscles by maximal stimulation of ulnar nerve at wrist (W) and at elbow (E).

Section (b) shows maximum responses of thenar muscles following maximal stimulation of the median nerve at the wrist (W) and elbow (E). In this and section (a) the smallest intervals on the time calibrations represent 1 ms.

Section (c) shows absence of spontaneous activity at rest in left abductor pollicis brevis.

Section (d) shows incomplete interference pattern in same muscle during attempted maximal effort (note the falsely 'myopathic' look of many of the potentials).

relief. The salient features of her illness were as follows; —

*November 1970.* Hemilaminectomy of L5 vertebra.

*May 1971.* Myelogram revealed central disc protrusions at C5-6 and C6-7.

*July 1971.* Pain in neck more severe with radiation into left arm; also numbness of all (?) fingers.

*December 1971.* Cloward operation with fusion of C4, C5 and C6 vertebrae. Patient subsequently developed osteomyelitis of her cervical spine.

*December 1972.* Patient still experiencing severe neck pain with radiation into the left shoulder and elbow, aggravated by coughing and sneezing. Circumduction and abduction of left arm weak; triceps jerk reduced. Laminectomies of C4 and C5 vertebrae were performed. Post-operatively the pain in the neck, left shoulder and arm continued; the left thumb was noted to be numb and neither the biceps nor the radial jerks could be elicited.

*May 1973.* Pain was present as before and sensory examination revealed that numbness was now present in the thumb, index and middle fingers of the left hand. The previous laminectomy was extended and the C5, C6 and C7 roots on the left were 'decompressed'. On the day following operation the left arm was noted to be very weak with no finger movement present and only very weak movements of the wrist and elbow.

*August 1973.* All movements of the left shoulder, elbow and wrist were still very weak and no contraction could be detected in intrinsic muscles of the hand. The left thumb, index and middle fingers were still numb. An electromyographic examination was performed, the results of which are summarized below and in Tables 1-3.

*Results (left arm):* No responses could be detected in thenar muscles following electrical stimulation of the median nerve at the wrist. On stimulation of the ulnar nerve at the wrist, a small response was evoked in the hypothenar muscles, corresponding to about 25 motor units (Table 1). Maximum impulse conduction velocities were normal in motor fibers of the ulnar nerve in the cubital tunnel and forearm (46 and 50 m/s respectively). Sensory nerve function was normal in digital branches of the radial, median and ulnar nerves (Tables 2, 3). Examination with a coaxial electrode disclosed reduced interference patterns in the

deltoid, trapezius and biceps brachii muscles with excessive proportions of prolonged polyphasic potentials. In the abductor pollicis brevis and abductor digiti minimi muscles sparse fibrillations and fasciculations were recorded but there was no voluntary activity in either muscle.

*February 1974.* Further operation on lumbar spine (laminectomy only?). Post-operative both legs were weak; the right leg was numb and the left extremely painful.

*April 1974.* Movements of the left shoulder and elbow were still very weak and hardly any voluntary movement could be detected in the wrist and fingers. Severe pain was experienced in the whole of the left arm; the thumb, index and middle fingers were still numb. The skin of the left hand was shiny and cyanosed. There was little, if any, wasting of small muscles of the hand.

A further electromyographic examination was conducted, the results of which are summarized below and in Tables 1-3 and Fig. 4.

*Results (left arm):* A small response could now be recorded from the thenar muscle following stimulation of the median nerve at the wrist (Fig. 4); about 73 motor units were involved. The hypothenar potential evoked by ulnar nerve stimulation was considerably larger than in August 1973; it corresponded to about 203 motor units. Maximal impulse conduction velocities were normal in motor fibers of the median and ulnar nerves in the forearm (51 and 50 m/s respectively). Sensory nerve function was mostly normal in digital branches of the median, ulnar and radial nerves although some of the impulse conduction velocities appeared to have dropped (Table 3). Examination with a coaxial electrode yielded evidence of chronic denervation in the biceps brachii and extensor digitorum muscles. In the abductor pollicis brevis no spontaneous activity could be detected; upon volition, an incomplete interference pattern was produced which was made up of small brief potentials (Fig. 4). In the abductor digiti minimi the interference pattern was also incomplete but the component potentials were mostly large and polyphasic.

In this patient it was evident that the cervical operation in May 1973 had resulted in dysfunction of motor and sensory fibers in the C4 to T1 roots on the left side. It was not possible to deduce the nature of this disorder but both traction or ischaemia were possibilities. Whatever its nature, these extensive lesions resulted in predominantly neurapraxic disorders. Thus, in spite of normal sensory nerve function peripherally, three digits remained numb, suggesting the presence of a proximally-situated block of impulse conduction. Similarly, on the motor side, voluntary activity was absent in hypothenar muscles at the first EMG examination even though a small number of units could be excited by nerve stimulation. In spite of the severe functional denervation of the thenar muscles, only a small amount of fibrillation activity was detected at the first EMG examination and none at the second.

The finding of greatest interest, however, was the dramatic return of function in the thenar and hypothenar muscles in the 34 weeks separating the two EMG examinations. The normal maximal impulse conduction velocities (see above) and the relatively compact configurations of the evoked potentials (Fig. 4) made it improbable that recovery of function had been associated with remyelination or regeneration of axons (see Discussion).

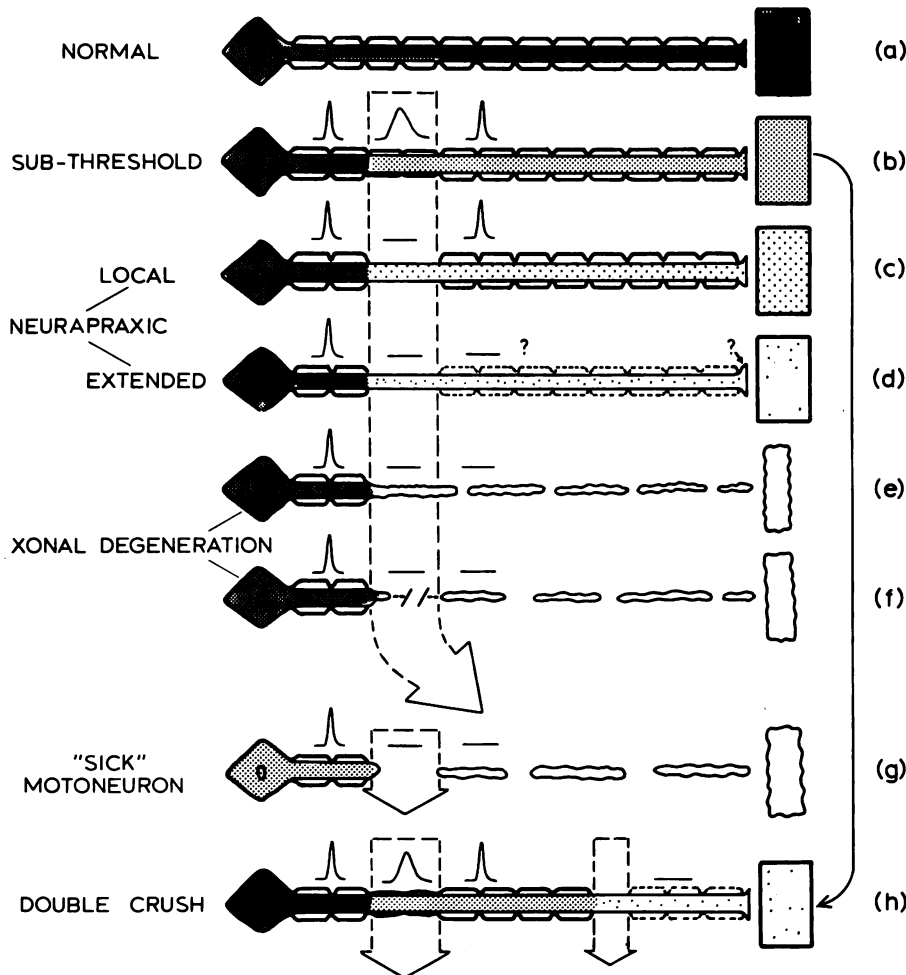
## DISCUSSION

The value of the motor unit counting method in revealing loss of functional innervation is that it is both sensitive and quantitative and that it does not depend on the cooperation of the patient. In many of our patients it would not have been possible to detect denervation, even of 50-70% severity, without use of this method. The four patients described are representative of more than a hundred who have been studied in this way, as well as with conventional electromyographic techniques, and in whom it has been necessary to make the diagnosis of a predominantly neurapraxic lesion. Case 1 provides an excellent exam-

ple of such a lesion for in this patient it was possible, by stimulating distally, to show that a substantial proportion of the axons remained in continuity beyond the region of electrical inexcitability and that the

motor end-plates were still functional (as in Fig. 5c). In Case 2 it was also possible to show, by distal stimulation, that the axons to pronator quadratus were still intact and a similar observation has recently

been made by one of us (A. R. M. U.) on a second patient with an anterior interosseous nerve syndrome. In some of our patients, for example Case 3, the presence of a neurapraxic lesion had to be inferred since it was not technically feasible to stimulate the nerve distal to the site of injury.



**Figure 5** — Possible types of neuropathic disorder. In (a) a normal motoneuron is shown with a myelinated axon; its impulses result in excitation of the muscle fiber at the neuromuscular junction and it supplies the fiber with trophic material conveyed by axoplasmic transport (AT). (b) to (f) show functional deficits resulting from increasingly severe compressive lesions (at arrow). In (b) there is local slowing of impulses and a slight reduction in AT. In (c) impulse transmission is abolished at the site of compression but the reduced AT is still sufficient to prevent denervation phenomena in muscle. In (d) the distal region of axon and/or neuromuscular junction are inexcitable but AT remains adequate for muscle. In (e) the compression has reduced AT to a level insufficient to maintain the distal axon, neuromuscular junction and muscle fiber; axonal (Wallerian) degeneration and muscle fiber atrophy with denervation features ensue. In (f) the mechanical injury is sufficient to interrupt the axon and so produce axonal degeneration and muscle fiber atrophy. In (g) a 'sick' motoneuron (e.g. in uraemia, diabetes, etc.) is barely able to manufacture sufficient trophic material; minimal compression of the nerve (e.g. in carpal tunnel) reduces AT still further, causing axonal degeneration and muscle fiber atrophy. In (h) crushes at 2 sites combine to reduce AT to levels inadequate for the preservation of axonal excitability, and/or neuromuscular transmission. In this figure, as in Case 2, muscle fiber viability is maintained; ultimately this will be prejudiced if AT declines further (see Upton and McComas, 1973).

At present it is not entirely clear why axons should become inexcitable at the site of compression. One possibility is that segmental demyelination occurs; in a recent study of single axons Rasminsky and Sears (1972) have shown that impulse propagation failed where demyelination had been induced by diphtheria toxin. However, it is evident that compression may also produce effects by less obvious means, as the experiments of Denny-Brown and Brenner (1944) have demonstrated. These authors compressed the sciatic nerves of cats and showed that, immediately after the compression at a time when impulse propagation was abolished, no changes could be observed in the inexcitable axons using light microscopy. After 24-48 hours had elapsed swelling and vacuolation of the axis cylinders were visible, and were followed by retraction of myelin at the nodes of Ranvier. In a proportion of axons segmental demyelination eventually took place and in some axons this extended peripherally, well beyond the site of compression. It is not known in our subjects whether the axonal inexcitability reflected alterations in cable properties caused by demyelination (see Rasminsky and Sears, 1972) or whether changes in the axis cylinder and axolemma were responsible.

The fourth patient, who was recovering from cervical root lesions, represents an interesting and apparently unrecognized extension of the classical neurapraxic disorder. In this and other patients with cervical root syndromes, motor unit counting often reveals a marked loss of functioning motor units without other evidence of denervation. In our patient it was necessary to postulate that many of the axons must have been present but not non-functional



in view of the rapid recovery which took place during the period of observation. The measurements of impulse conduction and the non-dispersed form of the evoked muscle potentials suggested that resumption of function had not been associated with remyelination or regeneration of axons. In these experiments the stimuli were applied beyond the lesion; therefore either the distal regions of axons were electrically inexcitable or else neuromuscular transmission had been impaired. So far there is no satisfactory means of distinguishing between these two possibilities in intact man. The only additional observation which may be of relevance was that in our patient normal sensory nerve responses were recorded from the branches of the median and ulnar nerves to the ring and little fingers. It is known that these digits are supplied by the C8 root and it is probable that the same root supplies the greater part of the median-innervated thenar musculature (McComas and Upton, unpublished observation). If the cervical root injury in Case 4 was distal to the dorsal root ganglia, the sensory and motor fibers would have been affected in a similar fashion. Under these circumstances the motor axons should have been excitable also; the attendant conclusion would be that the defect must have been limited to the synaptic region. Such a defect would be compatible with current concepts of neurotrophic phenomena since Miledi and Slater (1970) have recently shown that the functional and morphological integrity of the motor axon terminal is dependent on continued axoplasmic flow from the motoneuron. This flow could well be interrupted by compression of the axon at some intermediate point.

However, the main concern of the present study has been the contribution of the neurapraxic lesion towards an understanding of the trophic influence normally exerted by the motoneuron on the muscle fiber. To this extent it is immaterial whether the inexcitable region of nerve corresponds precisely to the site of compression (Fig. 5c),

whether it extends distally towards the muscle (Fig. 5d), or whether there is an associated failure of neuromuscular transmission. Each of these situations could have accounted for the observed inability of muscle fibres to respond to nerve stimulation with an evoked action potential. Yet in spite of their absence of impulse activity, the muscle fibers did not show other evidence of denervation; thus fibrillation potentials were absent and there were no signs of collateral reinnervation. Further, in Cases 1, 3 and 4 muscle atrophy was slight or absent whereas in Case 2 the completely paralysed pronator quadratus muscle was distinctly enlarged. This enlargement was presumably an example of the muscular hypertrophy, or pseudohypertrophy, which may sometimes complicate a neuropathic lesion (Lapresle, Fardeau and Said, 1973). In this last patient it was of interest that the two muscles examined which displayed fibrillation activity, the flexor digitorum profundus and the flexor pollicis longus, were definitely atrophied.

In all of our patients it was evident that some mechanism other than impulses had been responsible for suppressing features of denervation, the only alternative being a chemically-mediated one. If our interpretation of the findings in Case 4 is correct it would appear that the trophic influence of the motoneuron soma on the muscle may be preserved at a time when that to the distal region of the axon and motor end-plate may be inadequate. An explanation for this difference might lie in the selective vulnerabilities of target-specific neurotubules within the axon to compression (or ischaemia) or in different safety-margins of target structures.

The significance of the neurapraxic lesion for an understanding of trophic phenomena has already been pointed out. Denny-Brown and Brenner (1944) were also aware of this and stated (p. 22) . . . "The lesion, therefore, demonstrates that anatomic continuity of nerve, not receipt of impulses, prevents atrophy and fibrillation of muscle."

They, in turn, gave credit to Erb (1876) who showed that in some patients with paralysis caused by pressure the excitability of the nerve was normal below the level of the lesion, as was the response of the muscle to indirect stimulation.

In conclusion, it is worth remarking that a disorder of axoplasmic flow must underlie many neurologic disorders. In the peripheral nervous system it affords a convenient explanation for two further observations. One of these is the well-known susceptibility of patients with metabolic disorders (diabetes, uraemia, etc.) to nerve entrapment syndromes. It is reasonable to postulate that in such patients motoneurons are dysfunctional ('sick') and synthesize reduced amounts of trophic material. Under such circumstances minor degrees of compression will cut the trophic flow to levels inadequate to prevent denervation phenomena from occurring in the muscle; the axon may also degenerate for the same reason (Fig. 5g). In the 'double crush' situation (Upton and McComas, 1973) axoplasmic flow is impaired at two points in the axon, causing a net deficiency of trophic material for the muscle fiber and distal axon (Fig. 5h).

#### ACKNOWLEDGEMENTS

We are indebted to the Medical Research Council of Canada for financial assistance through its grant to the Developmental Neurobiology Research Group. For secretarial and technical assistance we wish to thank Irene Csatori, Klaus Fabich and Judy Leon (paid by the Muscular Dystrophy Association of Canada).

## REFERENCES

- DENNY-BROWN, D. and BRENNER, C. (1944). Paralysis of nerve induced by direct pressure and by tourniquet. *Archives of Neurology and Psychiatry*, 51, 1-26.
- ERB, W. H. (1896). Diseases of the peripheral cerebrospinal nerves. In VON ZIEMSEN, H. W., *Cyclopaedia of the Practice of Medicine*. Vol. 11 New York: William Wood. Cited by DENNY-BROWN and BRENNER, C. in *Archives of Neurology and Psychiatry*, 51, 1-26 (1944).
- DRACHMAN, D. B. (1974), editor, *Trophic Functions of the Neuron (Symposium)*. *Annals of the New York Academy of Sciences*, 228, 1-423.
- GUTH, L. (1968). Trophic influences of nerve on muscle. *Physiological Reviews*, 48, 645-687.
- GUTMANN, E., SCHIAFFINO, S. and HANZLIKOVÁ, V. (1971). Mechanism of compensatory hypertrophy in skeletal muscle of the rat. *Experimental Neurology*, 31, 451-464.
- LAPRESLE, J., FARDEAU, M. and SAID, G. (1973). L'hypertrophie musculaire vraie secondaire à une atteinte nerveuse périphérique. Etude clinique et histologique d'une observation d'hypertrophie du mollet consécutive à une sciatique. *Revue neurologique*, 128, 153-160.
- McCOMAS, A. J., SICA, R. E. P. and UPTON, A. R. M. (1974). Multiple muscle analysis of motor units in muscular dystrophy. *Archives of Neurology*, 30, 249-251.
- McCOMAS, A. J., FAWCETT, P. R. W., CAMPBELL, M. J. and SICA, R. E. P. (1971). Electrophysiological estimation of the number of motor units within a human muscle. *Journal of Neurology, Neurosurgery and Psychiatry*, 34, 121-131.
- MILEDI, R. and SLATER, C. R. (1970). On the degeneration of rat neuromuscular junctions after nerve section. *Journal of Physiology*, 207, 507-528.
- RASMINSKY, M. and SEARS, T. A. (1972). Internodal conduction in undissected demyelinated nerve fibers. *Journal of Physiology*, 227, 323-350.
- SEDDON, H. J. (1943). Three types of nerve injury. *Brain*, 66, 237-288.
- SICA, R. E. P., McCOMAS, A. J., UPTON, A. R. M. and LONGMIRE, D. (1974). Motor unit estimations in small muscles of the hand. *Journal of Neurology, Neurosurgery and Psychiatry*, 37, 55-67.
- SUNDERLAND, S. (1951). A classification of peripheral nerve injuries producing loss of function. *Brain*, 74, 491-516.
- UPTON, A. R. M. and McCOMAS, A. J. (1973). The double crush hypothesis in nerve entrapment syndromes. *Lancet*, 2, 359-362.