

*Social Media Review***SGEM Hot Off the Press: Regional Nerve Blocks for Hip and Femoral Neck Fractures: A Systematic Review**

Sarah Lockett-Gatopoulos, MSc, MD\*; Brent Thoma, MD, MA†; Ken Milne, MD, MSc‡; Chris Bond, MD§

*As part of the Canadian Journal of Emergency Medicine's (CJEM) developing social media strategy,<sup>1</sup> we are collaborating with the Skeptics' Guide to Emergency Medicine (SGEM) to summarize and critically appraise the current emergency medicine literature using evidence-based medicine principles. For this new "Hot Off the Press" series, we will select original research manuscripts published in CJEM to be featured on the SGEM site and discussed by study authors and the online EM community of medical students, residents, and practicing physicians. A similar collaboration is underway between the SGEM and Academic Emergency Medicine. What follows is a summary of the selected article, the immediate post-publication synthesis from the SGEM podcast, commentary by the first author, and the subsequent discussion from the SGEM blog and other social media. Through this series, we hope to enhance the value, accessibility, and application of important, clinically-relevant EM research. In this, the first SGEM HOP hosted collaboratively with CJEM, a systematic review evaluating the efficacy and safety of regional blocks for analgesia in hip and femur fractures is discussed.<sup>2</sup>*

**BACKGROUND**

Hip and femur fractures are common in the emergency department (ED). Elderly patients with multiple comorbidities are prone to these types of fractures.<sup>3</sup> Inadequate treatment of pain, oligoanalgesia, is also common in the ED. Oligoanalgesia is of particular concern in elderly patients, as they are less likely than younger patients to receive adequate doses of oral and

parenteral analgesia; these patients are at increased risk of short- and long-term complications when pain is inadequately managed.<sup>4,5</sup>

The pain associated with hip and femur fractures is commonly treated with acetaminophen, non-steroidal anti-inflammatory drugs (NSAIDs), and opioid medications. These medications may be insufficient for pain control, and practitioners may fail to administer adequate analgesia due to a perceived risk of complications, including pharmaceutical interactions and delirium.<sup>5</sup> Regional anaesthetic blocks promise analgesia, decreased need for oral and parenteral medication, and a reduced risk of systemic side effects. The regional blocks commonly used for hip and femur fractures are the traditional femoral nerve block, the 3-in-1 nerve block, and the fascia iliaca compartment block.

**ARTICLE SUMMARY**

Ritcey and colleagues<sup>2</sup> systematic review of regional anaesthetic blocks for hip and femur fractures included nine randomised control trials. The authors searched EMBASE, MEDLINE, CINAHL, the Cochrane Central Register of Controlled Trials, and the reference sections of selected articles to find 401 relevant studies, 19 of which were ultimately selected for full-text review. No language restriction was used, and the authors used a translation service for articles that were published in languages other than English. Two authors reviewed each article and independently extracted data. The authors used the Cochrane Collaboration tool to assess risk of bias.

From the \*Division of Emergency Medicine, McMaster University, Hamilton, ON; †Emergency Medicine, University of Saskatchewan, Saskatoon, SK; ‡Division of Emergency Medicine, University of Western Ontario, London, ON; and the §Department of Emergency Medicine, University of Calgary, Calgary, AB.

**Correspondence to:** Sarah Lockett-Gatopoulos, McMaster University, Emergency Medicine, 237 Barton Street East, 2nd Floor McMaster Wing, Room 252, Hamilton, ON, Canada, L8L 2X2; Email: sarah.lockett-gatopoulos@medportal.ca

© Canadian Association of Emergency Physicians

CJEM 2016;18(4):296-300

DOI 10.1017/cem.2016.332

Studies included by Ritcey and colleagues<sup>2</sup> used a visual analogue pain scale to compare a single, pre-operative regional anaesthetic injection with typical analgesia (acetaminophen, NSAIDs, and/or opioid). Secondary outcomes included opioid use and complications. Nine studies met selection criteria on full-text review, comprising a total of 547 patients aged 16 and over with hip or femur fractures.

### QUALITY ASSESSMENT

We used the Best Evidence in Emergency Medicine (BEEEM)<sup>6</sup> tool as a reference in our critical appraisal of the study by Ritcey and colleagues.<sup>2</sup>

The use of regional nerve blocks for the treatment of pain associated with hip and femur fractures may reduce oligoanalgesia and improve clinical outcomes. This study<sup>2</sup> addressed a clinically-relevant, patient-centered measure (the visual analogue scale for measurement of pain) as the primary outcome. The authors' search strategy was detailed and exhaustive, and their inclusion of non-English language articles is laudable. Two independent authors screened the titles and abstracts for full-text review, and inter-rater reliability was moderate for the initial screening phase ( $\kappa = 0.60$ ) and substantial ( $\kappa = 0.79$ ) for full-text review.<sup>7</sup>

Unfortunately, the available RCTs were small in size, ranging from 33 to 154 patients. Statistical and methodological heterogeneity was substantial, and the studies could not be combined into a meta-analysis. Only one of the 9 studies had a low risk of bias. The other studies were at moderate to high risk of bias, largely due to a lack of double blinding.

Though the authors had planned to do an *a priori* subgroup analysis to determine whether the use of ultrasound improved the effectiveness of regional blocks, they were unable to do so because only one study included ultrasound-guided regional blocks. Evaluation of secondary outcomes was hampered by variability of reporting in the included studies, particularly related to the under-reporting of harms.

Finally, it is not clear from the original papers which regional blocks were used, how they were performed, who performed them, and whether practitioners received training prior to performing the blocks.

### KEY RESULTS

The evidence for regional anaesthetic blocks for hip and femur fractures, as reviewed by Ritcey and colleagues,<sup>2</sup> comes from a small number of heterogeneous studies with a moderate to high risk of bias, but seems to support these blocks as a safe and effective alternative to standard analgesia for these injuries. Ultimately, we need more high-quality studies that evaluate safety.

### AUTHOR COMMENTARY

The authors of the systematic review<sup>2</sup> concluded that femoral nerve blocks are at least as effective as, and probably superior to, standard pain management for hip and femur fractures, and may decrease the need for IV opioids in fragile elderly patients. Five studies showed a significant reduction in use of opioid medications. No study found any immediate, life-threatening complication from the regional nerve blocks used. The authors recommend the use of these blocks but underline the need for further high-quality RCTs (Figure 1).

### METHODOLOGY

The social media discussion started with the launch of the blog post and podcast (<http://thesgem.com/2015/11/sgem138-hip-to-be-blocked-regional-nerve-blocks-for-hip-and-femoral-neck-fractures/>) on November 29th, 2015, and continued for one week through December 6th, 2015. An invitation to comment on the article was included in the audio of the podcast, the text of the blog post, and on social media (Twitter and Facebook). The extent of the social media response was tracked by evaluating its Altmetric score. Social media responses written in the SGEM blog's comment

#### **Take-to-Work Points**

Femoral nerve blocks are probably safe and as effective as standard pain management for hip and femur fractures. Further research is needed to elucidate the role of these anaesthetic techniques in improving analgesia and clinical outcomes, and to describe the harms associated with these techniques.

**Figure 1.** Take-to-Work Points

section, the SGEM Facebook page, and on Twitter (directed at @thesgem, @socmobem, and @Dr.Ritcey or using the #SGEMHOP hashtag) were reviewed by the authorship team. Using a simple, consensus-based process, those comments felt to be high yield were identified and included in the summary of the social media responses.

## RESULTS OF THE SOCIAL MEDIA RESPONSE

There was substantial social media uptake of the first SGEM HOP (Figure 2) and the podcast was recommended by Chris Connolly on the 209th edition of the widely-read *Life in the Fast Lane Review*.<sup>8</sup> Altmetric scores track the disseminative impact of research articles online by tracking mentions on social media (e.g., Facebook, Twitter) and mentions on blogs, podcasts, and news outlets.<sup>9</sup> Largely due to discussion spurred by the SGEM podcast and blog post, the Altmetric score for the article reached 71, the highest score of all the articles that have been published in *CJEM* (Figure 3).

There was another systematic review on femoral nerve blocks in the same issue of *CJEM*, which reached similar but distinct conclusions.<sup>10</sup> In the discussion of the podcast, Dr. Eddy Lang noted that this article by Riddell and collaborators<sup>8</sup> had an Altmetric score of 19, compared with the Altmetric score of 71 by Ritcey and

- What's the evidence to support the use of a [regional block for hip fracture?](#) The SGEM H.O.P. takes us through this recent systematic review. [CC]

**Figure 2.** Screen capture showing uptake of the article on LIFTL

colleagues,<sup>2</sup> suggesting that the use of the podcast and social media had likely improved its dissemination. Given that an Altmetric score of 19 is much higher than the Altmetric scores of other articles in this issue, all of which are between 1 and 7, it is also likely that its broad dissemination was related to the topic of the two articles.

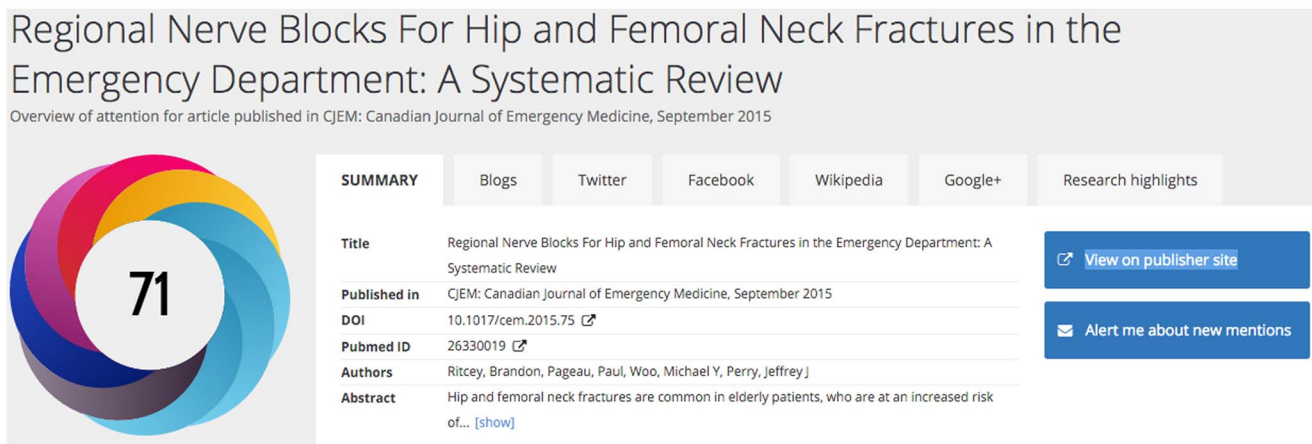
## ONLINE DISCUSSION SUMMARY

Feedback was solicited via a poll on the SGEM Twitter account, and it was found that the fascia iliaca block was the most popular method of providing regional analgesia for hip fractures (Figure 4).

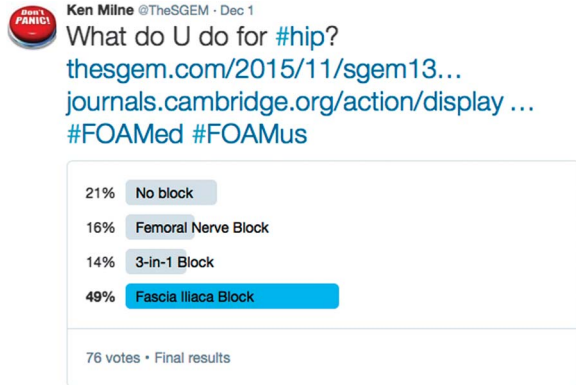
There were many insightful comments on social media networks, with the best appearing directly on the SGEM blog.<sup>11</sup>

The ACEP Geriatric Section noted that emergency orthogeriatrics is a fairly new concept with a rapidly-expanding body of research.<sup>12</sup> Regional nerve blocks in the setting of frail elderly hip fracture patients provide one alternative to the usual opioid analgesia, which can be particularly helpful in the near-hypotensive individual following a fall, while diagnostic evaluation is underway for other injuries/haemorrhage. One small study actually demonstrated feasibility in pre-hospital settings,<sup>13</sup> but regional anaesthesia is not commonly used in the contemporary ED.<sup>14,15</sup>

Dr. Chris Carpenter posed the question of how to learn to perform ultrasound-guided nerve blocks and asked about the learning curve for the procedure. Drs. Mike Mallin and Matt Dawson of *The Ultrasound Podcast* recommended three free online resources for learning to perform these ultrasound-guided blocks,



**Figure 3.** Screen capture of the Altmetrics data (available at: <http://www.altmetric.com/details/4466027> [accessed January 11, 2015]).



**Figure 4.** Tweet from Ken Milne (@theSGEM) containing a poll on viewers' choice of block for hip fractures.

including their own eBook,<sup>16</sup> their podcasts on the topic,<sup>17,18</sup> and a YouTube video by the New York School of Regional Anesthesia.<sup>19</sup> Dr. Greg Hall, a Canadian leader in Emergency Department Ultrasound, addressed other barriers to performing these nerve blocks, namely availability of the tools required for performing a block available in an easily accessible and timely fashion. He suggested that proper staff education, and organizing the department with carts and trays containing all the requisite materials for the procedure, would stimulate uptake.

## CONCLUSION

In summary, the first collaborative effort between *CJEM* and the SGEM was a resounding success. First, the article on ultrasound-guided femoral nerve blocks by Ritcey and colleagues is now *CJEM*'s most widely disseminated article via social media, with an Altmetric score of 71. Second, the episode engaged multiple parties in an educational critical appraisal of the article and discussion of the technique. Finally, social media interactions highlighted additional videos, articles, and resources helpful in the teaching and implementation of these blocks in the emergency department.

**Keywords:** regional anaesthesia, nerve blocks, analgesia, femur fracture

**Competing Interests:** None declared.

## REFERENCES

- Thoma B, Mohindra R, Artz JD, et al. *CJEM* and the changing landscape of medical education and knowledge translation. *CJEM* 2015;17(2):184-7, doi:[10.1017/cem.2015.16](https://doi.org/10.1017/cem.2015.16).
- Ritcey B, Pageau P, Woo MY, et al. Regional Nerve Blocks For Hip and Femoral Neck Fractures in the Emergency Department: A Systematic Review. *CJEM* 2016;18(1):37-47, doi:[10.1017/cem.2015.75](https://doi.org/10.1017/cem.2015.75).
- Volpato S, Guralnik JM. Hip fractures: comprehensive geriatric care and recovery. *Lancet* 2015;385(9978):1594-5, doi:[10.1016/S0140-6736\(14\)61592-0](https://doi.org/10.1016/S0140-6736(14)61592-0).
- Rainer SR. *Assessing Quality of Pain Management of Older Adults in Emergency Care*. Milwaukee: University of Wisconsin Milwaukee Theses and Dissertations; 2015.
- Morrison RS, Magaziner J, Gilbert M, et al. Relationship between pain and opioid analgesics on the development of delirium following hip fracture. *J Gerontol A Biol Sci Med Sci* 2003;58(1):76-81, doi:[10.1093/gerona/58.1.M76](https://doi.org/10.1093/gerona/58.1.M76).
- Worster A. *Best Evidence in Emergency Medicine*; 2015. Available at: <http://beemcme.com/> (accessed March 1, 2016).
- Cohen J. A coefficient of agreement for nominal scales. *Educ Psychol Meas* 1960;20(1):37-46.
- Connolly C. LITFL Review #209. *Life Fast Lane*; 2016. Available at: <http://lifeinthefastlane.com/litfl-review-209/> (accessed January 11, 2016).
- Trueger NS, Thoma B, Hsu CH, et al. The altmetric score: A new measure for article-level dissemination and impact. *Ann Emerg Med* 2015;66(5):549-53, doi:[10.1016/j.annemergmed.2015.04.022](https://doi.org/10.1016/j.annemergmed.2015.04.022).
- Riddell M, Ospina M, Holroyd-Leduc JM. Use of Femoral Nerve Blocks to Manage Hip Fracture Pain among Older Adults in the Emergency Department: A Systematic Review. *CJEM* 2015, epub 1-8, doi:[10.1017/cem.2015.94](https://doi.org/10.1017/cem.2015.94).
- Milne K. SGEM#138: Hip to be Blocked – Regional Nerve Blocks for Hip and Femoral Neck Fractures. *Skept Guid to Emerg Med*; 2015. Available at: <http://thesgem.com/2015/11/sgem138-hip-to-be-blocked-regional-nerve-blocks-for-hip-and-femoral-neck-fractures/> (accessed November 30, 2015).
- Carpenter CR, Stern ME. Emergency orthogeriatrics: concepts and therapeutic alternatives. *Emerg Med Clin North Am* 2010;28(4):927-49, doi:[10.1016/j.emc.2010.06.005](https://doi.org/10.1016/j.emc.2010.06.005).
- McRae PJ, Bendall JC, Madigan V, et al. Paramedic-performed fascia iliaca compartment block for femoral fractures: a controlled trial. *J Emerg Med* 2015;48(5):581-9, doi:[10.1016/j.jemermed.2014.12.016](https://doi.org/10.1016/j.jemermed.2014.12.016).
- Rashid A, Beswick E, Galitzine S, et al. Regional analgesia in the emergency department for hip fractures: survey of current UK practice and its impact on services in a teaching hospital. *Emerg Med J* 2014;31(11):909-13, doi:[10.1136/emj.2013.202794](https://doi.org/10.1136/emj.2013.202794).
- Haslam L, Lansdown A, Lee J, et al. Survey of Current Practices: Peripheral Nerve Block Utilization by ED Physicians for Treatment of Pain in the Hip Fracture Patient Population. *Can Geriatr J* 2013;16(1):16-21, doi:[10.5770/cgj.16.52](https://doi.org/10.5770/cgj.16.52).
- Dawson M, Mallin M. *Introduction to Ultrasound: Volume 1*. 1.34 ed.; 2013. Available at: <https://itunes.apple.com/ca/book/introduction-to-bedside-ultrasound/id554196012?mt=11>.

17. Dawson M, Mallin M. Episode 29 - Ultrasound guided nerve blocks Part 1. *Ultrasound Pod*; 2012. Available at: <http://www.ultrasoundpodcast.com/2012/06/episode-29-ultrasound-guided-nerve-blocks-part-1/> (accessed January 11, 2016).
18. Mallin M, Dawson M. Episode 24 - Femoral Nerve. *Ultrasound Pod*; 2012. Available at: <http://www.ultrasoundpodcast.com/2012/03/episode-24-femoral-nerve/> (accessed March 1, 2016).
19. NYSORA Admin. Ultrasound-guided femoral nerve block. *YouTube*; 2015. Available at: <https://www.youtube.com/watch?v=1mkHrVxdGNg> (accessed January 11, 2016).