

Brief Report

Cite this article: Grunenwald Gronier C, Benbrik N, and Baruteau A-E (2024) Complete atrioventricular block after atrial flow regulator implantation in a 5 kg infant. *Cardiology in the Young* 34: 2036–2038. doi: [10.1017/S1047951124025988](https://doi.org/10.1017/S1047951124025988)

Received: 2 November 2023
Revised: 4 March 2024
Accepted: 23 May 2024
First published online: 3 October 2024

Keywords:

atrial flow regulator; atrioventricular block; blood mixing; transposition of the great arteries

Corresponding author:

Alban-Elouen Baruteau;
Email: albanelouen.baruteau@chu-nantes.fr

¹Nantes Université, CHU Nantes, Department of Pediatric Cardiology and Pediatric Cardiac Surgery, FHU PreciCare, Nantes, France; ²Nantes Université, CHU Nantes, INSERM, CIC FEA 1413, Nantes, France; ³Nantes Université, CHU Nantes, CNRS, INSERM, l'institut du thorax, Nantes, France and ⁴Nantes Université, INRAE, UMR 1280, PHAN, Nantes, France

Abstract

The atrial flow regulator is a new self-expandable double-disc fenestrated device providing a calibrated inter-atrial communication. Paediatric reports are scarce. We herein describe a case of complete atrioventricular block complicating the exemption use of an atrial flow regulator in a 5-kg infant with transposition of the great arteries, ventricular septal defect, and right ventricular outflow tract obstruction.

Introduction

The Occlutech atrial flow regulator is a self-expandable double-disc nitinol device with a centrally located calibrated fenestration of 4 mm, 6 mm, 8 mm, and 10 mm diameters (only 8 mm and 10 mm devices are Communauté Européenne (CE)-marked). The diameters of the discs are 16 mm, 18 mm, 21 mm, and 23 mm, respectively. It has been approved in adult patients with symptomatic heart failure and increased left atrial pressure in the setting of reduced or preserved ejection fraction.¹ It has occasionally been used for left heart decompression under venoarterial extracorporeal membrane oxygenation support² or to create and secure a right-to-left shunt in patients with pulmonary arterial hypertension,³ CHD, or failing Fontan circulation.⁴ Paediatric reports are scarce, even more in children weighing less than 10 kg. We herein describe a case of transcatheter atrial flow regulator implantation in a 5 kg infant complicated by device-induced complete atrioventricular block.

Text

A 5 kg, 5-month-old infant with a prenatally diagnosed transposition of the great arteries with ventricular septal defect and right ventricular outflow tract obstruction was referred for cyanosis. He underwent balloon atrial septostomy at birth and a modified Blalock-Taussig-Thomas shunt at day-of-life 15. The patient was planned for a Nikaidoh procedure at a targeted 10 kg weight. He was readmitted in the interim for increased cyanosis, his oxygen saturation level having gradually dropped from 78 to 55% along with progressive atrial septal defect restriction and closure. Echocardiography showed systemic-to-pulmonary shunt patency but no residual inter-atrial shunt. After multidisciplinary team discussion, percutaneous implantation of an atrial flow regulator was offered to improve blood mixing at the atrial level as a bridge to further surgical biventricular repair. The French National Agency for Medicines and Health Products Safety authorised this exemption use procedure, and parents gave their consent. The procedure was performed in the catheterisation laboratory under general anaesthesia and biplane fluoroscopic guidance. On transesophageal echocardiography, atrial septal length and thickness measured 20 mm and 3.5 mm, respectively (Supplementary Figure S1). A transesophageal echocardiography-guided transeptal puncture was performed with a Brockenbrough needle in the middle of the inter-atrial septum, 12 mm away from the mitral valve, which was further dilated using a 12 × 20 mm Powerflex balloon catheter and a 14 × 20 mm Atlas Gold balloon catheter over a 0.035' guidewire parked in the left upper pulmonary vein (Figure 1). Transesophageal echocardiography demonstrated a central, unrestrictive, 5 mm atrial septal defect (Supplementary Figure S1), consistent with immediate oxygen saturation increase up to 78%. A 18/6 atrial flow regulator (i.e. 6-mm fenestration device) was successfully deployed through a 10-French Occlutech delivery sheath (Figure 1) with transesophageal echocardiography evidence of low velocity, continuous left-to-right inter-atrial shunt, without device-induced atrioventricular valve regurgitation and/or pulmonary veins or coronary sinus obstruction (Supplementary Figure S2). Ten minutes after device deployment, whilst still unreleased, complete atrioventricular block occurred with bradycardia and hemodynamic compromise (Figure 2). Immediate atrial flow regulator removal led to restoration of a normal 1:1 atrioventricular conduction. The patient was discharged home

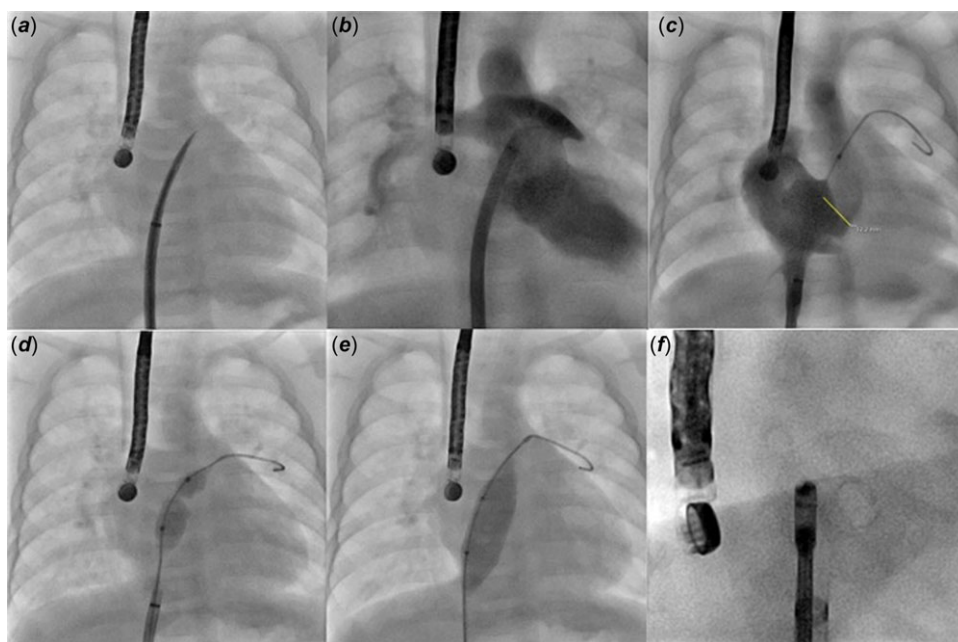


Figure 1. Echocardiography-guided transseptal puncture with a Brockenbrough needle (a). Contrast injections through the sheath confirm that the puncture site is located in the middle of the inter-atrial septum, 12 mm away from the mitral valve (b, c). Static balloon dilation using a 12x20 mm Powerflex balloon catheter (d) and a 14x20 mm Atlas Gold balloon catheter (e) on a 0.035' guidewire placed in the left upper pulmonary vein. After percutaneous implantation of a 18/6 atrial flow regulator, caudal right anterior oblique view (i.e., enface view) shows a well-opened 6 mm fenestration (f).

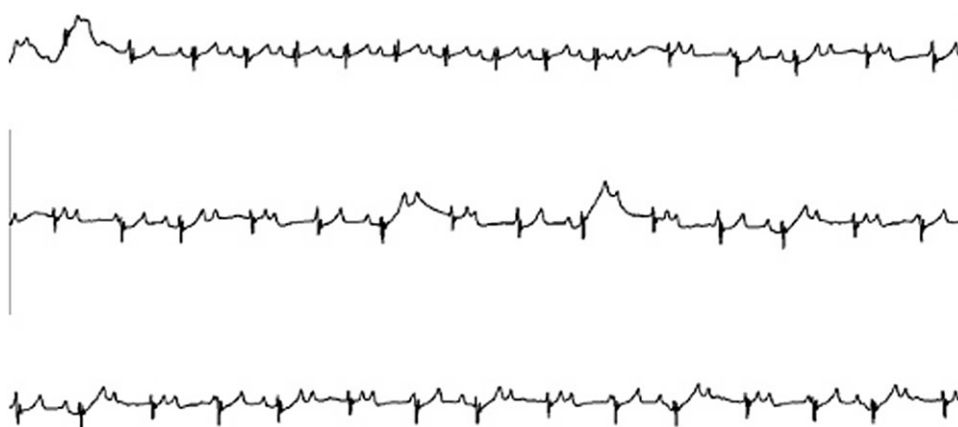


Figure 2. Electrocardiographic monitoring showing occurrence of complete atrioventricular dissociation.

the day after, with an uneventful follow-up and a long-standing unrestrictive atrial septal defect with appropriate blood mixing.

Discussion

This is the first report of atrial flow regulator-induced complete atrioventricular block. Data on the use of the atrial flow regulator in the paediatric population are limited, especially in < 10 kg children, where feasibility of atrial flow regulator implantation has been reported in a unique series of 4 patients (8.2 kg, 8.7 kg, 8.5 kg, and 5 kg, respectively), with procedural success, low morbidity, and long-lasting fenestration patency.² In this previous report, implantation of a 21/8 atrial flow regulator was successfully performed in an infant weighing 5 kg as did our patient; he was however twice older (10-month-old) with a longer inter-atrial septum due to an enlarged, loaded left atrium associated with left atrioventricular valve atresia and a restrictive atrial septal defect.

By analogy with percutaneous atrial septal defect closure, the atrioventricular node in the triangle of Koch may be at risk of device-related injury, especially after large device placement on the

inter-atrial septum. There is, however, growing evidence regarding feasibility and safety of transcatheter closure of large secundum atrial septal defects in symptomatic children weighing less than 10 kg. Atrioventricular block occurrence has been rarely observed as an acute periprocedural complication after transcatheter atrial septal defect closure, with a reported incidence of 0.4% (5/1,326 children, 29 kg [3.6–92.0]) in the paediatric population.⁵ Device-related atrioventricular block incidence may be 6 to 11-fold higher in children with lower procedural weight.^{6,7} In a series of 40 symptomatic children < 20 kg (11 kg [3.8–19.0]) with median device/weight ratio ≥ 1.5 (1.7[1.5–2.3]), transcatheter atrial septal defect closure was achieved with a 97.5% success rate and 5% major complications rate, including one complete atrioventricular block (1/40: 2.5%) requiring surgical device retrieval.⁶ In another series of 45 children ≤ 10 kg (9.6 kg [5.7–10.0]) with mean device/weight ratio > 1.5 (1.9[1.0–2.92]), percutaneous atrial septal defect closure was successful in 95.6%, providing two transient atrioventricular blocks (2/45: 4.4%) that resolved after steroids treatment.⁷ Of note, Narin et al. reported a 100% success rate with no device-induced atrioventricular block in 44 symptomatic children

< 10 kg (9 kg [8.12–9.50]) and large atrial septal defects inter-atrial septum/device length: 2.5[2.1–3.1]), although one device had to be surgically retrieved because it compressed the aorta.⁸

In our case, inter-atrial septum dilation before atrial flow regulator implantation precluded further inter-atrial septum stenting as a bailout procedure. Inter-atrial septum stenting is highly efficient at creating an unrestrictive inter-atrial shunt, but procedural morbidity and mortality are both significant, especially in low-body-weight infants.⁹ More experience is needed to assess whether atrial flow regulator implantation could become a safe and effective alternative in this complex paediatric population. In our patient, the significant improvement in oxygen saturation achieved by transcatheter inter-atrial septum dilation proved appropriate inter-atrial blood mixing. Static balloon dilation alone has been shown to be effective at creating a suitable, long-standing atrial septal defect anyway, reaching a good simplicity/efficiency ratio.

Conclusion

Atrial flow regulator implantation is technically feasible in as low as 5 kg infants, but careful cardiac rhythm monitoring is key during early follow-up, as device-related atrioventricular block may occur. Guidance on atrial flow regulator size selection in children is not currently available, but careful assessment on a case-by-case basis is key, taking into account the inter-atrial septum/device length ratio.

Supplementary material. The supplementary material for this article can be found at <https://doi.org/10.1017/S1047951124025988>.

Acknowledgements. We gratefully acknowledge GCS HUGO, AVIESAN, and FHU PRECICARE.

Financial support. A.-E.B is supported by the French Government as part of the “Investments of the future” programme managed by the National Research Agency (grant reference ANR-16-IDEX-0007); FHU PRECICARE.

Competing interests. A.-E.B is consultant and proctor for Occlutech.

Ethical standards. The authors assert that all procedures contributing to this work comply with the Helsinki Declaration of 1975, as revised in 2008.

References

1. Paitazoglou C, Özdemir R, Pfister R *et al.* The AFR-PRELIEVE trial: a prospective, non-randomized, pilot study to assess the atrial flow regulator (AFR) in heart failure patients with preserved or reduced ejection fraction. *EuroIntervention* 2019; 15 (5): 403–410.
2. Bautista-Rodriguez C, Hascoët S, Fraisse A. Feasibility, safety, and efficacy of atrial flow regulator in children under 10 kg. *Catheter Cardiovasc Interv* 2023. DOI: [10.1002/ccd.30536](https://doi.org/10.1002/ccd.30536). Online ahead of print. PMID: 36617379.
3. Butera G, Piccinelli E, Kolesnik A *et al.* Implantation of atrial flow regulator devices in patients with congenital heart disease and children with severe pulmonary hypertension or cardiomyopathy—an international multicenter case series. *Front Cardiovasc Med* 2024; 10: 1332395. DOI: [10.3389/fcvm.2023.1332395](https://doi.org/10.3389/fcvm.2023.1332395).
4. Jalal Z, Hascoët S, Gronier C *et al.* Long-term outcomes after percutaneous closure of ostium secundum atrial septal defect in the young: a nationwide cohort study. *JACC Cardiovasc Interv* 2018; 11: 795–804.
5. Houeijeh A, Hascoët S, Bouvaist H *et al.* Transcatheter closure of large atrial septal defects (ASDs) in symptomatic children with device/weight ratio ≥ 1.5 . *Int J Cardiol* 2018; 267: 84–87.
6. Sharma B, Pinto R, Dalvi B. Transcatheter closure of atrial septal defect in symptomatic children weighing ≤ 10 kg: addressing unanswered issues from a decade of experience. *Ann Pediatr Cardiol* 2020; 13: 4–10.
7. Narin N, Baspinar O, Pamukcu O *et al.* Percutaneous ASD closure of children weighing less than 10 kg. *Acta Cardiol* 2020; 75: 631–636.
8. Mainzer G, Goreczny S, Morgan GJ *et al.* Stenting of the inter-atrial septum in infants and small children: indications, techniques and outcomes. *Catheter Cardiovasc Interv* 2018; 91: 1294–1300.
9. Baruteau AE, Barnetche T, Morin L *et al.* Percutaneous balloon atrial septostomy on top of venoarterial extracorporeal membrane oxygenation results in safe and effective left heart decompression. *Eur Heart J Acute Cardiovasc Care* 2018; 7: 70–79.