



Vildan Atasayan , Yunus Emre Sarı and Taliha Öner 

Department of Pediatric Cardiology, University of Health Sciences, Ümraniye Training and Research Hospital, İstanbul, Turkey

Brief Report

Cite this article: Atasayan V, Sarı YE, and Öner T (2023) Left atrial appendage aneurysm in newborns: a report of two cases. *Cardiology in the Young* 33: 1477–1478. doi: [10.1017/S1047951123000069](https://doi.org/10.1017/S1047951123000069)

Received: 30 November 2022

Accepted: 2 January 2023

First published online: 17 January 2023

Keywords:

Infant; left atrial appendage aneurysm; cardiac surgery

Author for correspondence:

Vildan Atasayan, Department of Pediatric Cardiology, University of Health Sciences, Ümraniye Training and Research Hospital, Elmalikent district, Adem Yavuz Street, 34764 Ümraniye/İstanbul/Turkey.
Tel: +902166321818 int:4782.
E-mail: vatasayan@gmail.com

Abstract

Left atrial appendage aneurysm is an extremely rare cardiac anomaly with serious complications. It is rarely diagnosed in childhood. Herein, we reported two newborns diagnosed with left atrial appendage aneurysm.

Congenital left atrial appendage aneurysm is an extremely rare cardiac disease that can cause fatal complications.^{1,2} Since the left atrial appendage aneurysm is mostly diagnosed in adulthood, there are few cases reported in childhood.³ We reported two cases of left atrial appendage aneurysm diagnosed in the neonatal period.

Case reports

Case 1: Nineteen-day-old female newborn weighing 2700 g was referred to our centre with the suspicion of a left atrial aneurysm. The patient who did not have regular prenatal follow-ups had a 33-gestational week birth history due to hydrops fetalis. The aetiology of hydrops fetalis was probably thought to be an intrauterine maternal infection. The newborn also had a syndromic facial appearance. The intubated patient was admitted to the cardiovascular surgery ICU. She had high C-reactive protein, thrombocytopenia and anaemia. Blood and urine cultures were taken, and broad-spectrum antibiotics were applied. Transthoracic echocardiography showed a large saccular structure attached left atrium, and low-velocity blood flow between the left atrium and the aneurysm was detected with the color Doppler. Also, there was moderate to severe mitral valve regurgitation due to left atrial dilatation. Electrocardiography was in normal sinus rhythm. CT angiography was performed for the presence of a possible thrombus and differential diagnosis. CT angiography showed that the left atrium and left atrial appendage were aneurysmatic and secondary to this, and other cardiac chambers were displaced and pressed towards the right anterolateral (Fig 1). There was also left atrial appendage compression at the level of the left main bronchus hilus. Thereupon, the patient was decided to be operated after her antibiotic therapy was completed. At 1 month of age, cardiopulmonary bypass was performed after arterial bicaval selective venous cannulation from the aorta with median sternotomy. Intraoperatively, it was evident that the aneurysmatic left atrial appendage compressed the left ventricle. The aneurysmatic left atrial appendage was clamped and resected at its base. She was taken to the ICU with high-dose inotropic support. The patient who was hypotensive and had no urine output died after the surgery.

Case 2: A 5-day-old term baby, weighing 3005 g, was referred to our tertiary centre due to a murmur. Electrocardiography showed sinus rhythm. Transthoracic echocardiography revealed a large left atrial appendage aneurysm measuring 3.2 × 2.8 cm communicating with the left atrium. CT angiography was performed for differential diagnosis, and further investigation. CT angiography also revealed a large left atrial appendage aneurysm that did not cause any compression on the adjacent cardiac structures and bronchial system and did not have thrombi (Fig 2). The patient, who has no complaints and no arrhythmia detected in the Holter electrocardiography, is followed up at regular intervals without any medication. The patient is 4 months old now and has no increase and/or thrombus in the aneurysm.

Discussion

Although left atrial appendage aneurysm has life-threatening complications, its diagnosis is mostly incidental. It is extremely rare diagnosed in childhood.^{1–3} In this article, we have reported two cases diagnosed in the neonatal period.

Left atrial appendage aneurysm can be congenital or acquired. The cause of congenital left atrial appendage aneurysm is dysplasia and attenuation of the pectinate muscles. Acquired left atrial appendage aneurysm develops secondary to left atrial pressure increase due to mitral valve disease or left atrial wall weakening related to tuberculosis or syphilitic myocarditis.⁴ Symptoms associated with left atrial appendage aneurysm usually appear during the second to fourth

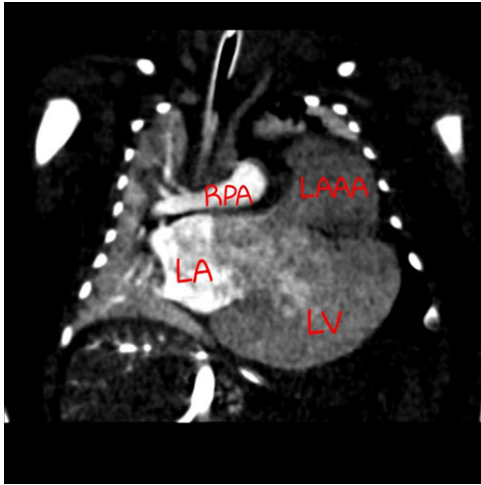


Figure 1. CT angiography image of LAAA for case 1. LA: left atrium; LV: left ventricle; RPA: Right pulmonary artery; LAAA: left atrial appendage aneurysm.

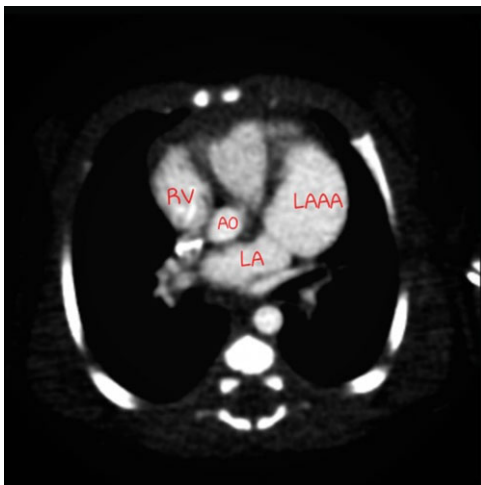


Figure 2. CT angiography image of LAAA for case 2. RV: left ventricle; AO: aort, LA: left atrium; LAAA: left atrial appendage aneurysm.

decades of life. The most common symptoms are palpitations and/or dyspnoea. Arrhythmia especially atrial arrhythmias, intracardiac thrombus, thromboembolic events, atrial fibrillation, and heart failure are serious complications of left atrial appendage aneurysm.⁵

Transthoracic echocardiography plays an important role in the diagnosis of left atrial appendage aneurysm. An aneurysm sac communicating with the left atrium cavity can be detected by transthoracic echocardiography, and the presence of a thrombus in the aneurysm can be seen. In addition, blood exchange between the aneurysm and left atrium can be demonstrated by colour Doppler echocardiography.⁶ MRI or CT can be used for differential diagnosis and evaluation of compression on adjacent structures. Congenital deficit of pericardium, solid or cystic paracardiac tumours, appendage juxtaposition, mediastinal mass, dilated coronary sinus, and left ventricle pseudoaneurysm are the differential diagnoses of left atrial appendage.⁵ We diagnosed left atrial

appendage aneurysm with transthoracic echocardiography in both of our two patients and confirmed the diagnosis with CT. There is no consensus on which size should be named as aneurysm, especially in children. Aryal et al suggested that, if the left atrial appendage has increased 1.5-fold compared to its normal size, it can be called an left atrial appendage aneurysm⁵.

The recommended treatment for left atrial appendage aneurysm is surgical resection, but there is no consensus on the timing of surgery. In our first patient, we preferred surgical resection by performing cardiopulmonary bypass because of compression findings on CT and clinical worsening. But we lost our patient because of the comorbidities. Since our second patient was asymptomatic and there were no signs of compression on CT, we decided to follow up closely. Some prefer conservative treatment, especially in small aneurysms without intracardiac thrombus. Plonska-Gosciniak et al reported a patient with left atrial appendage aneurysm accompanied by supraventricular arrhythmia with drug therapy at the 20-year follow-up.⁷ Similarly, Valentino et al reported a case who was followed up with drug management for 5 years and then underwent surgery.⁸ In addition, some authors recommend early surgery even if they are asymptomatic⁹.

There are few cases in the literature that newborns were diagnosed with left atrial appendage aneurysm in the first 1 month of life and undergone surgery. Therefore, we reported these two cases. The surgery time for left atrial appendage aneurysm varies according to the patient's symptoms and clinical experience, and there is no consensus on treatment and follow-up. We recommend CT or MRI for differential diagnosis and/or compression findings to patients diagnosed as left atrial appendage aneurysm with transthoracic echocardiography.

Financial support. This research received no specific grant from any funding agency, commercial, or not-for-profit sectors.

Conflicts of Interest. None.

References

1. Chowdhury UK, Seth S, Govindappa R, Jagia P, Malhotra P. Congenital left atrial appendage aneurysm: a case report and brief review of literature. *Heart Lung Circ* 2009; 18: 412–416.
2. Mathur A, Zehr KJ, Sinak LJ, Rea RF. Left atrial appendage aneurysm. *Ann Thorac Surg* 2005; 79: 1392–1393.
3. Zhang X, Li P, Cao Y, et al. Left atrial appendage aneurysm in pediatrics. *Echocardiography* 2020; 00: 1–5.
4. Tandon R, Arisha MJ, Nanda NC, et al. Incremental benefit of three-dimensional transthoracic echocardiography in the assessment of left atrial appendage aneurysm leading to severe extrinsic compression of a coronary artery. *Echocardiography* 2018; 35: 685–691.
5. Aryal MR, Hakim FA, Ghimire S, et al. Left atrial appendage aneurysm: a systematic review of 82 cases. *Echocardiography* 2014; 31: 1312–1318.
6. Tidake A, Gangurde P, Mahajan A. Congenital left atrial appendage aneurysm associated with a systemic embolism. *Cardiol Young* 2015; 25: 597–599.
7. Płonska-Gościniak E, Larysz B, Jurczyk K, et al. Five-chambered heart: a 20-year story of left atrial appendage aneurysm. *Eur Heart J* 2009; 30: 1014–1014.
8. Valentino MA, Al Danaf J, Morris R, et al. Giant left atrial appendage aneurysm: a case of mistaken identity. *J Cardiol Cases* 2017; 15: 129–131.
9. Tanoue Y, Kado H, Shiookawa Y, Sagawa K. Left atrial appendage aneurysm in a child. *Ann Thorac Surg* 2004; 77: 721–723.