

## *Corynebacterium pseudotuberculosis* infection in Israeli dairy cattle

I. YERUHAM<sup>1</sup>\*, D. ELAD<sup>2</sup>, S. FRIEDMAN<sup>3</sup> AND S. PERL<sup>2</sup>

<sup>1</sup> *Hachaklati* Gedera and the Koret School of Veterinary Medicine, The Hebrew University of Jerusalem, P.O. Box 12, Rehovot 76100, Israel

<sup>2</sup> The Kimron Veterinary Institute, Bet Dagan 50250, Israel and the Koret School of Veterinary Medicine, The Hebrew University of Jerusalem, P.O. Box 12, Rehovot 76100, Israel

<sup>3</sup> National Service for Udder Health Caesarea, and the Koret School of Veterinary Medicine, The Hebrew University of Jerusalem, P.O. Box 12, Rehovot 76100, Israel

(Accepted 28 March 2003)

### SUMMARY

Two forms of *Corynebacterium pseudotuberculosis* infection in Israeli dairy cattle herds during a survey period of 13 years (1989–2001) are described. The more common form, which was diagnosed in 45 herds, was characterized by ulcerative granulomatous lesions which occurred either sporadically – in 26 herds (with a morbidity rate of up to 5% – or in an epidemic course in 19 herds. Most (80.6%) of the affected animals were cows; the rest were first-calving cows (16.2%) and heifers (3.2%). The morbidity occurred mostly during the summer months. The ulcerative granulomatous lesions appeared in three clinical forms: cutaneous, mastitic and visceral. Mixed forms were also observed. The morbidity rate was 6.4% and the culling rate reached 16.3% of the affected animals. Most of the strains of *C. pseudotuberculosis* which were isolated from the abscesses in the cutaneous form of the disease and from milk samples failed to reduce nitrate. A decrease in milk production (6%) and an increase in bulk-milk somatic cell count were noted. Necrotic and ulcerative dermatitis on the heel of the foot occurred in an epidemic course in heifers in only two herds during the winter months, with morbidity rates of 7.5 and 76.2%, respectively. *C. pseudotuberculosis* isolates from skin lesions and from the soil did reduce nitrate. Clinical, epizootiological and microbiological aspects of the infection are described.

### INTRODUCTION

*Corynebacterium pseudotuberculosis* is a Gram-positive, pleomorphic, intracellular, nonmotile, facultative anaerobic rod that grows well on blood agar, forming small, whitish, opaque colonies [1]. *C. pseudotuberculosis* has three major components that have been implicated in the expression of its pathogenicity and virulence: the high lipid content in its cell wall; production of phospholipase D exotoxin and its intracellular ability to persist in macrophages [2–7].

The protective nature of the cell capsule enables the bacterium to persist in the environment for extended periods under favourable conditions: damp, shady areas and low temperatures [8–11].

Two biotypes of *C. pseudotuberculosis* have been reported: a nitrate-negative form, most frequently isolated from sheep and goats, and a nitrate-positive form that infects cattle and horses [12]. Other authors have reported that both types may be isolated from cattle [13–16].

The source of natural infection and the means of entry into the host are not well documented for cattle. The possible role of arthropod vectors in the

\* Author for correspondence: 4 Hagoren St., Gedera 70700, Israel.

transmission of the bacterium has been studied [17–21]. Several clinical forms of the disease caused by *C. pseudotuberculosis* have been described in cattle: pyogranulomatous reactions; abscess formation; ulcerative lymphangitis and mastitic and visceral forms [14, 16, 24–27]. Recently an additional form was described: necrotic and ulcerative dermatitis on the heel of the foot accompanied by oedematoes swelling and lameness [15]. The present paper describes the clinical and epidemiological aspects of *C. pseudotuberculosis* infection in Israeli dairy cattle and its economic importance.

## MATERIAL AND METHODS

### Animal and management

Field observations were carried out in 1989–2001 in 47 dairy cattle herds comprised 230–300 Israeli Holstein dairy cows. The herds consisted also female calves and heifers of various ages. In all the affected herds the cows were kept in a loose-housing system in large, completely covered open sheds. The lactating cows were divided into at least two groups: first-lactation cows, and the remainder. Dry cows and heifers were kept in separate sheds. All the clinical, reproduction, production and management data were recorded on computer by the herd manager and the attending veterinarian. All the herds were visited weekly. The economic losses were estimated from the decrease in milk production and milk quality, the culling rates and cost of drugs.

### Clinical, bacteriological and histological examinations

All the clinical cases were recorded. The location, size and appearance of any skin lesions were marked and recorded regularly. During the morbidity period, the milk from all the affected lactating cows was examined bacteriologically. Thereafter milk samples were examined monthly until negative bacteriological results were obtained for *C. pseudotuberculosis*. Milk samples were taken by standard aseptic techniques [22], refrigerated and processed on the next day. Once every month, milk from individual cows and the bulk tanks was sampled and analysed for somatic cell count by the central laboratory for Milk Recording of the Israeli dairy cattle breeders' association. A composite milk sample from all the lactating was obtained at least annually and submitted for bacteriological examination. Confirmation of the clinical diagnosis of *C. pseudotuberculosis* infection was obtained by

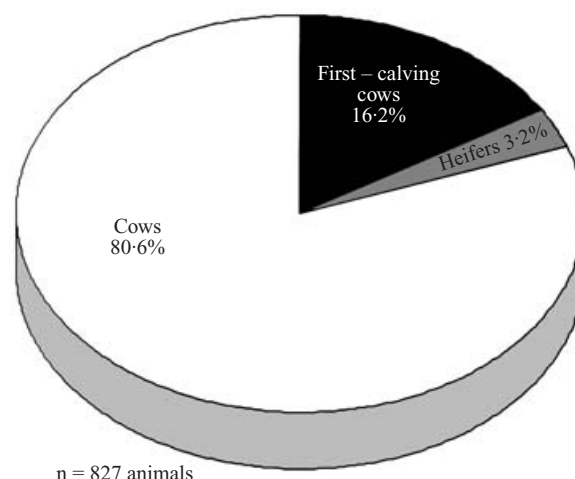


Fig. 1. Distribution of age groups in herds affected with *C. pseudotuberculosis* infection.

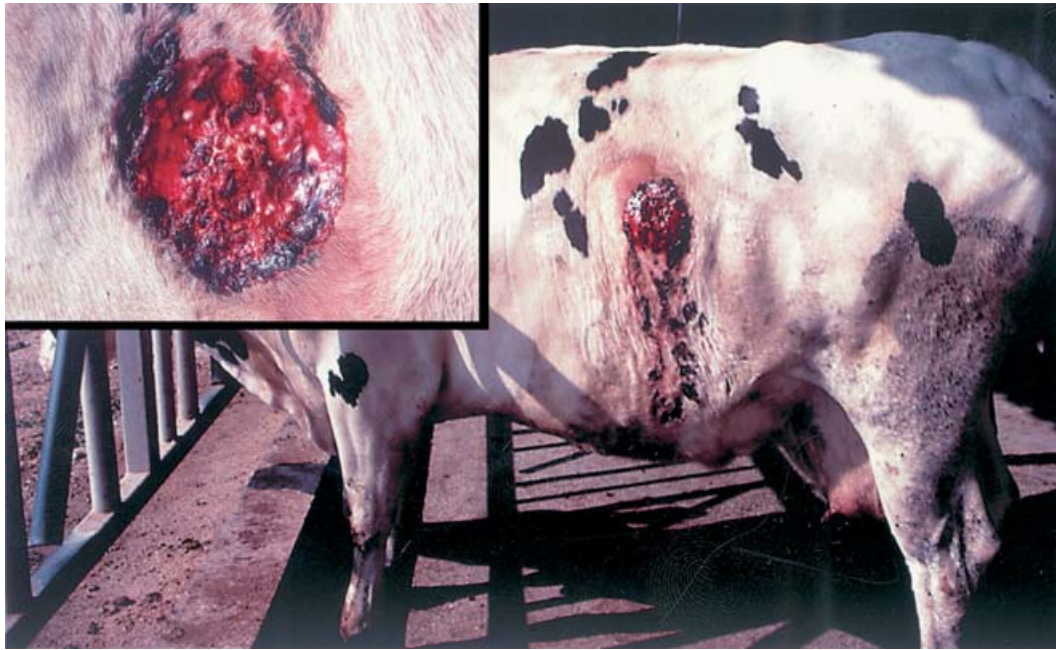the culture of abscess contents and skin lesions. Aspirates of the abscess contents were collected using a large, 16-gauge needle; fluids were thick, creamy-white and viscous. Skin swabs were taken into transport medium (Amies modified without charcoal), using standard aseptic techniques, placed on ice and processed within 4 h. Samples were inoculated on to 5% sheep-blood agar, nutrient agar and MacConkey's agar (Difco Laboratories) and incubated at 37 °C. The colonies suspected to be *C. pseudotuberculosis* were finally identified by the API-Coryne system. Susceptibility tests of the isolated bacteria were also made by a standard method [23]. Skin biopsies for histopathological examination were taken with a skin punch from the lesions of 85 affected cows. They were fixed in 10% natural buffered formalin embedded in paraffin wax, sectioned at 5–6 µm and stained with haematoxylin and eosin.

## RESULTS

### Clinical, epidemiological, bacteriological and histological studies

#### Ulcerative granulomatous lesions

During the study period of 13 years ulcerative granulomatous lesions were diagnosed in 45 herds. The morbidity rate was 6.4% – 27 heifers aged 14–18 months, 134 first-calving cows and 666 cows (Fig. 1), and the culling rate reached 16.3% (135 animals). The clinical signs included skin lesions in the form of single or multiple abscesses on the head, flanks, shoulders, neck and hind legs above the stifle joint.



**Fig. 2.** Cow with bleeding ulcerative-granulomatous lesions caused by *C. pseudotuberculosis* infection.

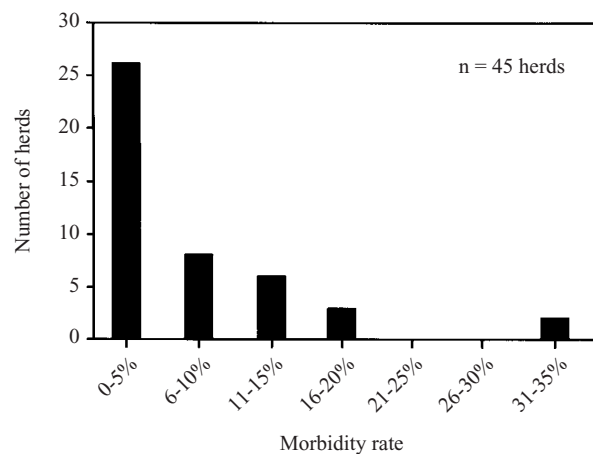
The cutaneous form of the disease appeared in 91.3% of the affected cattle, the cutaneous and mastitic form in 7.1%, and the cutaneous and visceral forms in only 1.6% of 125 affected cows which underwent post-mortem examination. No cases of mastitis without cutaneous lesions were observed. The regional lymph nodes were involved in all cases, but generalized lymphadenitis and lymphangitis were not observed.

Typically, the abscesses reached a diameter of 15–20 cm; they were associated with a firm, fibrous tissue capsule in the subcutaneous tissues and were fastened to the skin. Palpation of the abscess revealed it to be doughy, and it was oedematous and painful. The ruptured abscesses had raised necrotic margins and secreted either serosanguinous exudates or a blood-stained yellowish pus (Fig. 2).

The abscesses ulcerated and developed draining tracts. In most cases, the lesions did not appear to cause systemic illness in the affected cows. In 42 (5.3%) cows the cutaneous form of the disease recurred 4 weeks to 4 months after initial recovery.

The disease occurred sporadically in 26 dairy herds, with morbidity rates of up to 5%, and in the epidemic form in 19 herds, in which the morbidity rate ranged from 5 to 35% (Fig. 3). In 38 of the herds (84.4%) the infection occurred during the dry season, from March to October.

In 38 of the herds the infection lasted up to 5 months (Fig. 4) and the skin lesions on individual



**Fig. 3.** Distribution of morbidity rates in affected herds with *C. pseudotuberculosis* infection.

cows an average of 23.4 days, after either local or parenteral treatment.

A definitive diagnosis was based on bacteriological and histological examination. After 24 h incubation, non-haemolytic, pinpoint-sized colonies appeared on the blood and nutrient agar. After a further 24 h, the colonies reached a diameter of about 1 mm, appeared opalescent white and were surrounded by a narrow zone of haemolysis. There was no growth on McConkey's agar plates. The colonies consisted of Gram-positive coryneform micro-organisms, identified as *C. pseudotuberculosis* with the API-Coryne system (API-bioMérieux). *C. pseudotuberculosis* was

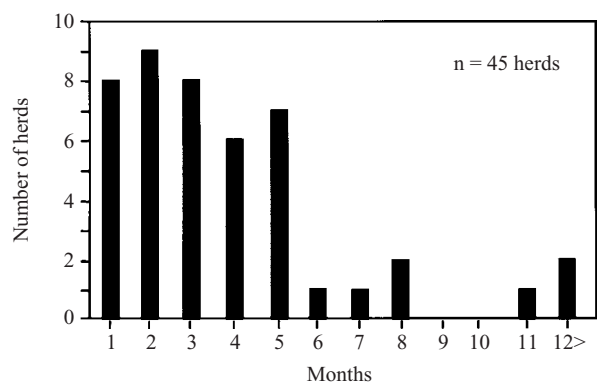


Fig. 4. Distribution of the duration of morbidity months in affected herds with *C. pseudotuberculosis* infection.

isolated from 92 of 112 abscesses. Mixed cultures of *C. pseudotuberculosis* with *Staphylococcus aureus* species were obtained from 5 samples. *C. pseudotuberculosis* was isolated from milk samples from 59 of the cows (7.1%) in 17 herds. All the strains isolated from milk samples were found not to be nitrate reducers. The bacterium was excreted in the milk of six cows during a period of 11 months.

Histological examination of the lesions biopsies showed a chronic granulomatous reaction. There were numerous pyaemic foci surrounded by epithelioid and multinuclear giant cells in the subcutis (Fig. 5).

Despite the susceptibility of *C. pseudotuberculosis* to nearly all common antibacterial drugs, including penicillin and amoxycillin, the efficacy of the systemic antibiotic treatment of the affected cows was unsatisfactory. There was no significant difference between the recovery periods observed in the animals treated systemically or locally.

Isolation of the affected animals, local treatment with antiseptics and fly control appeared to prevent the disease from spreading to other animals in the herds.

The economic losses in one of the affected herds, were attributed to high culling rates (16.3%), to a decrease in average monthly milk production, by 6% in comparison with a previous year (Fig. 6), and to an increase in the bulk-milk somatic cell count from a herd mean of  $280 \times 10^3/\text{ml}$  to a mean of  $485 \times 10^3/\text{ml}$  during the morbidity period (Fig. 7).

#### *Necrotic and ulcerative dermatitis on the heel of the foot*

The skin lesions occurred in two groups of heifers aged 12–18 months in two dairy cattle herds. The morbidity rates of the heifers reached 7.5 and 76.2%,

respectively. There was a marked seasonal pattern of occurrence of the disease – during the winter months (February–March). The most common signs were oedematous swelling on the distal part of the legs and necrotic-ulcerative dermatitis on the heel of the foot (Fig. 8). Affected animals were often noticeably depressed because of the lameness and pain. Rectal temperature was in the normal range. *C. pseudotuberculosis* was the dominant component of the bacterial cultures from the skin lesions and the environment.

Histological examination showed areas of ulcerated squamous epithelium and formation of microabscesses in the dermis; these contained many inflammatory cells, mainly neutrophils and macrophages (Fig. 9).

A foot bath with 5% formalin solution used for 30 min, twice a week for 2 weeks resulted in a marked improvement of the condition after the second treatment, and offered a good cure for the disease. The cutaneous lesions resolved within 4–8 weeks.

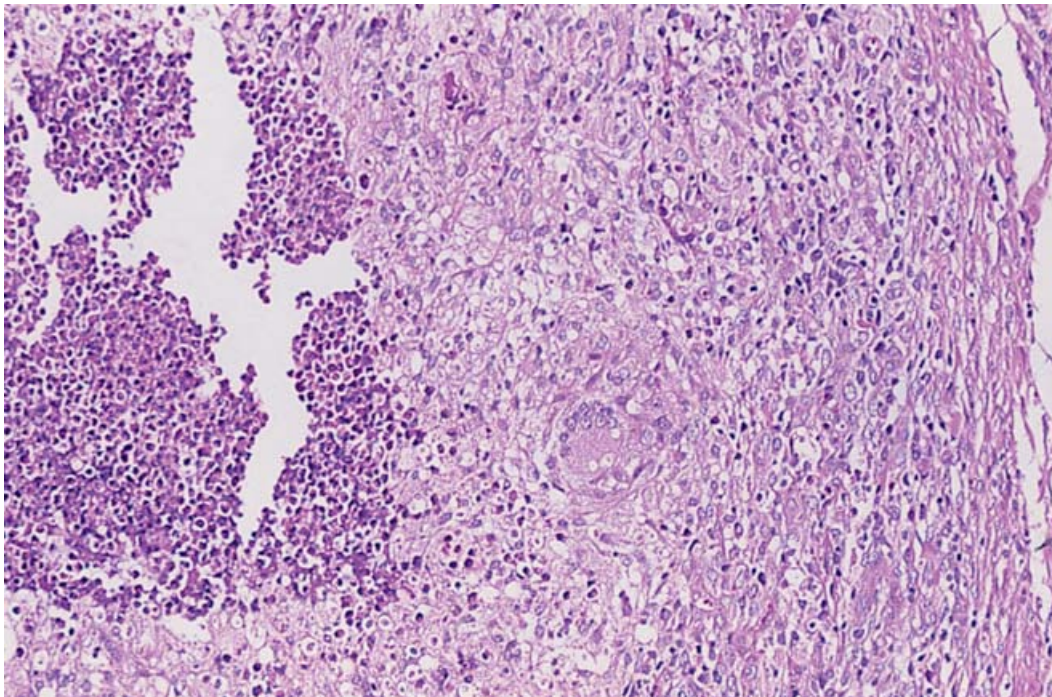
Haemograms of the animals affected by the both forms of the disease revealed mild to severe leucocytosis with a left shift.

## DISCUSSION

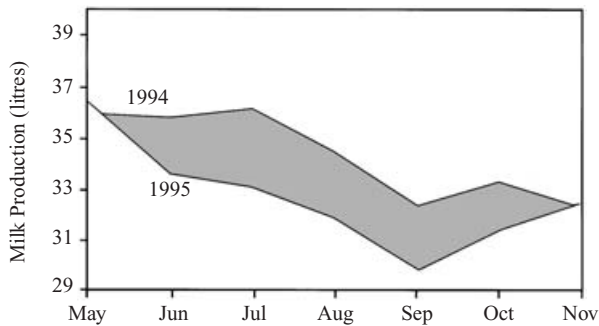
*Corynebacterium pseudotuberculosis* infection is one of the most commonly diagnosed infectious diseases in cattle in Israel [14–16, 26]. During the survey period (1989–2001) ulcerative granulomatous lesions occurred sporadically in 26 herds and in an epidemic course in 19 herds. The disease occurred in three clinical forms: cutaneous, mastitic, and visceral. Mixed forms have also been described [14, 19, 26]. Necrotic and ulcerative dermatitis on the heel of the foot appeared also in an epidemic form in heifers in two herds.

The inflammatory process and local oedematous swelling around the lesions are attributed to the organism's putative virulence factors, but mainly to the direct effect of phospholipase D exotoxin in the surrounding blood vessels and lymphatics [7, 21]. Besides the local pathological effects of phospholipase D exotoxin, it also has a general toxæmic influence on internal organs [21]. In addition, the cell wall lipids of *C. pseudotuberculosis* have a potent necrotic effect on the surrounding tissues [21].

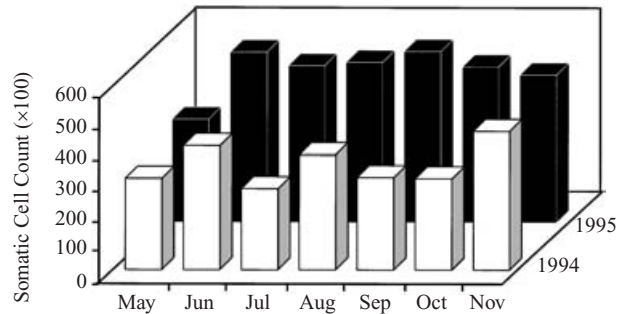
*Corynebacterium pseudotuberculosis* infection probably spread among Israeli dairy cattle herds through the introduction of infected animals into an infection-free herd or even through the movement of an



**Fig. 5.** Ulcerative-granulomatous reaction with pyaemic foci surrounded by epithelioid and giant cells. Haematoxylin and eosin  $\times 200$ .



**Fig. 6.** Decrease in milk production in a herd infected by *C. pseudotuberculosis*.



**Fig. 7.** Increase in somatic cell count in a herd infected by *C. pseudotuberculosis*.

infected animal from one barn to another. The infection may spread within the herd either by direct contact between infected and uninfected animals, or by mechanical transmission by houseflies [19–20] or other diptera [21].

The potential for environmental contamination from a single ruptured abscess in the ulcerative-granulomatous form is very high, and the ability of the organism to survive in soil and on fomites ensures its continuing presence [9]. Infected milk dripping from a dairy cow may also contaminate the environment and infect other cows in the herd.

As a result of the primary infection in the animal, the bacteria may become disseminated [28]. It seems

that geographic and climatic conditions, seasonally fluctuating incidence, contaminated environment, the age and possibly also the breed of the affected animals, are potential risk factors for the epidemic occurrence of the disease, and they may also have an important role in the epizootiology of the disease. Presumptive diagnosis of *C. pseudotuberculosis* infection can be made by consideration of necrotic and ulcerative dermatitis on the heel of the foot, and of the environmental conditions. A definitive diagnosis of *C. pseudotuberculosis* infection is based on isolation of the organism from swab samples taken from affected skin and soil, and on histological examination of skin biopsies.

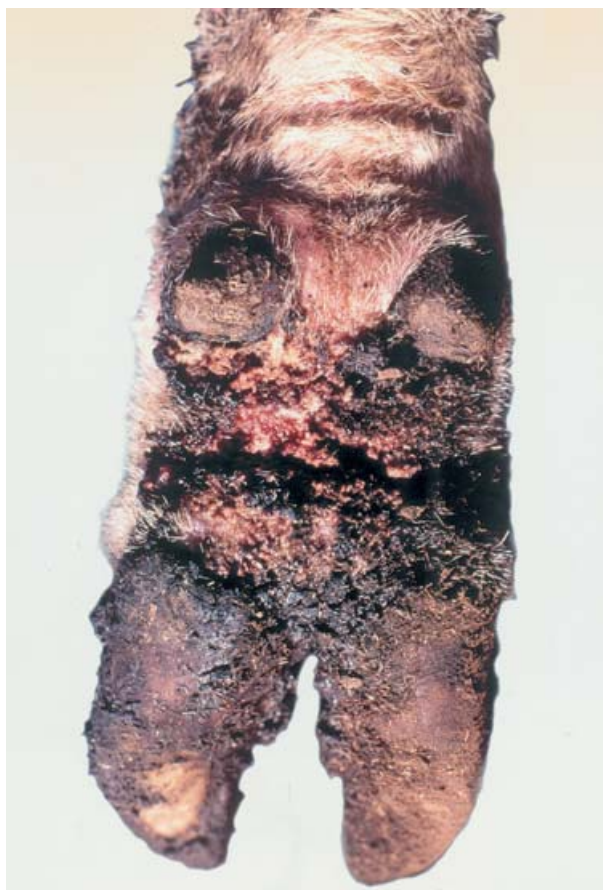

Fig. 8. Necrotic-ulcerative dermatitis on the heel of the foot.

The development of a pyogranuloma is associated with limited bacterial dissemination, as described by Pepin et al. [29]. These results illustrate the dual role of granulomas in chronic bacterial diseases [30]. On the one hand, an infectious granuloma can be considered as a mechanism of defence, that limits bacterial dissemination to critical sites and stimulates the development of an effective immune reaction [31, 32]. On the other hand, it can be considered as the expression of an immunopathological process, because of the tissue damage and excessive fibrosis associated with the persistence of viable bacteria [33]. All the strains of *C. pseudotuberculosis* which were isolated from the abscesses in the cutaneous form of the disease and from all milk samples (except in one herd [16]) failed to reduce nitrate [14, 26], and this failure is characteristic of the ovine and caprine strains [12, 13]. The isolation of *C. pseudotuberculosis* from the skin lesions on the heel of the foot as well as from the soil suggests that *C. pseudotuberculosis* was a secondary invader. The isolated *C. pseudotuberculosis* reduced nitrate and based on clinical

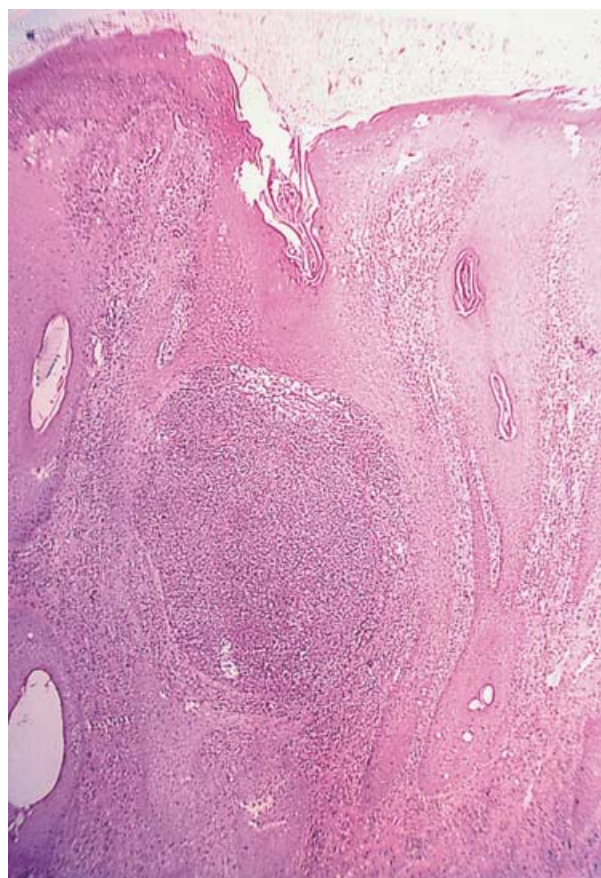


Fig. 9. Necrosis of the squamous epithelium with micro-abscesses in the dermis. Haematoxylin and eosin  $\times 100$ .

observations it caused necrotic and ulcerative dermatitis at the sites of abrasions in the skin, but it did not produce abscesses [13] or ulcerative granulomatous lesions [14, 26].

Parenteral treatment with penicillin and amoxycillin failed to cure infected cattle of ulcerative granulomatous lesions, and the local treatment of all forms of skin lesions was the most effective. Similar findings have been reported by Ashfaq and Campbell [34] and Kariuki and Poulton [25]. There are several possible reasons for the inefficacy of the parenteral antibiotic therapy: first, the antibiotics may be unable to penetrate the thick fibrous capsule of the abscess and, second, *C. pseudotuberculosis* is an intracellular parasite, residing in the phagocytic cells, therefore it may not come into contact with substantial quantities of the antibiotic.

The fact that *C. pseudotuberculosis* infection occurred only once in each affected herd during the survey suggests that the herds may have acquired some immunity to the disease [14]. In only one herd did the disease occur twice, and the two events were

seven years apart. It may be explained by the high annual culling rate (30%) and by the existence of two biotypes of the organism, between which there is no cross-immunity [16]. Jolly [35] stated that immunity to reinfection can be acquired but, nevertheless, cutaneous lesions reappeared in 24 cows several weeks to several months after they had recovered.

The cutaneous form of the disease occurred at various sites, usually subcutaneous or within lymph nodes; the visceral and mastitic forms are apparently less common but more severe forms of the diseases [14]. It seems that the severe cases tend to be mixed forms, either cutaneous and visceral, or cutaneous and mastitic [14, 19]. In the present study, the visceral form of the disease was detected only when severely affected animals were slaughtered, therefore it is likely that more animals than was apparent were affected by this form.

Nairn and Robertson [36] recorded that the formation of pulmonary abscesses followed the haematogenous or lymphogenous spread, rather than the aerogenous spread of *C. pseudotuberculosis*. Infected milk can also spread the disease, and it forms a public health hazard when unpasteurised milk or milk products are consumed by human beings [37]. Human infection may also occur as a result of continued close contact with infected animals. The distribution patterns of ulcerative granulomatous lesions and of necrotic-ulcerative dermatitis suggest a relationship between the age of the animals and the type and prevalence of the disease; young cattle appeared to be less susceptible to the ulcerative granulomatous form than older cows (80.6%), while only heifers were found to be affected by necrotic ulcerative dermatitis. Doherr et al. [38] reported that young animals were seemingly more frequently affected than older ones.

The fact that outbreaks and sporadic morbidity occurred in 84.4% of the affected herds during the summer (March to October) may be related to the large populations of houseflies and other diptera, which play an important role in harbouring and disseminating *C. pseudotuberculosis* in dairy herds in Israel [20, 21].

An additional predisposing factor is wet skin [36], which results from the practice in Israel of showering lactating cattle in the collecting yard 3–5 times daily during the summer months, to cool them and to reduce their heat stress. The excessive wetting of the coat may have damaged the epidermis and sebaceous film [39]. Moreover, under these conditions, the disease may have been transmitted directly.

The heel of the foot seems to be the primary site of infection in the necrotic-ulcerative dermatitis form of the infection, and none of the heifers developed abscesses at secondary locations. In contrast to the ulcerative granulomatous form, which occurred mainly during the summer–autumn months [14], this form appeared during the winter months, therefore, arthropod vectors were apparently not involved in the transmission of this form of the infection. Instead, the infection was apparently caused by the contaminated and poor environmental conditions in the yard that were apparently attributed to heavy precipitation during the winter months.

The animal yard apparently served as an environmental reservoir, but the infective route of *C. pseudotuberculosis* is still speculative. The entry route for this soil-borne organism is thought to be through abrasions or wounds in the skin, or mucous membranes, or via ingestion or inhalation [10, 34], and probably also through intact skin [10, 13, 36].

The potential of *C. pseudotuberculosis* to survive outside the host, and the close contact between animals when they gather near the water trough and in the waiting yard, are considered to be the most important factors in the spread of this organism. *C. pseudotuberculosis* has been shown to be able to survive for prolonged periods in contaminated environments under favourable conditions [9–11, 40, 41]. Such environmental conditions prevailed during the winter months in the heifers' yard, indicating that optimal survival conditions for the bacterium are necessary for a high rate of infection to occur in cattle.

The eradication of endemic *C. pseudotuberculosis* infection is apparently nearly impossible, because of the longevity of the organism on infected premises [9, 10], despite its sensitivity to ultraviolet light and, therefore, to direct sunlight.

Although lymphadenitis has been diagnosed serologically in sheep [42], to the best of the authors' knowledge no such method has been developed for cattle. Serodiagnosis, however, would be very useful in certifying herds as free from *C. pseudotuberculosis*. Epidemic *C. pseudotuberculosis* infection in cattle is a severe condition, with significant economic consequences, as was pointed out in previous reports [14, 19, 27]. All forms of the infection severely affect the animals' health and production, and a better understanding of the epizootiology and the clinical aspects of the disease should be applied to preventive management schemes.

## REFERENCES

1. Coyle MB, Lipsky BA. Coryneform bacteria in infectious diseases: clinical and laboratory aspects. *Clin Microbiol Rev* 1990; **3**: 227–246.
2. Hard GC. Adoptive transfer of immunity in experimental *Corynebacterium ovis* infection. *J Comp Pathol* 1972; **80**: 329–334.
3. Hard GC. Comparative toxic effect of the surface lipid of *Corynebacterium ovis* on peritoneal macrophages. *Infect Immun* 1975; **12**: 1439–1449.
4. Carne HR, Onon EO. Action of *Corynebacterium ovis* exotoxin on endothelial cells of blood vessels. *Nature* 1978; **271**: 246–248.
5. Barksdale L, Linder R, Skulea IT, Pollice M. Phospholipase D activity of *Corynebacterium pseudotuberculosis* (*Corynebacterium ovis* and *Corynebacterium ulcerans*), a distinctive marker within the genus *Corynebacterium*. *J Clin Microbiol* 1981; **13**: 335–343.
6. Yozwiak MS, Songer JG. Effect of *Corynebacterium pseudotuberculosis* phospholipase D on viability and chemotactic responses of ovine neutrophils. *Am J Vet Res* 1993; **54**: 392–397.
7. Aleman MR, Spier SJ. *Corynebacterium pseudotuberculosis* infections. In: Smith PB, ed. *Large animal internal medicine*, 3rd ed. St. Louis: Mosby Co. 2002: 1076–1084.
8. Knight HD. *Corynebacterium pseudotuberculosis* infection in the horse. Ph.D. thesis, University of California, Davis, 1969.
9. Augustine JL, Renshaw HW. Survival of *Corynebacterium pseudotuberculosis* in axenic purulent exudates on common barnyard fomites. *Am J Vet Res* 1986; **47**: 713–715.
10. Brown CC, Olander HJ. Caseous lymphadenitis of goats and sheep: a review. *Vet Bull* 1987; **57**: 1–12.
11. Lloyd S. Caseous lymphadenitis in sheep and goats. In *Practice* 1994; **16**: 24–29.
12. Biberstein EL, Knight HD, Jang S. Two biotypes of *Corynebacterium pseudotuberculosis*. *Vet Rec* 1971; **25**: 691–692.
13. Barakat AA, Selim SA, Atef A, Saber MS, Nafie EK, El-Ebeedy AA. Two serotypes of *Corynebacterium pseudotuberculosis* isolated from different animal species. *Rev Sci Tech Off Int Epiz* 1984; **3**: 151–163.
14. Yeruham I, Elad D, Van-Ham M, Shpigel NY, Perl S. *Corynebacterium pseudotuberculosis* infection in Israeli cattle: clinical and epidemiological studies. *Vet Rec* 1997; **140**: 423–427.
15. Yeruham I, Perl S, Elad D, Ram A. An outbreak of necrotic and ulcerative dermatitis on the fetlock in heifers in a dairy herd infected with *Corynebacterium pseudotuberculosis*. *Vet Rec* 2002. In press.
16. Steinman A, Elad D, Shpigel NY. Ulcerative lymphangitis and coronet lesions in an Israeli dairy herd infected with *Corynebacterium pseudotuberculosis*. *Vet Rec* 1999; **145**: 604–606.
17. McGiure CD, Durant RC. The role of flies in the transmission of eye disease in Egypt. *Am J Trop Med Hyg* 1957; **6**: 569–575.
18. Addo PB. Role of the common housefly (*Musca domestica*) in the spread of ulcerative lymphangitis. *Vet Rec* 1983; **113**: 496–497.
19. Yeruham I, Braverman Y, Shpigel NY, Chizov-Ginzburg A, Saran A, Winkler M. Mastitis in dairy cattle caused by *Corynebacterium pseudotuberculosis* and the feasibility of transmission by houseflies. *Vet Quart* 1996; **18**: 87–89.
20. Braverman Y, Chizov-Ginzburg A, Saran A, Winkler M. The role of houseflies (*Musca domestica*) in harbouring *Corynebacterium pseudotuberculosis* in dairy herds in Israel. *Rev Sci Tech Off Int Epiz* 1999; **18**: 681–690.
21. Selim SA. Oedematous skin disease of buffalo in Egypt. *J Vet Med B* 2001; **48**: 241–258.
22. National Mastitis Council. *Microbiological procedures for use in the diagnosis of bovine mastitis*, 2nd edn. Ames: Carter Press, 1981.
23. National Committee for Clinical Laboratory Standards. *Performance standards for anti-microbial disk susceptibility tests*. Approved Standard M2-A5. Villanova, Pennsylvania: National Committee for Clinical Laboratory Standards, 1993: 268.
24. Purchase HD. An outbreak of ulcerative lymphangitis in cattle caused by *Corynebacterium ovis*. *J Comp Pathol* 1944; **54**: 238–244.
25. Kariuki DP, Poulton J. *Corynebacterium* infection of cattle in Kenya. *Trop Anim Hlth Prod* 1982; **14**: 33–36.
26. Shpigel NY, Elad D, Yeruham I, Winkler M, Saran A. An outbreak of *Corynebacterium pseudotuberculosis* infection in an Israeli dairy herd. *Vet Rec* 1993; **133**: 89–94.
27. Yeruham I, Friedman S, Elad D, Perl S. Association between milk production, somatic cell count and bacterial dermatoses in three dairy cattle herds. *Aust Vet J* 2000; **78**: 250–253.
28. Pepin M, Pardon P, Marly J, Lantier F. *Corynebacterium pseudotuberculosis* infection in adult ewes by inoculation in the external ear. *Am J Vet Res* 1988; **49**: 459–463.
29. Pepin M, Pardon P, Lantier F, Marly J, Levieux D, Lamand M. Experimental *Corynebacterium pseudotuberculosis* infection in lambs: kinetics of bacterial dissemination and inflammation. *Vet Microbiol* 1991; **26**: 381–392.
30. Williams GT, Williams WJ. Granulomatous inflammation: a review. *J Clin Pathol* 1983; **36**: 723–733.
31. Strauss R, Heymer B, Hof H. Effects of cyclosporin A on experimental infection with *Listeria monocytogenes*. *Immunology* 1985; **62**: 491–498.
32. Heymer B, Wirsing Von Konig CH, Finger H, Hof H, Emmerling P. Histomorphology of experimental listeriosis. *Infection* 1988; **16**(S2): S106–S111.
33. Pepin M, Fontaine JJ, Pardon P, Marly J, Parodi AL. Histopathology of the early phase during experimental *Corynebacterium pseudotuberculosis* infection in lambs. *Vet Microbiol* 1991; **29**: 123–134.



34. Ashfaq MK, Campbell SG. Experimentally induced caseous lymphadenitis in goats. *Am J Vet Res* 1980; **41**: 1789–1792.
35. Jolly RD. The pathogenesis of experimental *Corynebacterium ovis* infection in mice. *New Zealand Vet J* 1965; **13**: 141–147.
36. Nairn ME, Robertson JD. *Corynebacterium pseudotuberculosis* infection of sheep: role of skin lesions and dipping fluids. *Aust Vet J* 1974; **50**: 537–542.
37. Henderson A. Pseudotuberculosis adenitis caused by *Corynebacterium pseudotuberculosis*. *J Med Microbiol* 1979; **12**: 147–149.
38. Doherr MG, Carpenter TE, Hanson KMP, Wilson WD, Gardner IA. Risk factors associated with *Corynebacterium pseudotuberculosis* infection in Californian horses. *Prev Vet Med* 1998; **35**: 229–239.
39. Yeruham I, Elad D, Nyska A. A survey of dermatophilosis in Israeli dairy cattle. *Rev Elev Med Vet Pays Trop* 1995; **48**: 25–29.
40. Benham CL, Seaman A, Woodbine M. *Corynebacterium pseudotuberculosis* and its role in diseases of animals. *Vet Bull* 1962; **32**: 647–655.
41. Nairn ME, Roberson JP, Middleton HD, McQuade NC. The possibility of control of caseous lymphadenitis in goats by vaccination. *Proceeding of the 3rd International Conference on Goat Production and Diseases*. Tucson, Arizona USA, 1982, vol. 3, 455–457.
42. Schreuder BEC, Terlaak EA, Dercksen DP. Eradication of caseous lymphadenitis in sheep with the help of a newly developed ELISA technique. *Vet Rec* 1994; **135**: 174–176.