

# PROGRESS IN CLINICAL NEUROSCIENCES: Perioperative Ulnar Neuropathies: A Medicolegal Review

John D. Stewart, Stephen H. Shantz

**ABSTRACT: Background:** Perioperative ulnar neuropathies have long been attributed to inappropriate arm positioning and padding during operations and have resulted in many lawsuits. **Methods:** A recent Canadian lawsuit is described and the literature regarding perioperative ulnar and other focal neuropathies reviewed. **Results:** The evidence strongly suggests that ulnar nerve damage is usually sustained in the postoperative rather than the intraoperative period. There is no evidence that positioning or padding of the arm during the operation prevents perioperative ulnar neuropathies. **Conclusions:** There should generally be no basis for a claim against medical or nursing staff or hospitals when an ulnar neuropathy develops following anesthesia and surgery.

**RÉSUMÉ: Neuropathies cubitales périopératoires: revue médico-légale. Contexte:** Les neuropathies cubitales périopératoires ont longtemps été attribuées à un positionnement et à un matelassage inadéquats du bras pendant la chirurgie et ont donné lieu à de nombreuses poursuites. **Méthodes:** Nous décrivons une poursuite récente au Canada et nous présentons une revue de la littérature sur la neuropathie cubitale périopératoire et sur d'autres neuropathies focales. **Résultats:** Les données suggèrent fortement que le dommage du nerf cubital survient en postopératoire plutôt que pendant la chirurgie. Il n'y a pas d'observation suggérant que le positionnement ou le matelassage du bras pendant la chirurgie prévient les neuropathies cubitales périopératoires. **Conclusions:** Il ne devrait généralement pas exister de fondement à une réclamation contre le personnel médical ou infirmier ou l'hôpital quand une neuropathie cubitale survient après une anesthésie et une chirurgie.

Can. J. Neurol. Sci. 2003; 30: 15-19

Ulnar neuropathies at the elbow (UNEs) following surgical procedures under anesthesia have long been recognized. The traditional view is that these can be the result of poor positioning of the arm and inadequate protection of the ulnar nerve, resulting in external compression of the nerve. This belief has led to many lawsuits especially in the United States of America. The American Society of Anesthesiologists Closed Claims Study database shows that UNE has been the most frequent focal neuropathy cited in such claims, and constitutes over one-third of all claims involving nerve injury.<sup>1</sup> A recent lawsuit in Canada focussed on this issue (Sutherland, et al, v. Hunt, et al [2001], O.J. No. 3859). The purpose of this paper is to bring the decision of the court to the attention of physicians and lawyers, and to reappraise the medicolegal issues surrounding perioperative UNEs.

Three terms have been used for categorizing focal neuropathies occurring in association with surgery and anesthesia: intraoperative, postoperative, and perioperative (Figure 1). Intraoperative and postoperative imply that the damage to the nerve occurred during or after the operation, respectively. Perioperative is the preferred term, and the one

mainly used in this paper, because it does not specify at which time the neuropathy developed.

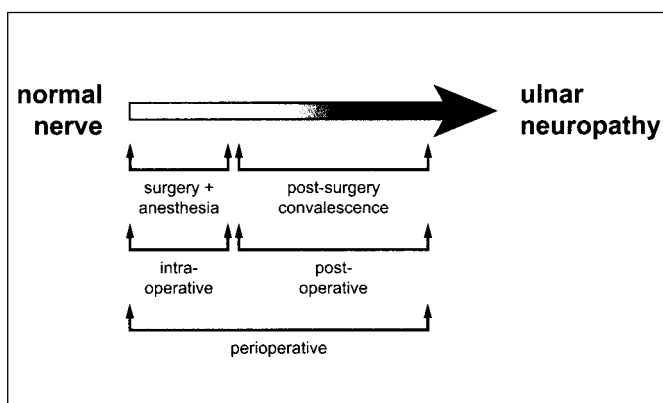
## CASE HISTORY

A 70-year-old man was diagnosed as having a rectal carcinoma and had an abdominoperineal resection under general anesthesia. The operation lasted approximately 3.5 hours. The patient's arms were placed on arm boards covered with 7.5 cm thick foam padding at both elbows. His postoperative course was uneventful and he left hospital 14 days after the surgery. At a follow-up visit with the surgeon on the 22nd postoperative day, no untoward symptoms were reported. However, five days later he visited his family physician with the complaint of numbness and tingling in the 4th and 5th digits of the left hand. Over the

From the Montreal Neurological Hospital and Institute, and McGill University, Montreal QC, and McCarthy Tetrault, London, ON Canada.

RECEIVED JUNE 27, 2002. ACCEPTED IN FINAL FORM SEPTEMBER 23, 2002.

Reprint requests to: John D. Stewart, Montreal Neurological Hospital, 3801 University Street, room 365, Montreal QC, H3A 2B4 Canada



**Figure 1:** Schematic to define the terms regarding the relationship of focal neuropathies and the surgical procedure.

next several days this evolved to include neuropathic pain in this hand, forearm pain, and weakness of the left forearm and hand. He was seen by a physiatrist and this examination plus nerve conduction and electromyographic studies confirmed the presence of a severe left UNE. The patient developed substantial impairment of activities of daily living including colostomy care because of this hand dysfunction. Severe pain necessitated major analgesic medication. He developed a left frozen shoulder which further added to his pain and disability. In spite of intensive physiotherapy, an ulnar nerve transposition and then later an internal ulnar nerve neurolysis, the severe motor and sensory nerve dysfunction persisted, as did the pain. The patient died two years later from metastatic cancer.

A suit was brought against the hospital, the surgeon and the anesthetist, claiming that the UNE was the result of improper intraoperative protection of the nerve. The plaintiffs said that the patient complained of numbness and tingling in his left 4th and 5th digits immediately upon awakening from the anesthetic and for the remainder of his 14 day hospitalization. They maintained that position in spite of no documented complaints referable to the left hand or arm in the hospital chart from the defendant physicians, the nursing staff or the patient's own family physician who saw him regularly during his hospital stay. The court was charged with determining whether the UNE occurred intraoperatively, and if so, whether it resulted either from improper positioning or inadequate padding of the left arm or elbow. Based on a careful analysis of the evidence including the hospital records, testimony of the defendant physicians and nursing staff, and on testimonial from a medical expert, the court rejected the widow's contention that her husband's UNE developed during his hospitalization and concluded that the injury occurred some time after his discharge. During the trial the following important questions regarding perioperative UNEs were raised and will be addressed in this paper.

1. What is the prevalence of perioperative UNE?
2. Do perioperative UNEs occur during the operation (intraoperative) or are they postoperative?
3. How effective are padding and positioning of the arms in preventing perioperative UNE? How much padding should be used?
4. Are there identifiable risk factors during or following surgery and anesthesia that contribute to perioperative UNE?
5. Can we presume negligence on the part of the anesthetist, surgeon

and/or hospital operating room staff if a patient develops a perioperative UNE?

## DISCUSSION

### Anatomy of the ulnar nerve

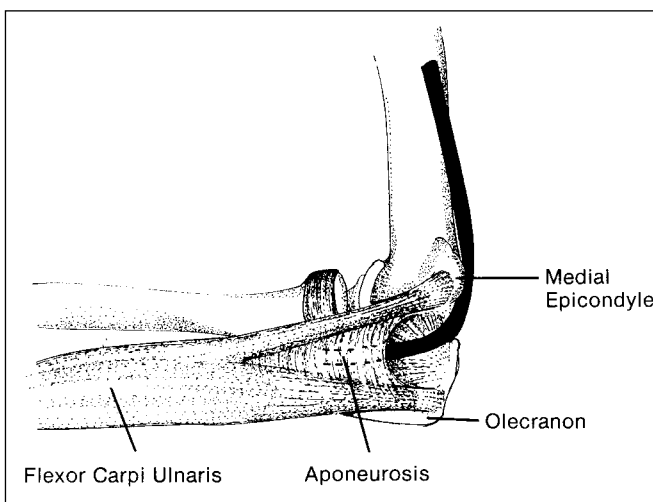
This nerve arises from the brachial plexus and lies on the lateral wall of the axilla and the medial aspect of the upper arm. At the elbow it passes into the ulnar (condylar or retrocondylar) groove behind the medial epicondyle (Figure 2). As it emerges from this groove, it passes under the aponeurotic arch of the flexor carpi ulnaris muscle – also known as the humeroulnar arcade.<sup>2</sup> Beyond this arch/arcade, the ulnar nerve traverses the substance of the flexor carpi ulnaris muscle, lying in the cubital tunnel.<sup>3</sup> It then courses between muscle layers of the forearm to reach the wrist, entering the hand through Guyon's canal.

### Mechanisms of damage to the ulnar nerve at the elbow

Although there are many specific causes of UNE,<sup>4</sup> two general mechanisms are thought to be of major importance in causing damage to this nerve: external compression and flexion of the elbow. The ulnar nerve is prone to external compression because in the condylar groove it rests directly on bone and is covered only by skin and thin subcutaneous tissue. During elbow flexion, the aponeurosis of the flexor carpi ulnaris muscle tightens over the nerve and the medial elbow ligaments bulge and flatten the concave condylar groove.<sup>5-8</sup> Both of these mechanisms cause narrowing of the cubital tunnel and compress the ulnar nerve within it.

### Perioperative UNE

This condition became clearly recognized in the early 1970s. Wadsworth, a British orthopedic surgeon, studied this problem particularly in the light of new anatomical descriptions of the passage of the ulnar nerve through the cubital tunnel.<sup>3,9</sup> He



**Figure 2:** View of the inner surface of the right elbow showing the course of the ulnar nerve (black) in the ulnar groove behind the medial epicondyle and in the cubital tunnel. (See text for details). (Reproduced, with permission from Stewart JD. *Focal Peripheral Neuropathies*. Philadelphia: Lippincott Williams Wilkins, 2000; modified from Kincaid,<sup>30</sup> with permission.)

reasoned that when a patient was lying on his or her back on the operating table, if the arm was placed in a pronated position (ie palm downward) on a flat supporting surface the nerve would be at risk of external compression in the condylar groove. If the arm were supine (ie palm upward), such compression would be avoided. He also noted the danger to the ulnar nerve of elbow flexion. He recommended several arm positions that would help to avoid ulnar nerve damage. At about the same time, others were advocating the use of elbow padding to protect the ulnar nerve at the elbow.<sup>10</sup> Padding and positioning of the elbows to protect the ulnar nerve are now routine practices in operating rooms. However, specific nursing guidelines for these techniques are not given in the recommended standards published by the Association of Operating Room Nurses, Inc., and the Operating Room Nurses Association of Canada.<sup>11,12</sup> In her text "Perioperative Nursing: Principles and Practice", Fairchild<sup>13</sup> instructs simply that the elbow be padded. In "Alexander's Care of the Patient in Surgery", Heizenroth says that arm boards should be padded. She recommends placing the arms in supination which "theoretically protects the ulnar nerve ... However, there is no hard evidence that (this) actually does protect the ulnar nerve".<sup>14</sup> In the publication of the Canadian Anesthesiologists' Society entitled "2001 CAS Guidelines to the Practice of Anesthesia" (Canadian Anesthesiologists' Society, 1 Eglinton Avenue East, Suite 208, Toronto, ON M4P 3A1), there are no instructions regarding arm positioning and padding. In 1993, Stoelting<sup>15</sup> reviewed the literature to date<sup>1,16-20</sup> and concluded that despite positioning the arms as recommended, and/or using padding at the elbow, there was no evidence that these practices decreased the occurrence of perioperative UNE. Others have supported this view.<sup>1,21</sup> These conclusions are further underscored by the fact that the frequency and severity of perioperative UNEs have not changed significantly in two decades despite widespread use of intraoperative ulnar nerve protection.<sup>22</sup>

In the analysis of the Closed Claims Study (see above) data, an important additional fact regarding perioperative UNEs came to light.<sup>1</sup> Of 77 patients with UNEs, 22 noted the time of onset of their symptoms: five were on waking from the anesthesia, three during the first postoperative day, 10 during the first postoperative week, and four at some time two to four weeks following surgery. This clearly points to a substantial number of patients developing UNE in the postoperative period.

These papers were followed by four landmark studies by Warner and colleagues at the Mayo Clinic, Rochester MN.<sup>22-25</sup> The first of these was a large retrospective analysis of 1,129,692 consecutive patients who had undergone diagnostic and non-cardiac surgical procedures with concurrent anesthetic management at the Mayo Clinic from 1957-1991.<sup>23</sup> The authors' findings were:

1. UNE was identified in 414 patients (0.04%).
2. A very small number of UNEs were bilateral.
3. The initial symptoms for most patients were noted more than 24 hours after the procedure.
4. Factors associated with persistent UNE included male gender (70% of patients), duration of hospitalization of more than 14 days, and body habitus (neuropathy more likely to develop in very thin or obese patients), increasing age, and pre-existing diabetes.

5. The duration of the surgery or anesthesia, the type of anesthetic technique and the patient position were all not associated with the development of neuropathy.
6. UNEs developed in some patients who had not undergone a general anesthetic.
7. Of the patients who survived the first postoperative year, 53% were asymptomatic and regained complete motor function and sensation; those with symptoms persisting more than a year had moderate or greater disability from pain or weakness.

Warner et al<sup>22</sup> then performed a prospective study on 1502 adult patients undergoing noncardiac surgical procedures (cardiac surgery was excluded because of the well-known complication of brachial plexus injury associated with those procedures).<sup>26-28</sup> Persons with pre-existing ulnar neuropathy were excluded from the study. Patients were assessed by trained research assistants using a standard questionnaire and neurological examination before surgery, and daily during their hospitalization for seven days after surgery or by telephone interview. All patients who developed signs and symptoms suggestive of UNE were seen by a neurologist; nerve conduction and electromyographic studies were done at the discretion of the neurologist. The patients with UNE were followed for one year. Potential intraoperative risk factors for UNE such as type and duration of surgery, use and location of automatically inflated blood pressure cuffs, arm positions, anesthetic type were recorded. The upper extremities and specifically the elbows of all patients were padded with foam or gel pads.

This study showed that UNE developed in seven patients (0.5%), six of whom were men. Symptoms began two to seven days after surgery. The manifestations were mild and confined to sensory deficits in six patients. Symptoms resolved in four of the seven patients within six weeks. The remaining three patients had residual symptoms two years later. Apart from the association with male gender, no other patient or procedural characteristic was found to be associated with UNE, but the small sample size precluded definitive statements regarding risk factors. The authors emphasized that in all patients the symptoms developed two or more days following the surgery. They speculated that perioperative UNE may be caused by postoperative rather than intraoperative factors. It was noteworthy that these seven patients developed UNE in spite of padding of the elbow, an observation also made by others.<sup>1,15</sup>

Warner et al<sup>24</sup> followed this study with another in which UNE was evaluated in medical patients. The reasoning was that because the previous study had shown delayed onset of UNEs in patients following anesthesia and surgical procedures, perhaps factors associated with hospitalization, rather than intraoperative events, were the cause of such neuropathies. They asked the fundamental question: Do medical patients who are not undergoing surgery also develop UNE during hospitalization? They studied patients admitted with medical conditions who had very similar hospital care characteristics (mainly bed rest) to postoperative patients. This prospective study included 990 patients admitted to Internal Medicine services usually for serious illnesses requiring intravenous treatments. The protocol was identical to that of their surgical study.<sup>22</sup> Two patients (0.2%), both men, developed UNE. Because of the small patient numbers they could not identify any specific patient or other

characteristics associated with the development of UNE. They concluded that prolonged periods of bed rest in the supine position may be an important risk factor for UNE. They pointed out that a common position for hospitalized patients is lying on their back with elbows flexed and their hands resting on their upper abdomen or chest. In this position elbow flexion predisposes the ulnar nerve to compression within the cubital tunnel, and also the nerve may be subjected to prolonged external compression between a firm hospital mattress and the condylar groove. Convalescing patients often spend long periods of time sitting in chairs, with the risk of compressing the ulnar nerve while leaning their elbows against the arm of the chair. These were exactly the same points made by Williams in 1982 when he suggested that perioperative UNEs begin “not on the operating table, but in bed with the patient sitting up, resting on his elbows ... often sit(ting) in an easy chair, resting his elbows as he reads a book or watches television.”<sup>29</sup>

The most recent paper by Warner, et al<sup>25</sup> evaluated the issue of neuropathies developing in the lower limbs following surgical procedures in the lithotomy position. This prospective study also used protocols similar to those of the surgical ulnar study.<sup>22</sup> The authors identified lower extremity neuropathies in 15 of 991 (1.5%) patients. Various nerves were involved. The crucial finding was that symptoms were reported within four hours of completion of the anesthetic in all patients. Symptoms were thus readily noted by patients in spite of persisting sedation or concomitant narcotic administration. This refutes the frequently stated belief that patients may not report symptoms of UNE early after an operation because of sedation and analgesics. In Warner et al's<sup>25</sup> view, the very early onset of symptoms strongly suggests intraoperative nerve damage. They felt that this early onset of symptoms in lower limb neuropathies strikingly contrasts with the delayed onset of symptoms in most perioperative UNEs.<sup>22</sup> They reasoned that this was further evidence that perioperative UNEs most likely occur in the postoperative rather than intraoperative period.

No studies have directly assessed the value of intraoperative arm positioning and elbow padding versus neither of these. Such a study would probably be deemed unethical although in the absence of such a study the value of these practices will never be known. Nor have any studies systematically evaluated the different thickness or types of padding (e.g. gel foam versus other types of foam). An interesting report is that of a patient in whom it was felt that upper limb neuropathy was caused by too much padding.<sup>21</sup>

In this particular Canadian lawsuit, careful attention was paid to the conclusions drawn by Warner and his colleagues. The patient was an older male who required prolonged bed rest after anesthesia and surgery. The UNE developed sometime between his 20th and 25th postoperative day, and so was highly unlikely to have been due to an intraoperative cause. Of note was the discrepancy between the family's recollection that the symptoms started on awakening from the anesthetic, and the lack of any such symptoms recorded in the hospital chart. In their prospective study on perioperative UNE, Warner et al<sup>22</sup> noted a similar discrepancy. At telephone follow-up interviews, two of the seven patients with UNE were adamant that their symptoms had developed shortly after waking from the anesthesia. Both had received legal advice on potential malpractice litigation.

However, when the patients were presented with the evidence that during multiple postoperative assessments they had denied symptoms until postoperative days 4 and 6, the patients and their legal counsels decided not to pursue malpractice suits.

In this recent Canadian case it was unnecessary for the court to make a determination as to whether additional padding, or some different type of padding, may have prevented the UNE in light of the finding that the neuropathy did not occur until sometime after discharge from hospital. However, the issue of padding may well arise in other cases. There are no studies or data available to assist a court in resolving this issue. It would seem prudent, however, to continue the current practice of applying padding to the arm and elbow intraoperatively.

## CONCLUSIONS

1. UNE occurs in patients who have undergone anesthesia and surgery even when there has been what is deemed to be appropriate positioning of the arm and padding of the elbow.
2. The only clear patient characteristic associated with the development of such a neuropathy is male gender.
3. UNE also occurs in ill hospitalized patients who have not undergone anesthesia and surgery.
4. Most perioperative UNEs develop two to seven days following the anesthetic and surgical procedure.
5. Because lower limb neuropathies occurring following operations in the lithotomy position produce symptoms within four hours of waking from the anesthetic, and because most UNEs occur two days or greater following the operation, it is highly likely that most perioperative UNEs are caused by postoperative rather than by intraoperative events. This postoperative trauma to the ulnar nerve may be the result of compression during bed rest or during prolonged periods of sitting, or both.
6. In the rare circumstance of symptoms of a UNE occurring within four hours of waking from anesthesia, it would seem likely that the nerve damage occurred intraoperatively. However, there is no evidence that any amount or any particular type of padding will prevent such UNEs.
7. For these reasons there should generally be no basis for any claim against the surgeon, the anesthetist, or the operating room staff when a UNE develops following anesthesia and surgery.

## REFERENCES

1. Kroll DA, Caplan RA, Posner K, Ward RJ, Cheney FW. Nerve injury associated with anesthesia. *Anesthesiology* 1990;73:202-207.
2. Campbell WW, Pridgeon RM, Riaz G, Astruc J, Sahni KS. Variations in anatomy of the ulnar nerve at the cubital tunnel: pitfalls in the diagnosis of ulnar neuropathy at the elbow. *Muscle Nerve* 1991;14:733-738.
3. Feindel W, Stratford J. The role of the cubital tunnel in tardy ulnar palsy. *Can J Surg* 1958;1:287-300.
4. Stewart JD. *Focal Peripheral Neuropathies*. Philadelphia: Lippincott Williams Wilkins, 2000.
5. Vanderpool DW, Chalmers J, Lamb DW. Peripheral compression lesions of the ulnar nerve. *J Bone Joint Surg* 1968;50B:792-802.
6. Apfelberg DB, Larson SJ. Dynamic anatomy of the ulnar nerve at the elbow. *Plast Reconstr Surg* 1973;51:76-81.
7. Pechan J, Julius I. The pressure measurement in the ulnar nerve: a contribution to the pathophysiology of the cubital tunnel syndrome. *J Biomech* 1975;8:75-79.



8. Gelberman RH, Yamaguchi K, Hollstien SB, et al. Changes in interstitial pressure and cross-sectional area of the cubital tunnel and of the ulnar nerve with flexion of the elbow. An experimental study in human cadavers. *J Bone Joint Surg Am* 1998;80:492-501.
9. Wadsworth TG, Williams JR. Cubital tunnel external compression syndrome. *Br Med J* 1973;1:662-666.
10. Murphy JP, Devers JC. Prevention of postsurgical ulnar neuropathy. *JAMA* 1974;227:1123-1124.
11. Association of Operating Room Nurses, Inc. Standards, Recommended Practices & Guidelines. Deb Reno. 289-290. 1999. Denver, CO, Association of Operating Room Nurses.
12. Operating room nurses association of Canada. Recommended standards for perioperative nursing practice. 4th edition, 1998:113-114.
13. Fairchild SS. Perioperative nursing. Principles and Practice. Philadelphia: Lippincott, 1993.
14. Heizenroth PA. Positioning the patient for surgery. In: Meeker JH, Rothrock JC, (Eds). *Alexander's Care of the Patient in Surgery*. St. Louis: Mosby, 1999:153-65.
15. Stoelting RK. Postoperative ulnar nerve palsy – is it a preventable complication? *Anesth Analg* 1993;76:7-9.
16. Mawk JR, Thienprasit P. Postoperative ulnar neuropathy. *JAMA* 1981;246:2806-2807.
17. Seyfer AE. Upper extremity neuropathies after cardiac surgery. *J Hand Surg* 1985;10A:16-19.
18. Alvine FG, Schurrer ME. Postoperative ulnar nerve palsy: Are there predisposing factors? *J Bone Joint Surg Am* 1987;69:255-259.
19. Roy RC, Stafford MA, Charlton JE. Nerve injury and musculoskeletal complaints after cardiac surgery: influence of internal mammary artery dissection and left arm position. *Anesth Analg* 1988;67:277-279.
20. Dawson DM, Krarup C. Perioperative nerve lesions. *Arch Neurol* 1989;46:1355-1360.
21. Caplan RA, Posner KL, Cheney FW. Perioperative ulnar neuropathy: are we ready for shortcuts? *Anesthesiology* 1994;81:1321-1323.
22. Warner MA, Warner DO, Matsumoto JY, et al. Ulnar neuropathy in surgical patients. *Anesthesiology* 1999;90:54-59.
23. Warner MA, Warner ME, Martin JT. Ulnar neuropathy. Incidence, outcome, and risk factors in sedated or anesthetized patients. *Anesthesiology* 1994;81:1332-1340.
24. Warner MA, Warner DO, Harper CM, Schroeder DR, Maxson PM. Ulnar neuropathy in medical patients. *Anesthesiology* 2000;92:613-615.
25. Warner MA, Warner DO, Harper CM, Schroeder MS, Maxson PM. Lower extremity neuropathies associated with lithotomy positions. *Anesthesiology* 2000;93:938-942.
26. Graham JG, Pye IF, McQueen INF. Brachial plexus injury after median sternotomy. *J Neurol Neurosurg Psychiatr* 1981;44:621-625.
27. Lederman RJ, Breuer AC, Hanson MR, et al. Peripheral nervous system complications of coronary artery bypass graft surgery. *Ann Neurol* 1982;12:297-301.
28. Seyfer AE, Grammer NY, Bogumill GP. Upper extremity neuropathies after cardiac surgery. *J Hand Surg* 1985;10A:16-19.
29. Williams JR. Postoperative ulnar neuropathy. *JAMA* 1980;243:1525-1526.
30. Kincaid JC. The electrodiagnosis of ulnar neuropathy at the elbow. *Muscle Nerve* 1988;11:1005-1015.