

Neuroimaging Highlight

Editor: David Pelz

Intraventricular Localization of an Anaplastic Oligodendroglioma: A Rare Event

Submitted by: Elisa Pomero, Roberta La Piana, Maria del Pilar Cortes, Donatella Tampieri

Can J Neurol Sci. 2012; 39: 649-651

We report an unusual case of an anaplastic oligodendroglioma with secondary intraventricular localization.

CASE DESCRIPTION

In 2004, a 24-year-old woman presented initially with seizures and she was diagnosed, in another centre, with a right frontal space occupying lesion.

She underwent a right frontal craniotomy and a subtotal resection of the lesion. The pathology demonstrated an anaplastic oligodendroglioma (combined allelic losses for 1p and 19q chromosomes, MGMT promoter methylated).

The tumour recurred in 2007 and the lesion was again subtotally resected and treated with chemotherapy and temozolomide.

In spite of the treatment, the lesion continued to increase in size (Figure 1) and the patient was referred to our institution

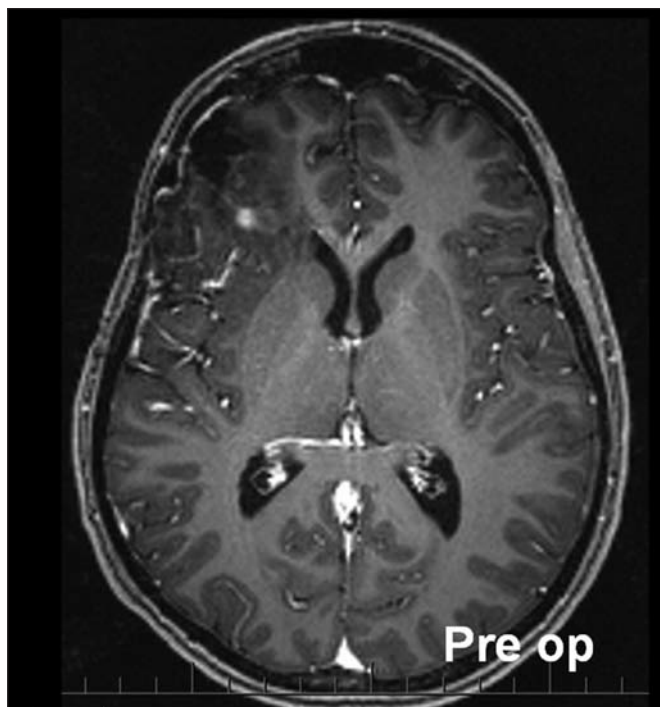


Figure 1: Axial T1-weighted Post Gadolinium (by 3 Tesla Siemens Trio) showing the presence of an anaplastic oligodendroglioma involving the right frontal lobe and the anterior aspect of the cortex of the insula. No evidence of leptomeningeal or ventricular involvement.

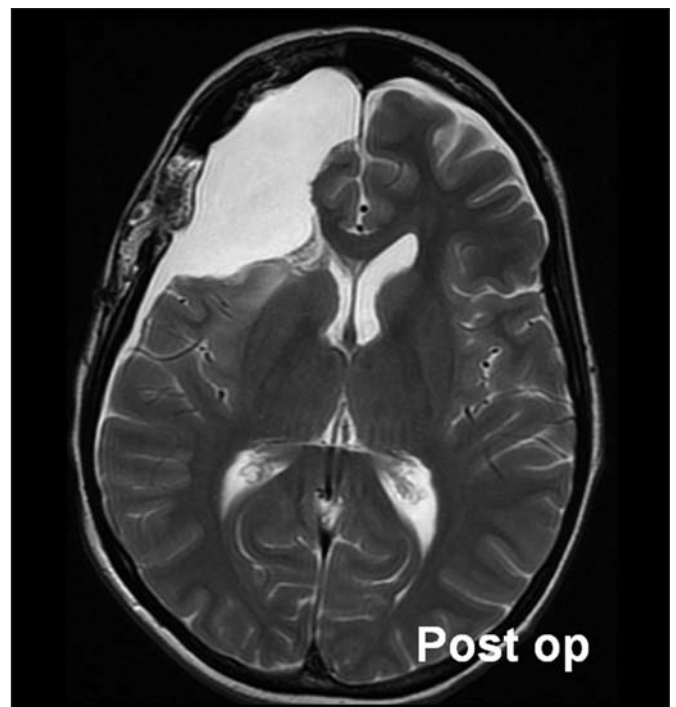

Figure 2: Axial T2-weighted image (by 1.5 Tesla GE Sign Excite). Post surgery, no pathological tissue is seen.

From the Department of Neuroradiology, Montreal Neurological Institute and Hospital, McGill University, Montreal, Quebec, Canada.

RECEIVED AUGUST 15, 2011. FINAL REVISIONS SUBMITTED MARCH 15, 2012.

Correspondence to: Elisa Pomero c/o Dr. Donatella Tampieri, Montreal Neurological Institute and Hospital, Neuroradiology Department, 5th floor, room 540, 3801, rue University, Montreal, Quebec, H3A 2B4, Canada. Email: elisa.pomero@gmail.com.

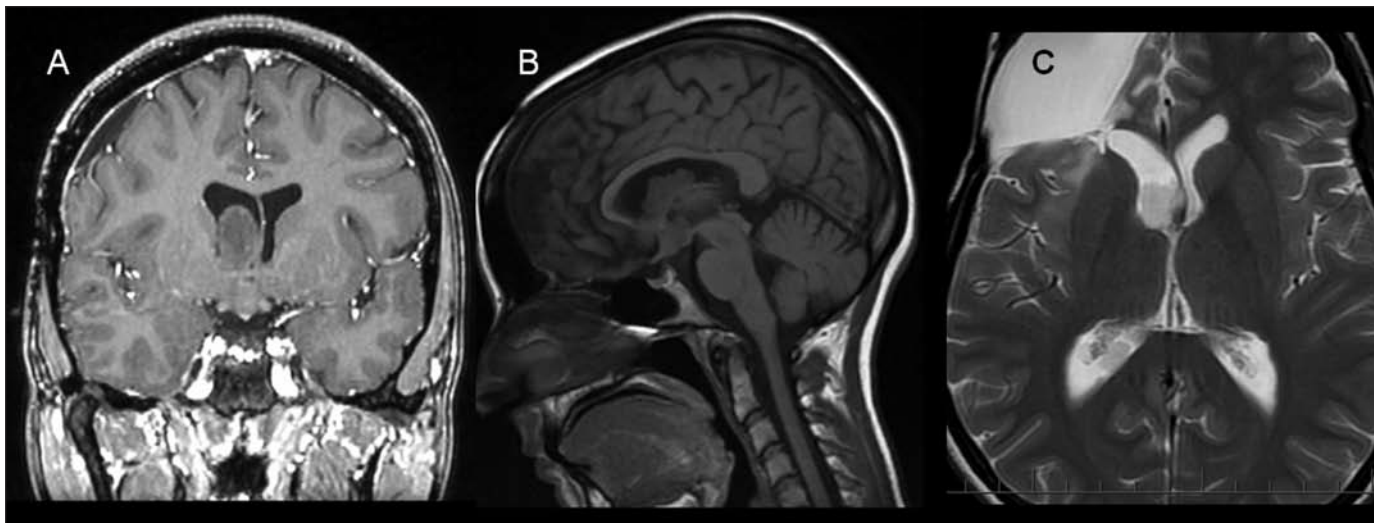


Figure 3: A: Coronal T1-weighted Post Gadolinium (by 1.5 Tesla GE Sign Excite); B: Sagittal T1 FLAIR; C: Axial T2-weighted: images showing three intraventricular lobulated masses: the first arising from the floor (A) of the right lateral ventricle and the second one involving the atrium (C) of the same ventricle. The third one is seen in the anterior recess region of the third ventricle (B).

where a third gross total resection of the tumour was done in 2009 (Figure 2). The pathological analysis confirmed the presence of an oligodendroglioma with moderate cellularity, mild nuclear pleomorphism. Immunohistochemistry for GFAP showed appearance typical for oligodendroglioma. A definite focus with high number of mitotic figures and anaplastic features was evident.

The follow-up MRI of the brain performed in February 2011 demonstrated a lobulated intraventricular mass arising from the

floor of the right lateral ventricle (Figure 3A) and extending medially towards the septum pellucidum. Two other intraventricular lesions were noted, one in the floor of the third ventricle (Figure 3B), the other in the atrium of the right lateral ventricle (Figure 3C).

The larger intraventricular mass was resected in March 2011; the pathology report confirmed the lesion was a recurrent anaplastic oligodendroglioma.

DISCUSSION

Anaplastic oligodendrogliomas frequently arise in the subcortical white matter of the cerebral hemispheres. They are rarely localized within the ventricular system.¹ Intraventricular oligodendroglioma remains a rare diagnosis, with high-grade/anaplastic intraventricular oligodendrogliomas being very uncommon.^{1,2}

We report the case of a patient presenting with an intraventricular localization of oligodendroglioma, focusing on the multiple pathogenetic mechanisms.

Different phenomena have been advocated in the intraventricular localization of oligodendroglioma:

- I) primary diffus leptomeningeal gliomatosis or oligodendrogliosis³⁻⁶;
- II) haematogenous spreading⁷;
- III) intraventricular seeding from a primary oligodendroglioma, either due to a CSF dissemination⁷ or secondary to an invasive procedure such as surgery^{2,7,8}.

In our case, leptomeningeal gliomatosis can be easily ruled out by the absence of leptomeningeal thickening and enhancement^{3,5,6,9}.

Considering the second mechanism, namely spreading through the hematogenous way,^{1,8,10} the secondary localizations, in the floor of the third ventricle and the atrium of the lateral

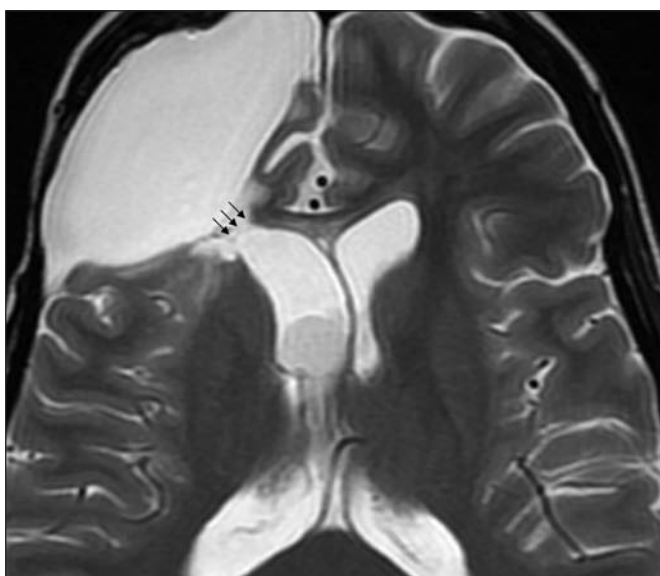


Figure 4: Axial T2-weighted (by 1.5 Tesla GE Sign Excite) demonstrating the ependymal discontinuity (black arrows).

ventricle, could have been assumed to be metastatic given the high vascularisation of these regions.^{8,10} However, in our patient, the lesion in the right lateral ventricle is unlikely related to haematogenous dissemination due to the scarce vascularity of this area.

Allowing for the relatively small amount of cerebrospinal fluid collected during surgery, no tumoral cells were noted.¹¹

Finally, in our patient, the dissemination secondary to surgery is the most probable mechanism responsible for the intraventricular localization. In fact, the multiple craniotomies and surgical excisions could have played a role in facilitating the intraventricular dissemination. In particular, during the third surgery there was opening of the frontal horn, therefore breaching of the ependymal lining occurred, which could have led to intraventricular localization (Figure 4).^{8,10}

ACKNOWLEDGEMENT

Dr. La Piana received a fellowship from the Montreal Neurological Institute.

REFERENCES

1. Van den bent MJ. Anaplastic oligodendroglioma and oligoastrocytoma. *Neurol Clin.* 2007;25(4):1089-109.
2. Zada G, McNatt SA, Gonzalez-Gomez I, McComb JG. Anaplastic intraventricular oligodendroglioma: case report and review of the literature. *Surg Neurol.* 2009;71(6):693-700.
3. Stark AM, Hugo HH, Mehdorn HM, Knerlich-Lukoschus F. Acute hydrocephalus due to secondary leptomeningeal dissemination of an anaplastic oligodendroglioma. *Case Report Med.* 2009;2009:370901.
4. Best PV. Intracranial oligodendrogliomatosis. *J Neurol Neurosurg Psychiatry.* 1963;26:249-56.
5. Russell DS, Beck DJK. Oligodendrogliomatosis of the cerebrospinal pathway. *Brain.* 1942;65:352-60.
6. Cooper IS, Kernohan JW. Heterotopic glial nests in the subarachnoid space; histopathologic characteristics, mode of origin and relation to meningeal gliomas. *J Neuropathol Exp Neurol.* 1951;10(1):16-29.
7. Natelson SE, Dyer ML, Harp DL. Delayed CSF seeding of benign oligodendroglioma. *South Med J.* 1992;85(10):1011-2.
8. Kural C, Pusat S, Sentürk T, Seçer HI, Izci YI. Extracranial metastases of anaplastic oligodendroglioma. *J Clin Neurosci.* 2011;18(1):136-8.
9. Armao DM, Stone J, Castillo M, Mitchell KM, Bouldin TW, Suzuki K. Case Report: Diffuse Leptomeningeal Oligodendrogliomatosis. *AJNR Am J Neuroradiol.* 2000;21(6):1122-6.
10. James TG, Pagel W. Oligodendroglioma with extracranial metastases. *Br J Surg.* 1951;39(153):56-65.
11. Chhieng DC, Elgert P, Cohen JM, Jhala NC, Cangiarella JF. Cytology of primary central nervous system neoplasms in cerebrospinal fluid specimens. *Diagn Cytopathol.* 2002;26(4):209-12.