

# Six-canal video head impulse test in patients with labyrinthine and retrolabyrinthine pathology: detecting vestibulo-ocular reflex deficits

G Kontorinis , H Taylor , T Tikka and M A M Slim

Department of Otolaryngology, Head and Neck Surgery, Queen Elizabeth University Hospital, Glasgow, Scotland, UK

## Main Article

Prof G Kontorinis takes responsibility for the integrity of the content of the paper

**Cite this article:** Kontorinis G, Taylor H, Tikka T, Slim MAM. Six-canal video head impulse test in patients with labyrinthine and retrolabyrinthine pathology: detecting vestibulo-ocular reflex deficits. *J Laryngol Otol* 2023;137:398–403. <https://doi.org/10.1017/S0022215122001153>

Accepted: 5 May 2022

First published online: 16 May 2022

### Key words:

Acoustic Neuroma; Head Impulse Test; Labyrinth; Vertigo; Vestibulo-Ocular Reflex

### Author for correspondence:

Prof Georgios Kontorinis, Department of Otorhinolaryngology, Head and Neck Surgery, Queen Elizabeth University Hospital, 1345 Govan Road, Glasgow G51 4TF, Scotland, UK  
E-mail: [gkontorinis@gmail.com](mailto:gkontorinis@gmail.com)

## Abstract

**Background.** Abnormal gains in six-canal video head impulse test are attributed to semi-circular canal deficits. However, as video head impulse test responses are linked to the vestibulo-ocular reflex, it was hypothesised that abnormal gains can be caused by vestibulo-ocular reflex pathway deficits.

**Methods.** This study compared video head impulse test gains in 20 patients with superior semi-circular canal dehiscence (labyrinthine cause) and 20 side- and gender-matched patients with vestibular schwannomas (retrolabyrinthine cause), and investigated correlations between them (Mann–Kendall trend test).

**Results.** Vestibular schwannoma but not superior semi-circular canal dehiscence was significantly associated with abnormal lateral (odds ratio = 9.00 (95 per cent confidence interval = 1.638–49.44),  $p = 0.011$ ) and posterior (odds ratio = 9.00 (95 per cent confidence interval = 2.151–37.659),  $p = 0.003$ ) canal status. In vestibular schwannoma patients, there was a statistically significant degree of dependence between all ipsilesional canal video head impulse test gains; such dependence was not observed in superior semi-circular canal dehiscence.

**Conclusion.** Vestibulo-ocular reflex gains differ in patients with labyrinthine and retrolabyrinthine disease; this suggests that abnormal gains can indicate deficits not only in the semi-circular canals but also elsewhere along the vestibulo-ocular reflex pathway.

## Introduction

Dizziness is one of the commonest presenting symptoms, affecting approximately 20–30 per cent of the population, while dizziness of peripheral or vestibular cause is believed to affect 5 per cent of the population every year.<sup>1,2</sup> These figures highlight the significance of dealing with the dizzy patient in a timely and efficient manner. While a detailed medical history and clinical examination are paramount in identifying the underlying cause, setting the precise diagnosis, although always crucial for tailored and prompt management, can be challenging, requiring vestibular testing. Among the available assessment batteries, the relatively recently introduced six-canal video head impulse test has been gaining popularity, mainly because of its ease of use and applicability, as well as being well tolerated by patients.<sup>3–6</sup>

The concept of the video head impulse test is based on the vestibulo-ocular reflex. During the vestibulo-ocular reflex, the visual stimulus reaches the inferior olivary nucleus, transmitting the signal to the vestibulo-cerebellum, which subsequently turns this signal to the vestibular nucleus, altering the sensitivity of the vestibular input.<sup>7</sup> In simple words, if the head of an individual whose gaze is fixed on a target is suddenly and rapidly passively rotated horizontally to one side and back, the individual will continue staring at the target, as the eye movement will instantly oppose the head movement. This is caused by the vestibulo-ocular reflex and would correspond to a head movement to eye movement ratio (gain) of 1.<sup>3,4,7</sup> Should there be a deficit in the vestibulo-ocular reflex, then this response will be abnormal, as the eyes will follow the head movement with some delay; the eyes will lose fixation. This delay will be picked up by the video head impulse test, shown as abnormal vestibulo-ocular reflex gain (head to eyes movement ratio is no longer 1), and will be reflected in the presence of overt and covert saccades, where overt saccades are refixation attempts occurring after head movement comes to rest, and covert saccades are those occurring during head motion.<sup>3–7</sup> It is believed that this presence of overt (and covert) saccades with abnormal vestibulo-ocular reflex gain is a sign of canal paresis.<sup>3,4,8</sup>

While head impulse testing was first described three decades ago as an experimental vestibular assessment, it was not until nearly 20 years ago that a head-mounted camera for ocular tracking led to the evolution of the video head impulse test, which is now more widely utilised.<sup>9</sup> Abnormal vestibulo-ocular reflex gains accompanied by overt or covert saccades are believed to show semi-circular canal responses. However, the studies that have led on standardisation of the technique, as well as setting the normal range, are

based on predominantly underpowered cohorts, including a heterogeneous group of patients with various vestibular pathologies.<sup>10,11</sup> Such study heterogeneity generates questions about the precise meaning of abnormal video head impulse test responses.

In the current study, based on the concept that the video head impulse test records vestibulo-ocular reflex gains, we compared the video head impulse test gains between patients with definite labyrinthine pathology and patients with definite retrolabyrinthine disease. Our primary aim was to identify whether video head impulse test responses differ between labyrinthine and retrolabyrinthine pathologies. Meanwhile, our secondary aim was to assess whether video head impulse test gains indicate only semi-circular canal deficit or responses, or responses generated along the vestibulo-ocular reflex pathway rather than by the peripheral vestibular organ. This is, to our knowledge, the first study assessing the precise origins of the video head impulse test responses.

## Materials and methods

### Study settings and patient selection

We carried out a retrospective case-control study in tertiary, academic settings. The study was approved as an audit by the research ethics committee; Caldicott Guardian approval was also granted (approval number: 1008/2021).

We identified 20 patients with unilateral superior semi-circular canal dehiscence, as defined through clinical and audiological findings, high-resolution computed tomography of the temporal bones, and cervical evoked myogenic potentials. All patients with superior semi-circular canal dehiscence were identified through our tertiary referral pathway or records, and were under the care of the first author. The patients with superior semi-circular canal dehiscence were defined as having definite labyrinthine pathology because of the definite anatomical cause of their symptoms. None of the patients with superior semi-circular canal dehiscence had undergone any surgical treatment at the time of the video head impulse tests.

We also included an equinumerous group of patients with unilateral vestibular schwannomas, as determined by magnetic resonance imaging pre- and post-gadolinium administration. These patients were also identified through our tertiary database of patients with vestibular schwannoma, covering a population of 2.2 million. This group was matched to the superior semi-circular canal dehiscence group in terms of gender and side of the pathology. The vestibular schwannoma group was defined by a definite retrolabyrinthine cause. None of the patients with vestibular schwannoma had undergone any previous treatment for their tumour. While we recognise that patients with vestibular schwannoma can have balance problems of a more complex nature, affecting both the labyrinth and the retrolabyrinthine vestibular pathway, we used patients with vestibular schwannoma as the retrolabyrinthine group, given the definite location of the pathology (and accepting it as a weakness of the study).

We did not include patients with vestibular symptoms of other causes, to ensure the definite diagnosis as well as the appropriate classification in labyrinthine and retrolabyrinthine causes. On these grounds, we did not include patients with labyrinthitis or vestibular neuronitis, to avoid equivocal diagnoses, determined through retrospective review of the medical notes. We also excluded patients with vestibular migraines

because of the inability to identify an abnormal (affected) and normal (unaffected) side; on the same grounds, we excluded patients with bilateral vestibular pathology or failure. Patients with benign paroxysmal positional vertigo were also excluded because of the intermittent, short-lasting nature of their symptoms. Finally, we also excluded patients with visual pathologies that could have affected the video head impulse test process or results.

### Video head impulse test settings

Patients were sat upright in a chair situated 1.5 metres from a fixed point on a wall. They were fitted with ICS Impulse® goggles connected to a computer running the accompanying OTOsuite® audiometry software.

The procedure of video head impulse testing has been previously well described.<sup>3,12</sup> For lateral canal testing, the patient's head is briefly and abruptly turned laterally 10–20°. For left anterior and right posterior canals, the head is turned approximately 45° to the right, then briefly and abruptly tilted 10–20°, while for the right anterior and left posterior canals, this is repeated with the head turned approximately 45° to the left. Brief upward tilting stimulates the left posterior, whereas downward tilting stimulates the right anterior. Head movements were performed at a recommended minimum velocity of 120° per second for the lateral canal, and 100° per second for the anterior and posterior canals,<sup>12</sup> while in most of the enrolled cases, a velocity of 200° per second was preferable in order to minimise any performance bias.

Six-canal vestibulo-ocular reflex gains and raw data wave patterns (overt or covert saccades) from video head impulse test reports of each patient were recorded and reviewed; we set the normal gain as 0.8–1.2, as per manufacturer instructions.<sup>12</sup>

### Recorded data and statistical analysis

We recorded basic demographic data, namely age at the time of video head impulse testing, side of the pathology and gender, as well as vestibulo-ocular reflex gains for all six canals as above.

We used Jamovi (version 1.6) statistical software to analyse the data. Numerical data were assessed for normal distribution with the Shapiro–Wilk test and subsequently analysed with the Welch's *t*-test or Wilcoxon rank-sum test. Categorical data were explored with the Fisher's exact test or chi-square test, and subsequently reported as odds ratio when statistically significant differences were noted. The Mann–Kendall trend test (tau-B) was subsequently performed to further explore the presence of correlation between the ipsilesional canals' video head impulse test gains. *P*-values of  $\leq 0.05$  were considered statistically significant.

## Results

### Basic demography

We evaluated 40 patients in this study: 20 patients with unilateral superior semi-circular canal dehiscence and 20 patients with unilateral vestibular schwannoma (Table 1). There were no statistically significant differences in gender and pathological side within this sample (Table 1). The superior semi-circular canal dehiscence cohort was, however, younger than the vestibular schwannoma cohort ( $p < 0.001$ ). None of the

**Table 1.** Basic demographic information

Parameter	Total cases*	Vestibular schwannoma <sup>†</sup>	SSCD <sup>‡</sup>	p-value
Age (mean ± SD; years)	50.7 ± 13.8	58.2 ± 13.9	43.2 ± 9.0	<0.001** (Welch's t-test)
Sex (n (%))				0.752 (χ <sup>2</sup> test)
– Female	19 (47.5)	9 (45.0)	10 (50.0)	
– Male	21 (52.5)	11 (55.0)	10 (50.0)	
Pathological side (n (%))				0.752 (χ <sup>2</sup> test)
– Left	19 (47.5)	10 (50.0)	9 (45.0)	
– Right	21 (52.5)	10 (50.0)	11 (55.0)	

\*n = 40; <sup>†</sup>n = 20; <sup>‡</sup>n = 20. \*\*Indicates statistical significance. SSCD = superior semi-circular canal dehiscence; SD = standard deviation

included patients had undergone any active treatment of their pathology at the time of the video head impulse test; however, all patients were treated accordingly at a later stage, either conservatively or surgically. The management modality is outside the scope of this study.

**Video head impulse test gains analysis**

There were statistically significant differences for the lateral semi-circular canal and posterior semi-circular canal between the vestibular schwannoma and superior semi-circular canal dehiscence groups (Table 2). Based on the lateral semi-circular canal video head impulse test gains, the presence of vestibular schwannoma decreases the video head impulse test gains statistically on the ipsilesional and normal sides (Table 2) compared with superior semi-circular canal dehiscence.

On the contrary, in the posterior semi-circular canal, only the ipsilesional video head impulse test gains were statistically reduced compared with superior semi-circular canal dehiscence (Table 2). Based on categorical data, vestibular

schwannoma is significantly associated with an abnormal lateral semi-circular canal status (odds ratio = 9.00 (95 per cent confidence interval = 1.638–49.44), p = 0.011) and posterior semi-circular canal status (odds ratio = 9.00 (95 per cent confidence interval = 2.151–37.659), p = 0.003). No differences were noted in the superior semi-circular canal.

**Ipsilesional video head impulse test gain correlation**

In vestibular schwannoma, a statistically significant degree of dependence between all ipsilesional semi-circular canal video head impulse test gains was seen (Table 3 and Figure 1), with the strongest correlation between the lateral and the posterior semi-circular canals. Meanwhile, there was only a statistically significant negative correlation between the superior and lateral semi-circular canals in superior semi-circular canal dehiscence (Table 3 and Figure 1).

Overall, there were abnormal responses in both groups, with these being more common in patients with vestibular schwannoma. Additionally, we identified a correlation of the

**Table 2.** vHIT gains analysis

Parameter	Total cases*	Vestibular schwannoma <sup>†</sup>	SSCD <sup>‡</sup>	p-value
SSC pathological status (n (%))				0.197 (χ <sup>2</sup> test)
– Abnormal	16 (40.0)	10 (50)	6 (30)	
– Normal	24 (60.0)	10 (50)	14 (70)	
SSC vHIT gains (mean ± SD)				
– Normal side	0.9 ± 0.2	0.9 ± 0.2	0.8 ± 0.2	0.561 (Welch's t-test)
– Ipsilesional side	0.8 ± 0.2	0.8 ± 0.3	0.9 ± 0.2	0.126 (Welch's t-test)
Lateral SSC pathological status (n (%))				0.014** (Fisher's exact test)
– Abnormal	12 (30.0)	10 (50)	2 (10)	
– Normal	28 (70.0)	10 (50)	18 (90)	
Lateral SSC vHIT gains				
– Normal side (mean ± SD)	0.9 ± 0.1	0.9 ± 0.2	1.0 ± 0.1	0.045** (Welch's t-test)
– Ipsilesional side (median (IQR))	0.87 (0.24)	0.765 (0.537)	0.895 (0.085)	0.02** (Wilcoxon rank-sum test)
Posterior SSC pathological status (n (%))				0.002** (χ <sup>2</sup> test)
– Abnormal	20 (50)	15 (75)	5 (25)	
– Normal	20 (50)	5 (25)	15 (75)	
Posterior SSC vHIT gains (median (IQR))				
– Normal side	0.855 (0.185)	0.835 (0.188)	0.880 (0.158)	0.22** (Wilcoxon rank-sum test)
– Ipsilesional side	0.785 (0.335)	0.550 (0.273)	0.875 (0.130)	<0.01** (Wilcoxon rank-sum test)

\*n = 40; <sup>†</sup>n = 20; <sup>‡</sup>n = 20. \*\*Indicates statistical significance. vHIT = video head impulse test; SSCD = superior semi-circular canal dehiscence; SSC = superior semi-circular canal; SD = standard deviation; IQR = interquartile range

**Table 3.** Correlations of ipsilateral vHIT gains based on pathology

Correlations by pathology	Kendall tau-B	p-value
Vestibular schwannoma		
- Superior SSC – lateral SSC	0.549	<0.001*
- Superior SSC – posterior SSC	0.413	0.012*
- Lateral SSC – posterior SSC	0.578	<0.001*
SSCD		
- Superior SSC – lateral SSC	-0.325	0.047*
- Superior SSC – posterior SSC	0.128	0.435
- Lateral SSC – posterior SSC	0.165	0.313

\*Indicates statistical significance. vHIT = video head impulse test; SSC = superior semi-circular canal; SSCD = superior semi-circular canal dehiscence

vestibulo-ocular reflex gains between the ipsilateral canals as recorded by video head impulse tests in patients with vestibular schwannoma (retrolabyrinthine disease), but not in patients with superior semi-circular canal dehiscence (labyrinthine disease). In particular, the gains of the lateral canals correlated with the gains from the ipsilateral posterior and superior canals in patients with vestibular schwannoma; this was not observed in patients with a labyrinthine cause.

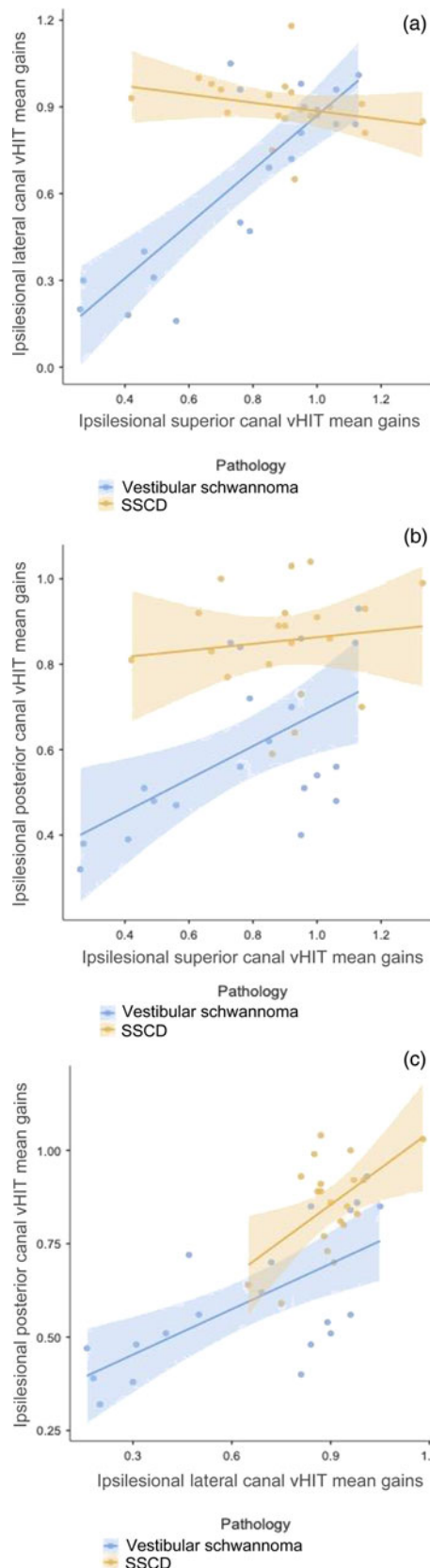
**Discussion**

*Main findings*

In the present study, we assessed vestibulo-ocular reflex gains, as recorded through six-canal video head impulse tests, for two distinct groups of patients, one with definite labyrinthine pathology and one with definite retrolabyrinthine pathology. We showed, to our knowledge for the first time, that in patients with a vestibular schwannoma (retrolabyrinthine cause), there is a statistically significant dependence between all ipsilateral canal gains, while this is not the case in patients with superior semi-circular canal dehiscence (labyrinthine cause). Additionally, abnormal vestibulo-ocular reflex gains were more frequently observed in patients with vestibular schwannoma than in those with superior semi-circular canal dehiscence. Based on our findings, this dependence and correlation of vestibulo-ocular reflex gains in patients with retrolabyrinthine disease could indicate a retrolabyrinthine origin of the video head impulse test responses. In simple words, abnormal video head impulse test gains might not necessarily indicate deficit of the semi-circular canal function only, but, rather, a deficit along the vestibulo-ocular reflex pathway.

*Abnormal vestibulo-ocular reflex gain origin*

This section concerns the hypothesis that abnormal vestibulo-ocular reflex gains do not necessarily originate from the labyrinth. Previous studies have shown that abnormal video head impulse test responses in patients with vestibular schwannoma can implicate the labyrinth but also symptoms associated with the affected nerve,<sup>9,13</sup> as most vestibular schwannomas tend to originate from the inferior vestibular nerve, which innervates the posterior semi-circular canal, abnormal vestibulo-ocular reflex gains from that canal were expected.<sup>9,14</sup> Additionally, abnormal vestibulo-ocular reflex gains can be seen in asymptomatic patients with vestibular schwannoma, indicating a subclinical deficit.



**Fig. 1.** Correlations between video head impulse test (vHIT) gains for ipsilateral semi-circular canals in patients with vestibular schwannoma and superior semi-circular canal dehiscence (SSCD): (a) lateral and superior canals; (b) posterior and superior canals; and (c) posterior and lateral canals.

With respect to superior semi-circular canal dehiscence, vestibular symptoms can have an intermittent character, despite symptoms such as oscillopsia and pressure- or noise-induced vertigo being present on a regular basis.<sup>15-17</sup> One

could use this intermittent character of vestibular symptoms in superior semi-circular canal dehiscence to explain the greater occurrence of abnormal video head impulse test responses in vestibular schwannoma than in superior semi-circular canal dehiscence patients. However, although both vestibular schwannoma and superior semi-circular canal dehiscence are constant and definite as pathologies, their symptomatology is intermittent in nature, particularly when it comes to vestibular symptoms. On these grounds, the intermittent nature of symptoms does not seem an adequate explanation of our findings.

As previously mentioned, the video head impulse test records vestibulo-ocular reflex gains.<sup>3–8</sup> On these grounds, it is sensible to hypothesise that abnormal responses can indicate a deficit along the reflex pathway rather than the canals themselves; we do stimulate the semi-circular canals to get a response, but the response is generated by the vestibulo-ocular reflex pathway. While abnormal vestibulo-ocular reflex gains are believed to indicate canal deficits,<sup>3,4,18</sup> which can be the case, the significant dependence between all semi-circular canals in patients with retrolabyrinthine pathology, and the absence of such correlation in labyrinthine disease, raise the hypothesis of abnormal vestibulo-ocular reflex gains indicating a deficit at a retrolabyrinthine level (for example, in vestibular schwannoma, the vestibular nerve) and not necessarily the canals in isolation.

While the video head impulse test has been developed and marketed as a tool for six-canal assessment, the underpinning physiology is that of canal asymmetry. Caloric testing was traditionally reported with percentage paresis, and so perhaps the video head impulse test should follow suit with gain asymmetry (e.g. laterality of gain).<sup>9</sup>

Finally, one could claim that even in patients with vestibular schwannoma, the vestibular symptoms relate to the impact of the size and growth of the tumour on the inner ear or vestibule, and not on the vestibular nerve per se; therefore, it is not solely a retrolabyrinthine cause. However, the impact of the vestibular schwannoma on the vestibular nerve has been well shown through numerous surgical and clinical studies.<sup>13,14,19</sup>

Given the complexity of the vestibular pathways, we can only support our hypothesis with our present findings rather than prove it. If video head impulse tests only indicated abnormal canal responses, then one would have expected similar relations or dependence between the vestibulo-ocular reflex gains from each canal, regardless of the location of the cause. However, as this relation or dependence differs between labyrinthine and retrolabyrinthine cause (with dependence present only in a retrolabyrinthine cause), it is sensible to assume that abnormal video head impulse test gains can indicate a deficit at a retrolabyrinthine level, too.

### Strengths and limitations

The main weaknesses of our study are its retrospective bias and the small cohort size. As reported above, most studies validating and standardising video head impulse test measurements have so far been based on even smaller cohorts. Given the selected groups, one with vestibular schwannoma patients and one with superior semi-circular canal dehiscence patients, which are both relatively uncommon pathologies, our enrolled numbers are significant.

As per our methods, we accepted the limitations of using patients with vestibular schwannoma as the retrolabyrinthine group. We do recognise that vestibular issues in this group

of patients can be complex; however, there is anatomically a clear retrolabyrinthine cause.

While we did not include a control group without any symptoms at all, because of ethical limitations, we used case-control settings and carefully selected our patients, limited to definite labyrinthine and retrolabyrinthine pathology. We excluded patients with other types of vestibulopathies, where the diagnoses, particularly on retrospective settings, can be vague and debatable; in this way we attempted to overcome issues related to our relatively small sample and any bias associated with the retrospective character of our study.

- There was significant dependence between all ipsilateral canal video head impulse test gains in vestibular schwannoma patients (retrolabyrinthine cause)
- However, such dependence was not observed in superior semi-circular canal dehiscence patients (labyrinthine cause)
- Observed correlations of vestibulo-ocular reflex gains in retrolabyrinthine disease patients could indicate a retrolabyrinthine origin of video head impulse test responses
- Abnormal video head impulse test gains might not indicate semi-circular canal function deficit, rather a vestibulo-ocular reflex pathway deficit
- These findings enhance our understanding of video head impulse test gain origins

While one could argue that our inclusion of only two groups (two types of diagnosis) was a limitation, we consider this patient selection a strength of our work, as it helped us avoid misdiagnoses. Crucially, this is a novel study suggesting the hypothesis that the origins of the video head impulse test responses are along the vestibulo-ocular reflex pathway. While we recognise the challenges in interpreting the presented correlations, these findings should trigger further research.

### Conclusion

We found a correlation in the video head impulse test responses between the semi-circular canals, with a statistically strong dependence in patients with retrolabyrinthine pathology; we did not identify similar patterns in patients with a labyrinthine cause. These results highlight how the vestibulo-ocular reflex gains from the semi-circular canals, as well as the correlations between them, can differ in patients with labyrinthine and retrolabyrinthine disease. They also support the hypothesis that abnormal vestibulo-ocular reflex gains do not necessarily indicate deficit in the semi-circular canals, but, in some cases, reflect deficit elsewhere along the vestibulo-ocular reflex pathway; that is what the video head impulse test records.

**Competing interests.** None declared

### References

- 1 Neuhauser HK, von Brevern M, Radtke A, Lezius F, Feldmann M, Ziese T *et al.* Epidemiology of vestibular vertigo: a neurotologic survey of the general population. *Neurology* 2005;**65**:898–904
- 2 Ludman H. Vertigo and imbalance. *BMJ* 2014;**348**:g283
- 3 Halmagyi GM, Chen L, MacDougall HG, Weber KP, McGarvie LA, Curthoys IS. The Video Head Impulse Test. *Front Neurol* 2017;**8**:258
- 4 Halmagyi GM, Curthoys IS. A clinical sign of canal paresis. *Arch Neurol* 1988;**45**:737–9
- 5 Halmagyi GM, Curthoys IS, Cremer PD, Henderson CJ, Todd MJ, Staples MJ *et al.* The human horizontal vestibulo-ocular reflex in response to high-acceleration stimulation before and after unilateral vestibular neurectomy. *Exp Brain Res* 1990;**81**:479–90

- 6 MacDougall HG, Weber KP, McGarvie LA, Halmagyi GM, Curthoys IS. The video head impulse test: diagnostic accuracy in peripheral vestibulopathy. *Neurology* 2009;**73**:1134–41
- 7 Kandel ER, Dubai Y, Mayford MR. The molecular and systems biology of memory. *Cell* 2014;**157**:163–86
- 8 Weber KP, Aw ST, Todd MJ, McGarvie LA, Curthoys IS, Halmagyi GM. Head impulse test in unilateral vestibular loss: vestibulo-ocular reflex and catch-up saccades. *Neurology* 2008;**70**:454–63
- 9 Tailor H, Gaggini M, Hastings L, Locke R, Crowther JA, Kontorinis G. Subclinical vestibular deficit in six-canal video head impulse testing (vHIT) in patients with vestibular schwannomas. *Clin Otolaryngol* 2020;**45**:139–42
- 10 MacDougall HG, McGarvie LA, Halmagyi GM, Curthoys IS, Weber KP. Application of the video head impulse test to detect vertical semicircular canal dysfunction. *Otol Neurotol* 2013;**34**:974–9
- 11 Macdougall HG, McGarvie LA, Halmagyi GM, Curthoys IS, Weber KP. The video Head Impulse Test (vHIT) detects vertical semicircular canal dysfunction. *PLoS One* 2013;**8**:e61488
- 12 GN Otometrics A/S. ICS Impulse USB User Guide. In: <https://partners.natus.com/asset/resource/17181> [10 April 2018]
- 13 Blödow A, Blödow J, Bloching MB, Helbig R, Walther LE. Horizontal VOR function shows frequency dynamics in vestibular schwannoma. *Eur Arch Otorhinolaryngol* 2015;**272**:2143–8
- 14 Khrais T, Romano G, Sanna M. Nerve origin of vestibular schwannoma: a prospective study. *J Laryngol Otol* 2008;**122**:128–31
- 15 Tikka T, Slim MAM, Gaggini M, Kontorinis G. Video Head Impulse Test (vHIT) findings in patients with superior semicircular canal dehiscence: a case-control study. *J Int Adv Otol* 2021;**17**:103–8
- 16 Carey JP, Migliaccio AA, Minor LB. Semicircular canal function before and after surgery for superior canal dehiscence. *Otol Neurotol* 2007;**28**:355–64
- 17 Park JH, Kim HJ, Kim JS, Koo JW. Costimulation of the horizontal semicircular canal during skull vibrations in superior canal dehiscence syndrome. *Audiol Neurotol* 2014;**19**:175–83
- 18 Weber KP, MacDougall HG, Halmagyi GM, Curthoys IS. Impulsive testing of semicircular-canal function using video-oculography. *Ann N Y Acad Sci* 2009;**1164**:486–91
- 19 Tranter-Entwistle I, Dawes P, Darlington CL, Smith PF, Cutfield N. Video head impulse in comparison to caloric testing in unilateral vestibular schwannoma. *Acta Otolaryngol* 2016;**136**:1110–14