

Neuroimaging Highlight

Amiodarone Producing Insidious Optic Neuropathy

Ryan H. Mason¹, Armin Handzic¹ , Prem A. H. Nichani¹ and Edward A. Margolin^{1,2} 

¹Department of Ophthalmology and Vision Sciences, University of Toronto, Toronto, ON, Canada and ²Department of Medicine, Division of Neurology, University of Toronto, Toronto, ON, Canada

Keywords: Amiodarone-related optic neuropathy; toxic optic neuropathy; optic disk swelling; neuro-ophthamology

(Received 19 May 2023; final revisions submitted 30 July 2023; date of acceptance 31 July 2023; First Published online 4 January 2024)

Amiodarone is one of the most frequently prescribed antiarrhythmic medications. Used in tachycardia and fibrillation management, its efficacy is tempered by clinically significant drug toxicities in 20% of patients.¹ Systemic sequelae include pulmonary fibrosis, thyroid dysfunction, hepatotoxicity, and gastrointestinal

upset. The most common ocular side effect is corneal verticillata, whereby crystalline deposits accumulate in the cornea. A rare and less well-known but important side effect of amiodarone is optic neuropathy. Occurring in less than 2% of users,² vision loss from amiodarone-associated optic neuropathy (AAON) has been the

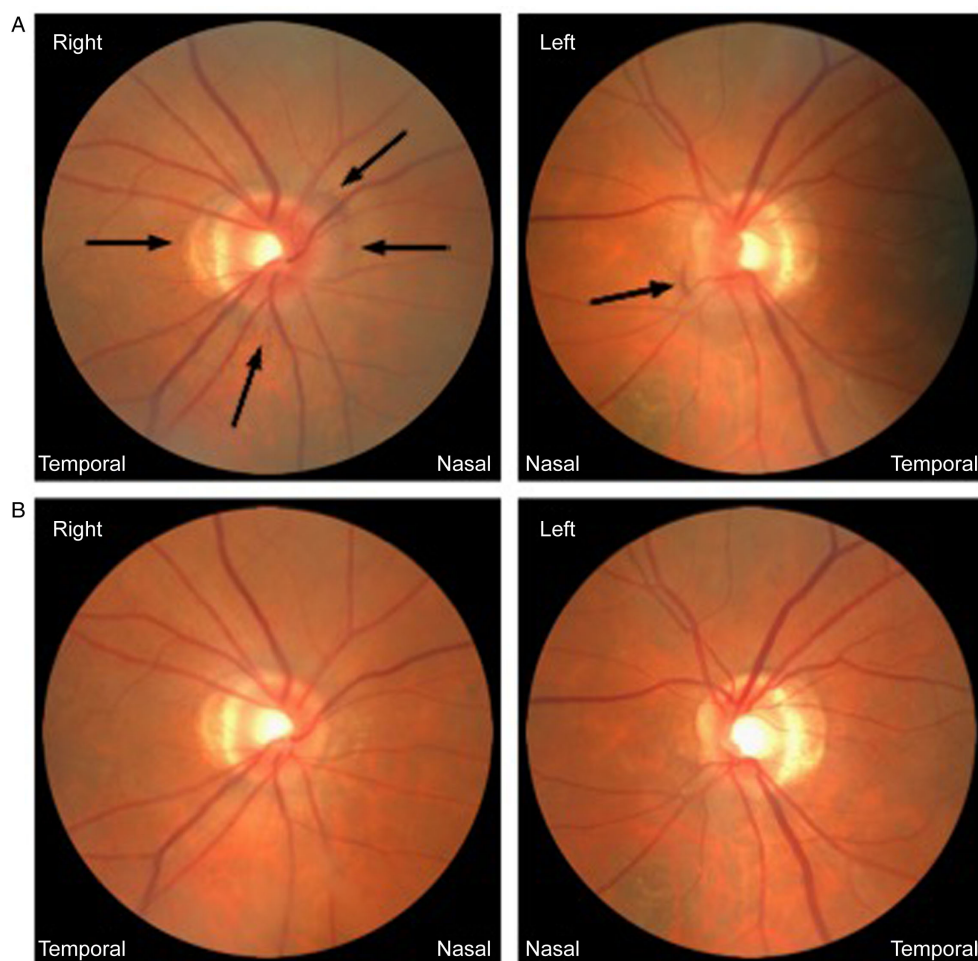


Figure 1: Photographs of the right and left optic disk: (a) at presentation demonstrating mild nasal disk edema, disk hyperemia, and peripapillary hemorrhages being more subtle in the right than left eye (black arrows); and (b) at 6-week follow-up after discontinuation of amiodarone demonstrating resolution of disk edema and hemorrhages and development of temporal disk pallor.

Corresponding author: E. A. Margolin; Email: edward.margolin@uhn.ca

Cite this article: Mason RH, Handzic A, Nichani PAH, and Margolin EA. (2024) Amiodarone Producing Insidious Optic Neuropathy. *The Canadian Journal of Neurological Sciences* 51: 564–565, <https://doi.org/10.1017/cjn.2023.269>

© The Author(s), 2024. Published by Cambridge University Press on behalf of Canadian Neurological Sciences Federation.

subject of multi-million-dollar settlements against pharmaceutical companies.³ Here, we present an illustrative case of AAON.

A 77-year-old woman noticed blurry vision in both eyes for several months. She had a history of paroxysmal atrial fibrillation diagnosed 6 months earlier, for which she required amiodarone 200 mg daily, metoprolol, and apixaban. Her visual acuity was 20/30 in each eye, there was no relative afferent pupillary defect, and anterior segment exam of each eye was normal. Ophthalmoscopy demonstrated small optic disks with mild nasal swelling and few peripapillary hemorrhages (Fig. 1a). Peripapillary optical coherence tomography (OCT) identified mild retinal nerve fiber layer elevation in each eye at 95 μm right and 78 μm left. Ganglion cell analysis of the macular complex and automated visual fields were normal. Amiodarone was discontinued in consultation with her cardiologist. In follow-up 6 weeks later, her disk edema and peripapillary hemorrhages had fully resolved (Fig. 1b). There was minimal residual temporal pallor of each optic disk, more pronounced on the left, a left relative afferent pupillary defect, and mild loss of retinal nerve fiber layer thickness on OCT with average thickness of 81 μm right and 75 μm left.

Few entities present with disk edema and peripapillary hemorrhages in the context of normal or near-normal vision function. Diabetic papillitis is once such entity and represents a poorly understood rare manifestation of diabetic microangiopathy. AAON is another uncommon entity that often presents with unilateral or bilateral optic disk swelling and normal or near-normal visual function. If untreated, however, it can sometimes lead to visual loss. Since patients taking amiodarone are often older with cardiovascular comorbidities, one should differentiate AAON from non-arteritic anterior ischemic optic neuropathy (NAION). In contrast to NAION, AAON is typically insidious in onset, typically bilateral, has normal or near-normal visual function, lacks a “disk-at risk” in the unaffected eye (cup-to-disk ratio of < 0.3), and has a longer duration of disk edema owing to the half-life of amiodarone being up to 100 days.⁴ Our patient’s presentation was thus classic for AAON.

Amiodarone and its metabolites disseminate widely and accumulate as lysosome-like inclusion bodies. Histopathologic and animal studies suggest that intraneuronal or glial cell inclusion bodies within the optic nerve may obstruct axoplasmic flow and result in disk edema and optic neuropathy, although a direct causal

relationship remains speculative.^{5,6} AAON typically occurs within 1 year of drug initiation.⁷ It is unclear if patients taking amiodarone need regular ophthalmic screening, but a detailed ocular assessment should occur if visual symptoms arise. When deciding if amiodarone should be discontinued in the setting of AAON, cardiology consultation is required to evaluate the risk of potentially fatal arrhythmia and alternative treatment options. Following discontinuation, patients may have improvement in visual acuity over several months.

This case reminds neurologists about the ability of amiodarone to produce optic neuropathy with typically bilateral optic disk edema and normal or near-normal visual function. When AAON is correctly diagnosed, it obviates the need for further expensive and anxiety-provoking investigations.

Statement of Authorship. All authors contributed equally to manuscript writing, data gathering, revision, and final approval of the manuscript.

Funding. None.

Competing interests. None.

References

1. Raeder EA, Podrid PJ, Lown B. Side effects and complications of amiodarone therapy. *Am Heart J.* 1985;109:97–83. DOI: [10.1016/0002-8703\(85\)90238-8](https://doi.org/10.1016/0002-8703(85)90238-8).
2. Feiner LA, Younge BR, Kazmier FJ, Stricker BH, Fraunfelder FT. Optic neuropathy and amiodarone therapy. *Mayo Clin Proc.* 1987;62:702–17. DOI: [10.1016/s0025-6196\(12\)65224-0](https://doi.org/10.1016/s0025-6196(12)65224-0).
3. Murphy MA, Murphy JF. Amiodarone and optic neuropathy: the heart of the matter. *J Neuroophthalmol.* 2005;25:232–6. DOI: [10.1097/01.wno.0000177290.09649.38](https://doi.org/10.1097/01.wno.0000177290.09649.38).
4. Latini R, Tognoni G, Kates RE. Clinical pharmacokinetics of amiodarone. *Clin Pharmacokinet.* 1984;9:136–56. DOI: [10.2165/00003088-198409020-00002](https://doi.org/10.2165/00003088-198409020-00002).
5. Mansour AM, Puklin JE, O’Grady R. Optic nerve ultrastructure following amiodarone therapy. *J Clin Neuroophthalmol.* 1988;8:231–7.
6. Costa-Jussa FR, Jacobs JM. The pathology of amiodarone neurotoxicity, I: experimental studies with reference to changes in other tissues. *Brain.* 1985;108:735–52. DOI: [10.1093/brain/108.3.735](https://doi.org/10.1093/brain/108.3.735).
7. Passman RS, Bennett CL, Purpura JM, et al. Amiodarone-associated optic neuropathy: a critical review. *Am J Med.* 2012;125:447–53. DOI: [10.1016/j.amjmed.2011.09.020](https://doi.org/10.1016/j.amjmed.2011.09.020).