

Images

Delayed onset diplopia following head trauma

Caleb P. Canders, MD*; Steve R. Stanford, MD*; Frank C. Day, MD, MPH*

CASE REPORT

A 78-year-old woman presented with proptosis and double vision for 2 weeks. One month prior, she had fallen and suffered a skull fracture with a nonsurgical epidural hematoma. Visual acuity was 20/20 bilaterally. Her right pupil was 2 mm and reactive, and her left pupil was 4 mm and fixed. She had ptosis, inability to adduct, and limited elevation of the left eye (Figure 1). A bruit was auscultated over the left eye. The remainder of her neurological examination was normal. A computed tomography (CT) angiogram of the brain was obtained (Figure 2).

venous pressure and compressing the cavernous sinus contents.¹ Most occur after blunt or penetrating head trauma, although they can also occur spontaneously. The classic triad of symptoms is chemosis, exophthalmos, and orbital bruit. Patients may also present with ophthalmoplegia, facial sensory deficit, ptosis, photophobia, or blindness. Our patient presented with a cranial nerve III palsy. CT angiography is the study of choice to diagnose a carotid-cavernous sinus fistula and commonly demonstrates proptosis, an engorged superior ophthalmic vein, and thick extraocular muscles.²

DISCUSSION

Carotid-cavernous sinus fistula. A carotid-cavernous sinus fistula develops when the carotid artery leaks into the cavernous system, usually over days to weeks, increasing

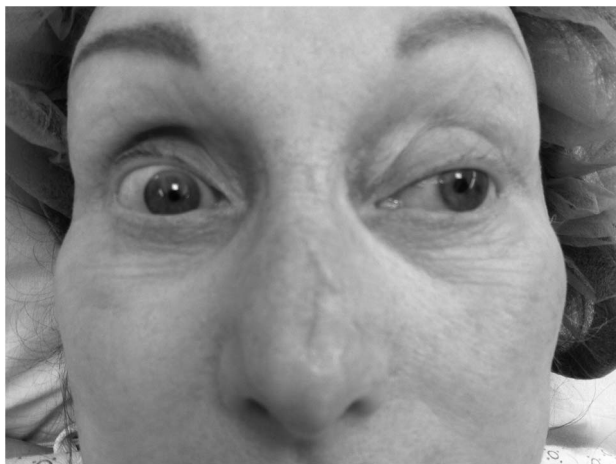

Figure 1. Left eye ptosis and dilated pupil, consistent with a left cranial nerve III palsy.

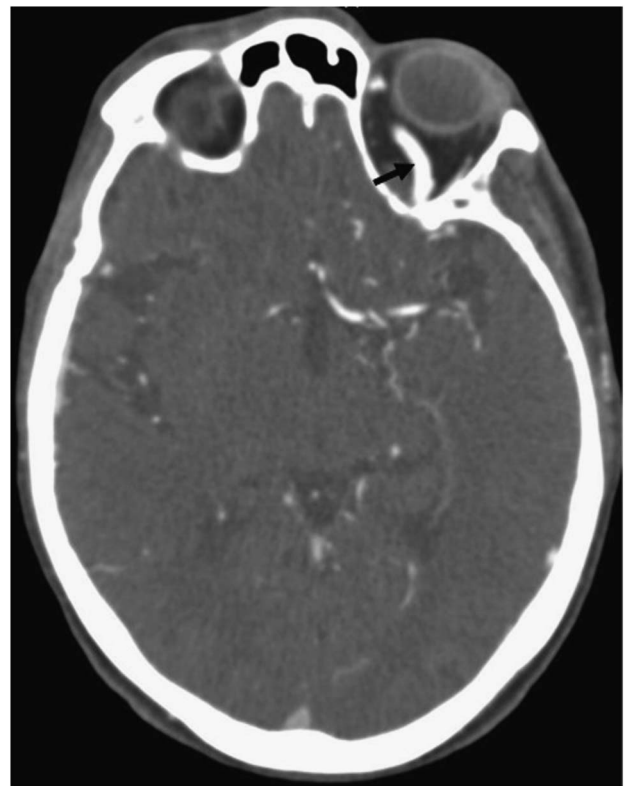


Figure 2. CT angiography demonstrates enlargement of the left superior ophthalmic vein (arrow).

From the *Los Angeles Emergency Medicine Center, University of California, Los Angeles, CA.

Correspondence to: Dr. Caleb P. Canders, Department of Emergency Medicine, David Geffen School of Medicine at UCLA, 924 Westwood Boulevard, Suite 300 | Box 951777, Los Angeles, CA 90095; Email: caleb.canders@gmail.com

© Canadian Association of Emergency Physicians

CJEM 2016;18(2):156-157

DOI 10.1017/cem.2014.67



This diagnosis is important to consider in a patient with pulsating proptosis or an atypical red eye, because patients risk secondary glaucoma and blindness.³ Misdiagnoses include arteriovenous malformations, aneurysms, multiple sclerosis, infections, and malignancies. Our patient underwent cerebral angiography with coil embolization of her fistula, with resolution of her symptoms.

Keywords: carotid, cavernous sinus, fistula, head trauma, diplopia

Competing interests: None declared.

REFERENCES

1. Kaplan JB, Bodhit AN, Falgiani ML. Communicating carotid-cavernous sinus fistula following minor head trauma. *Int J Emerg Med* 2012;5(1):10.
2. Chaudry AI, Elkhamry SM, Al-Rashed W, et al. Carotid cavernous fistula: ophthalmological implications. *Middle East Afr J Ophthalmol* 2009;16(2):57-63.
3. Preechawat P, Narmkerd P, Jiarakongmun P, et al. Dural carotid cavernous sinus fistula: ocular characteristics, endovascular management and clinical outcome. *J Med Assoc Thai* 2008;91(6):852-8.