

LETTER TO THE EDITOR**TO THE EDITOR****Isolated Horner Syndrome as the Only Manifestation of a Large Intrathoracic Schwannoma**

Horner's Syndrome results from disruption anywhere along the oculosympathetic chain, resulting in miosis, ptosis and sometimes, facial anhidrosis. We report a case of Horner Syndrome whose etiology was a large intrathoracic schwannoma and discuss the key features that allowed us to clinically suspect a second order neuron lesion, and to confirm it with targeted imaging

A healthy 31-year-old woman presented with a two-year history of right-sided ptosis. On exam, she had normal acuities and ocular motility. The right palpebral fissure was 2 mm lower than the left. The right pupil was smaller and anisocoria was greater in darkness. She endorsed anhidrosis affecting the whole right side of her face. Apraclonidine 0.5% testing showed reversal of anisocoria and ptosis. Otherwise, her neuro-ophthalmological exam was normal. She had been previously seen by another physician and was investigated with a Magnetic resonance imaging (MRI) and angiogram (MRA) of the head down to the level of C4, which was unremarkable. As the presence of facial anhidrosis was suggestive of preganglionic involvement and the entire preganglionic segment of the oculosympathetic pathway had not been completely investigated, further imaging with MRI–MRA targeted to the neck and upper chest was requested. It revealed a 5 cm mass in the right upper mediastinum close to the expected location of the oculosympathetic pathway. (Figure 1, Figure 2A and B). The patient underwent surgical resection of the mass and pathology revealed a schwannoma.

Horner Syndrome results from disruption of the oculosympathetic chain anywhere along its long and complex course. The first order neuron is located in the hypothalamus and the fibers descend through the brainstem and cervical spinal cord to synapse with the second order neuron, located in the intermediolateral gray substance of the spinal cord, at the level C8–T2. From here, these fibers exit in the ventral spinal roots of C8, T1 and T2, and pass through the stellate ganglion on their way to the superior cervical ganglion. Here they synapse with the third order neuron whose fibers ascend with the internal carotid artery. Once in the cavernous sinus, these fibers briefly join the abducens nerve, and then the ophthalmic division of the trigeminal nerve to subsequently enter the orbit and innervate the retractor muscles of the upper and lower eyelids, as well as the muscle dilator of the pupil. Based on the location of a lesion with respect to the superior cervical ganglion, Horner Syndrome is classified as preganglionic (first and second order neuron) and postganglionic (third order neuron). It is important to remember that the sudomotor fibers that innervate the sweat glands of the face travel along with the oculosympathetic first order and second order neurons (preganglionic). However, distal to the carotid bifurcation, the sudomotor fibers continue along the external carotid artery, whereas the oculosympathetic third order neuron (postganglionic) follows the internal carotid artery. It explains why

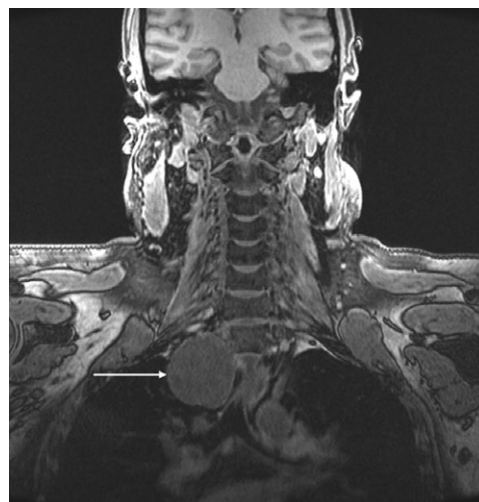


Figure 1. Coronal T1 fat-saturated image without Gadolinium shows a 5 cm mass (white arrow) at the thoracic inlet.

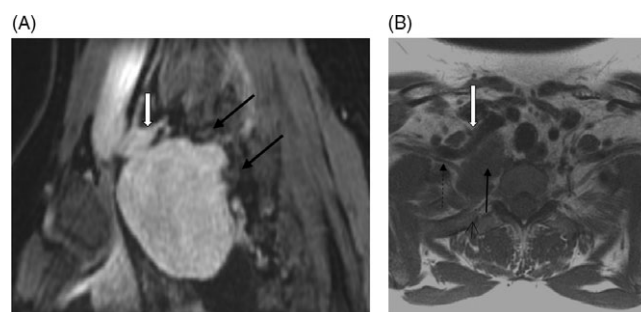


Figure 2. (A) Sagittal post-Gadolinium 3D MRI – Axial fat saturated spoiled gradient image demonstrates the mass bulging posteriorly in between the first and second ribs (thin black arrows). The mass is seen just posterior and slightly below the right subclavian artery (white arrow) at the level of the origin of the vertebral artery, involving the expected location of the stellate ganglion. (B) Axial T1 image at the thoracic inlet demonstrates the mass in the posterior mediastinum (thin black arrow). It is posterior to the right subclavian artery (white arrow) and anterior to the neck of the right first rib (short black arrow). This location would be in the expected vicinity of the stellate ganglion. It is intimately associated with the right C8 nerve root (dashed arrow).

complete facial anhidrosis is only seen in preganglionic lesions. Although a few sudomotor fibers travel with the internal carotid artery, they only innervate the sweat glands in a small patch of the forehead and lateral aspect of the nose, and therefore anhidrosis in postganglionic lesions is confined to that small area.¹

Knowledge of the anatomy and possible associated clinical symptoms and signs depending on the location of the underlying lesion, is essential to appropriately investigate patients with this condition. Pharmacological testing to confirm the diagnosis is recommended and usually achieved by using cocaine or apraclonidine; however, pharmacological localization with hydroxyamphetamine is rarely performed as it is difficult to obtain

and its usefulness has been questioned.² Thus, clinicians must rely on clinical symptoms and physical findings which, when present, help to localize the lesion and target imaging studies. Our patient did not have clinical symptoms or findings on neuroimaging suggestive of lesion of the first order neuron and given the facial anhidrosis, we suspected that the most likely site of involvement was the second order neuron, which was confirmed with targeted imaging.

Establishing a diagnosis begins with the clinical history. It is important to know the anatomy of the oculosympathetic chain to recognize and properly interpret the subtleties of the clinical features. Whereas in many cases of “isolated Horner Syndrome” imaging of the entire oculosympathetic chain is warranted,³ when clinical localization is possible, imaging studies should be targeted accordingly.^{4,5}

CONFLICT OF INTEREST

The authors do not have any financial or proprietary interests to declare.

STATEMENT OF AUTHORSHIP

PM and ARR wrote the manuscript. RR made revisions and approved the final version.

Prima Moinul

Department of Surgery, Division of Ophthalmology, McMaster University, Hamilton, ON, Canada

Ryan Rebello

Department of Radiology, McMaster University, Hamilton, ON, Canada

Amadeo R. Rodriguez

Department of Surgery, Division of Ophthalmology, Department of Medicine, Division of Neurology, McMaster University, Hamilton, ON, Canada

Correspondence to: Dr. Amadeo R. Rodriguez, Hamilton Regional Eye Institute, 2757 King St. East, Hamilton, ON, Canada L8G 5E4. Email: arodrig@mcmaster.ca.

REFERENCES

1. Reede DL, Garcon E, Smoker WRK, Kardon R. Horner's Syndrome: clinical and radiographic evaluation. *Neuroimag Clin N Am*. 2008;18:369–85.
2. Trobe JD. The evaluation of Horner Syndrome. *J Neuro-Ophthalmol*. 2010;30:1–2.
3. Almog Y, Gepstein R, Kesler A. Diagnostic value of imaging on Horner Syndrome in adults. *J Neuro-Ophthalmol*. 2010;30:7–11.
4. Beebe JD, Kardon RH, Thurtell MJ. The yield of diagnostic imaging in patients with isolated Horner Syndrome. *Neurol Clin*. 2017;35(1):145–51.
5. Davagnanam I, Fraser CL, Miszkiel K, Daniel CS, Plant GT. Adult Horner's Syndrome: a combined clinical, pharmacological and imaging algorithm. *Eye*. 2013;27:291–98.