


Lost needle in the oral cavity: can the nightmare be just a bad dream?

Laura Rodríguez-Alcalá¹, Johanna Ximena Valderrama-Penagos¹,
Ernesto O'Connor-García St² and Carlos O'Connor-Reina¹ 

¹Department of Otorhinolaryngology, Hospital Quiron Salud Marbella and Hospital Quiron Salud Campo de Gibraltar, Spain and ²Medicine School, Universidad Rey Alfonso X, Madrid, Spain

Clinical Record

Carlos O'Connor-Reina takes responsibility for the integrity of the content of the paper

Cite this article: Rodríguez-Alcalá L, Valderrama-Penagos JX, O'Connor-García St E, O'Connor-Reina C. Lost needle in the oral cavity: can the nightmare be just a bad dream? *J Laryngol Otol* 2024;**138**:814–817. <https://doi.org/10.1017/S0022215124000264>

Received: 18 October 2023
Revised: 14 November 2023
Accepted: 23 November 2023
First published online: 5 February 2024

Keywords:

Oral pathology; mouth;
sleep medicine specialty; surgical endoscopy;
pediatrics; otorhinolaryngology;
maxillofacial surgery; pharynx

Corresponding author:

Carlos O'Connor-Reina;
Email: Carlos.oconnor@quironosalud.es

Abstract

Objective. The loss of a scalpel or a needle during surgery can threaten the health of the patient and lead to additional costs, and radiographical assistance during surgery has been the only recovery method. This study evaluates the efficacy of a metal detector compared with conventional radiology for recovering a needle lost in the oropharynx during surgery.

Method. Different fragment sizes of needles normally used in pharyngoplasty were embedded at different locations and depths in a lamb's head. Three experienced and three junior otolaryngologists searched for the needle fragments using a metal detector and conventional radiology.

Results. All fragments were found with each method, but the mean searching time was 90 per cent shorter with the metal detector.

Conclusion. A metal detector can be a useful tool for locating needles that break during ENT surgery, as it requires less time than conventional radiology and avoids exposing patients to radiation.

Introduction

The loss of a needle during minimally invasive surgery is rare, but when it occurs, it becomes an emergency that can seriously affect patients' lives. The recovery of lost needles has been described in the literature.¹

The best strategy to avoid such accidents is prevention. However, once lost, there are no established protocols for searching for a lost needle. The incidence ranges between 0.06 per cent and 0.11 per cent,^{2,3} and surgeons who perform minimally invasive surgery face this complication one to five times on average during their professional careers.

Because of the complex manoeuvres with endoscopic suturing, the risk of losing a needle is highest in abdominal procedures (50 per cent of cases), followed by gynaecological and urological procedures.⁴ Associated factors increase the frequency of this complication (Table 1). Therefore, the most effective measure continues to be prevention.⁵

Conventional radiology remains the 'gold standard' for detecting lost surgical instruments.^{1,6–8} Here, we evaluate the effectiveness of a high-sensitivity metal detector compared with conventional radiology for locating a needle lost during ENT surgery.

Materials and methods

We conducted an experiment to locate lost needle fragments (Stratafix™ size 2-0 and V-Loc™ size 9-0 suture needles) on a lamb's head using a high-sensitivity metal detector (model IP-68; Inkbird Plus, Shenzhen, China) (Figure 1).

The weights of the three needle fragments, which had been cut with pliers, were measured using a digital scale (Alfresco, Jiangsu, China) (Figure 2); these were inserted 1 cm inside the posterior two-thirds of the lamb's tongue. Depth was measured with a digital tyre gauge (Katsu Tools, Harrow, UK) (Figure 3).

Three senior otolaryngologists (with more than 10 years of experience) and three junior surgeons (with less than three years of experience) attempted to locate the needle fragments using a metal detector (Appendices 1 and 2) or X-rays (Figure 4). The fragments were hidden three times for each different weight with each procedure. The time it took each surgeon to locate the remnants with each technique was recorded (Tables 2–5).

The metal detector measures 26.5 cm in length and is made of plastic. It is easy to use and transport, unlike an X-ray machine. It has a durable IP66 design that makes it waterproof; therefore, in the case of blood or other liquid spills, there should be no technical problems. The metal detector has audible and vibrating alarms to indicate the presence of metal objects, and is equipped with a protective cover and an accessory hook that help prevent its loss. Its power source is a 9 V battery that must be purchased for use. The working temperature is between –10°C and 30°C. The metal detector is easy to obtain in the domestic market.

Table 1. Factors associated with needles lost during surgery

High BMI
Large number of instruments used
>2 surgical teams
Equipment malfunction
Unexpected changes in procedure
Complicated, lengthy or emergency procedures
Suboptimal communication between team members

BMI = body mass index



Figure 1. High-sensitivity metal detector (model IP-68; Inkbird Plus, Shenzhen, China).



Figure 2. Different sizes of surgical needle fragments are weighed on a digital scale.

Quantitative variables were assessed by calculating the arithmetic mean and standard deviation values. Group differences were assessed using a two-sample paired *t*-test, or a Mann–Whitney U rank sum test if the variable was not

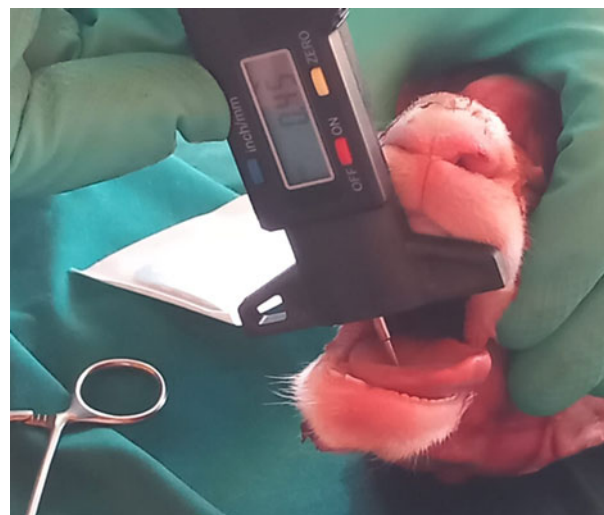

Figure 3. Depth measurement with a digital tyre gauge.

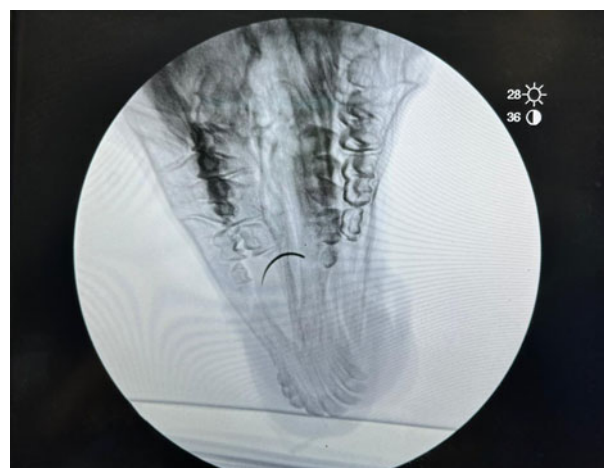

Figure 4. X-ray of a lamb's head with a surgical needle fragment in its tongue.

Table 2. Junior surgeons using metal detector for needle fragment detection

Needle fragment weight (g)	Searching time (mean ± SD; minutes)			
	Surgeon 1	Surgeon 2	Surgeon 3	Average
0.2	4.5 ± 2.2	5.8 ± 2.6	6.5 ± 2.3	5.6 ± 2.4
0.4	5.5 ± 0.2	5.4 ± 2.4	5.1 ± 0.9	5.3 ± 1
0.6	3.4 ± 0.1	4.5 ± 3.8	4.7 ± 0.1	4.2 ± 1.7

SD = standard deviation

Table 3. Experienced surgeons using metal detector for needle fragment detection

Needle fragment weight (g)	Searching time (mean ± SD; minutes)			
	Surgeon 1	Surgeon 2	Surgeon 3	Average
0.2	3.2 ± 1.1	3.8 ± 1.4	3.9 ± 1.3	3.6 ± 1.3
0.4	4.5 ± 0.1	2.3 ± 1.2	4.3 ± 1.4	3.7 ± 1
0.6	3.7 ± 0.2	3.9 ± 1.6	3.1 ± 1.1	3.5 ± 1.1

SD = standard deviation

Table 4. Junior surgeons using X-ray for needle fragment detection

Needle fragment weight (g)	Searching time (mean \pm SD; minutes)			
	Surgeon 1	Surgeon 2	Surgeon 3	Average
0.2	15.3 \pm 2.1	16.5 \pm 5.4	13.1 \pm 4.2	14.9 \pm 3.7
0.4	15.2 \pm 2.8	14.9 \pm 3.9	12.3 \pm 2.1	13.5 \pm 2.2
0.6	13.3 \pm 2.1	13.7 \pm 0.4	11.5 \pm 2.2	12.8 \pm 1.7

SD = standard deviation

Table 5. Experienced surgeons using X-ray for needle fragment detection

Needle fragment weight (g)	Searching time (mean \pm SD; minutes)			
	Surgeon 1	Surgeon 2	Surgeon 3	Average
0.2	12.3 \pm 2.1	15.2 \pm 3.4	12.1 \pm 3.2	13.2 \pm 2.6
0.4	14.2 \pm 3.2	13.2 \pm 3.2	10.3 \pm 2.1	12.5 \pm 2.7
0.6	12.3 \pm 2.1	14.3 \pm 2.3	10.4 \pm 3.2	12.3 \pm 2.9

SD = standard deviation

normally distributed. A p -value of less than 0.05 was considered significant. SPSS Statistics for Windows software (version 20; IBM, Armonk, New York, USA) was used for statistical analysis.

Results

The three junior ENT surgeons detected the needle with the metal detector in an average time of 5.03 ± 1.8 minutes, which included the time needed to use the mouth opener and bring the instrument close to the anatomical location (Table 6). The average time taken by these surgeons to move the X-ray equipment and take radiographs was 13.7 ± 2.8 minutes ($p < 0.005$).

In contrast, the three experienced ENT surgeons detected the needle remnants using the metal detector in an average time of 3.6 ± 1.2 minutes (Table 7). The time taken for these surgeons to detect the foreign body with X-ray was 12.6 ± 2.8 minutes ($p < 0.001$).

Discussion

To our knowledge, this is the first study investigating the use of a metal detector to identify a lost needle during surgery compared with radiology. In cases involving a lost needle, minimally invasive surgery is the first-line procedure.⁷ Given the delicate anatomy of the upper airways and the importance of their functions, lost needles must be located quickly and effectively. Some studies have reported that the detection sensitivity rate of imaging studies inside the operating theatre is strongly correlated with needle size. The X-ray detection sensitivities for needles sized 11–24 mm and those over 25 mm are 85 per cent and 99 per cent, respectively; however, it is only 29 per cent for needles sized 4–10 mm.^{2,8}

The main problem with radiology is the time spent before use to prevent excess radiation exposure to patients. This can lead to increased costs and medical resources. Radiology is also associated with increased operating time and

Table 6. Time taken for junior surgeons to detect needle fragments and significance level between techniques

Needle fragment weight (g)	Searching time (mean \pm SD; minutes)		Significance (p -value)
	Metal detector	X-ray	
0.2	5.6 \pm 2.4	14.9 \pm 3.7	0.001
0.4	5.3 \pm 1	13.5 \pm 2.2	0.003
0.6	4.2 \pm 1.7	12.8 \pm 1.7	0.002
Mean	5.03 \pm 1.8	13.7 \pm 2.8	0.003

SD = standard deviation

Table 7. Time taken for experienced surgeons to detect needle fragments and significance level between techniques

Needle fragment weight (g)	Searching time (mean \pm SD; minutes)		Significance (p -value)
	Metal detector	X-ray	
0.2	3.6 \pm 1.3	13.2 \pm 2.6	0.001
0.4	3.7 \pm 1	12.5 \pm 2.7	0.001
0.6	3.5 \pm 1.1	12.3 \pm 2.9	0.001
Mean	3.6 \pm 1.2	12.6 \pm 2.8	0.001

SD = standard deviation

anaesthesia time, and the transport of equipment and personnel for performing the X-rays.

Several step-by-step protocols for optimal needle recovery have been described in the literature,^{2,6} but none of these protocols includes the use of a metal detector by the surgical team. However, Jayadevan *et al.*² reported that the effectiveness of articulated magnetic recovery devices, such as the ConMed Magnetic Retriever (ConMed, Utica, New York, USA), can increase recovery speed by up to 10 times.

- Lost and broken needles in upper airway surgery necessitate halting the surgery to search for the missing pieces, given the significant morbidity if not recovered
- To date, only conventional radiology recovery has been used, but this involves additional time and transport of equipment during surgery
- Modern metal detectors are useful for detecting this foreign body; they save time for the surgeon and avoid radiation to the patient
- The authors' experience is satisfactory, and metal detectors are present during all upper airway surgical procedures

Instruments that can locate a lost needle fragment are needed because such occurrences remain controversial, and the possible health consequences for the patient, as well as the legal implications for the surgeon, remain a concern. If a needle is large enough to cause a serious injury, it should be identified on a simple X-ray.⁹ However, needles often break, leaving only remnants in the body; these can be identified using computed tomography (CT), especially if they are embedded within an organ.³ The disadvantages of this approach include the impossibility of performing CT at the time of intervention and the associated exposure to high radiation.

The main limitation of this study is that it was carried out on an animal corpse; thus, the anatomical variations between

lambs and humans are a concern. For ethical reasons, this study is difficult to perform on humans. The personal experience of the authors using a metal detector is satisfactory, and this device is always present in the operating theatre when oral surgery is performed.

Conclusion

The loss of a needle during surgery remains a possibility, and prevention is crucial. The present study suggests that a metal detector can be a useful tool for locating a needle lost during ENT surgery because it requires less time than conventional radiology to use and avoids exposing patients to radiation.

Supplementary material. The supplementary material for this article can be found at <https://doi.org/10.1017/S0022215124000264>

Acknowledgements. We acknowledge the assistance of: Manuel Vergara (surgery supervisor from Hospital Quiron Marbella), Dr Felipe Benjumea, Dr Juan Carlos Casado and Dr Carlos López-Azanza (invited surgeons), and Dr Fernando Gallardo (involved in X-ray management).

Competing interests. None declared

References

- 1 Macilquham MD, Riley RG, Grossberg P. Identifying lost surgical needles using radiographic techniques. *AORN J* 2003;**78**:73–8
- 2 Jayadevan R, Stensland K, Small A, Hall S, Palese M. A protocol to recover needles lost during minimally invasive surgery. *JSLs* 2014;**18**:e2014.00165
- 3 Barto W, Yazbek C, Bell S. Finding a lost needle in laparoscopic surgery. *Surg Laparosc Endosc Percutaneous Tech* 2011;**21**:163–5
- 4 Medina LG, Martin O, Cacciamani GE, Ahmadi N, Castro JC, Sotelo R. Needle lost in minimally invasive surgery: management proposal and literature review. *J Robot Surg* 2018;**12**:391–5
- 5 Zaman S, Clarke R, Schofield A. Intraoperative loss of a surgical needle: a laparoscopic dilemma. *JSLs* 2015;**19**:e2013.00401
- 6 Sharma AP, Mete UK, Bendapudidi D, Bora GS, Mavuduru RS. Needle in a haystack: lost in transition. *J Robot Surg* 2018;**12**:177–9
- 7 Möhrenschrager M, Ring J, Henkel V, Jessberger B. Lost needle: a simple search device for the operating room's floor. *Langenbecks Arch Surg* 2007;**393**:1009–11
- 8 Ponrartana S, Coakley FV, Yeh BM, Breiman RS, Qayyum A, Joe BN *et al.* Accuracy of plain abdominal radiographs in the detection of retained surgical needles in the peritoneal cavity. *Ann Surg* 2008;**247**:8–12
- 9 Small AC, Gainsburg DM, Mercado MA, Link RE, Hedican SP, Palese MA. Laparoscopic needle-retrieval device for improving quality of care in minimally invasive surgery. *J Am Coll Surg* 2013;**217**:400–5

Appendix 1. Supplementary video material

A short video demonstrating a metal detector activated by a V-Loc size 9-0 suture needle on a hard surface is available online at *The Journal of Laryngology & Otology* website, at <https://drive.google.com/file/d/184IOzKjk7tjZ-FwcfSDPosVX3FJDJOwQ/view?usp=sharing>.

Appendix 2. Supplementary video material

A short video demonstrating a metal detector activated by a needle inserted in the lamb's tongue is available online at *The Journal of Laryngology & Otology* website, at <https://drive.google.com/file/d/1vxVldOBDwf-j5faltjqcZNFfGp4eS-s/view?usp=sharing>.