

Neuroimaging Highlight

Primary Carotid Stenting

Submitted by: David Pelz, Stephen Lownie

doi:10.1017/cjn.2014.43

Can J Neurol Sci. 2014; 41: 773-774

A 66-year-old male presented with right hemispheric transient ischemic attacks. Computed tomography angiography (CTA) demonstrated a very severe atherosclerotic stenosis of the proximal right internal carotid artery, >95% by NASCET criteria. Carotid stenting was performed using a self-expanding stent (SES) alone, without balloon angioplasty or embolic protection. An immediate anteroposterior (AP) x-ray of the neck (Figure 1) shows the stent in place. A carotid Doppler done the same day demonstrated a peak systolic velocity (PSV) of 142 cm/sec and an internal carotid to common carotid artery (ICA/CCA) velocity ratio of 1.8, corresponding to a stenosis of approximately 50%.

Six weeks later, the stent had gently expanded by itself (Figure 2). The Doppler showed a PSV of 91 cm/sec and an ICA/CCA ratio of 0.87, indicating no residual stenosis. The patient remains asymptomatic.

In the major randomized controlled trials (RCTs) comparing carotid endarterectomy to carotid angioplasty and stenting (CAS), the endovascular procedure is performed using pre-and

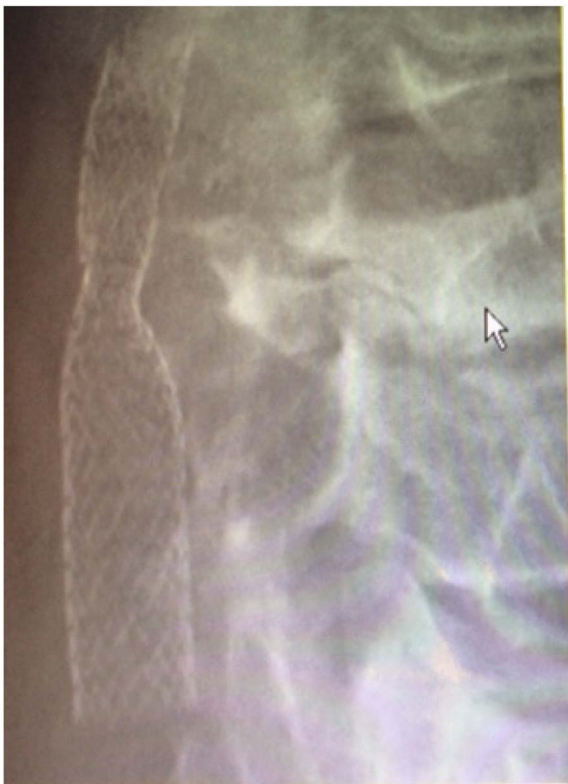

Figure 1: AP neck X-ray immediately post-stenting.

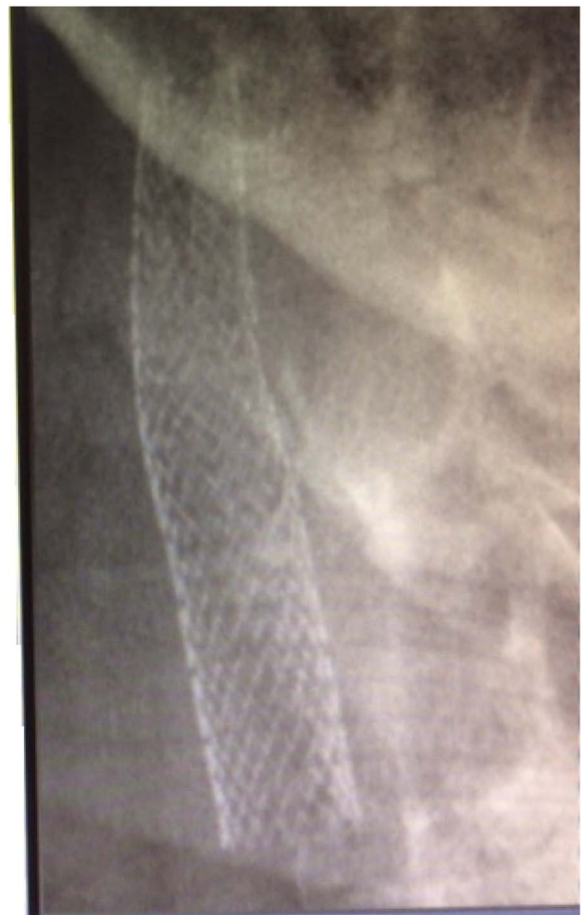

Figure 2: AP neck X-ray 6 weeks post-stenting.

From the Departments of Medical Imaging, and Clinical Neurological Sciences, Schulich School of Medicine and Dentistry, Western University, London, Ontario, Canada.

RECEIVED JULY 15, 2014. FINAL REVISIONS SUBMITTED SEPTEMBER 23, 2014.

Correspondence to: David Pelz, University Hospital - Medical Imaging, 339 Windermere Rd., London, Ontario, N6A5A5 Canada. E-mail: pelz@uwo.ca

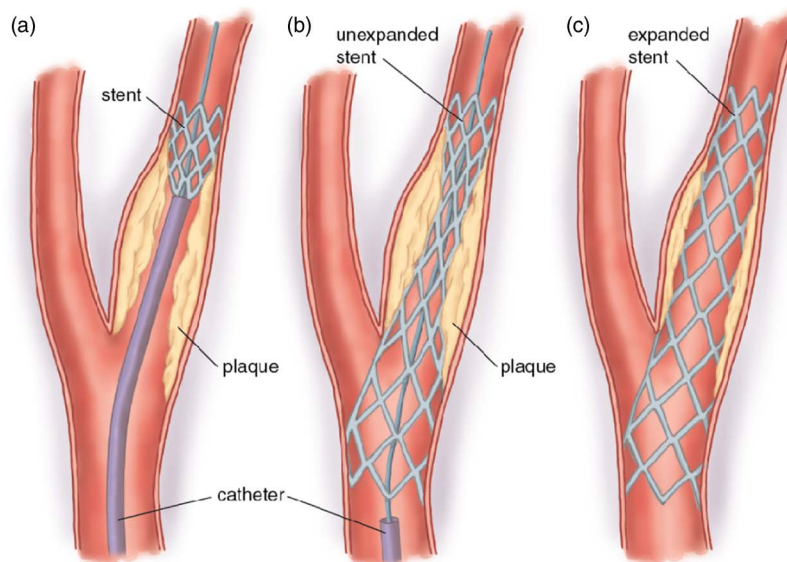


Figure 3: Primary Carotid Stenting. A self-expanding stent alone is used to gently open the internal carotid artery, usually over 4-6 weeks. No balloon angioplasty or embolic protection device is used.

post-stenting balloon angioplasty and embolic protection devices (EPDs).^{1,2} Balloon angioplasty is one of the most embologenic stages of CAS, and may result in significant hemodynamic instability.^{3,4} Embolic protection devices are expensive, do not catch all emboli and are themselves associated with unique complications.⁵ In selected patients, particularly those with little calcification of carotid plaque on CTA source images,⁶ use of balloon angioplasty and EPDs can be avoided. A SES may be all that is required for a successful outcome.^{7,8} This less invasive approach, termed primary carotid stenting (Figure 3) has not yet undergone RCT validation but it is faster, cheaper and potentially safer than standard techniques.^{9,10}

As Occam's Razor tells us: "It is vain to do with more what can be done with less."

ACKNOWLEDGEMENTS

The authors thank Ms. Cathy Carlisle for secretarial assistance.

REFERENCES

1. Brott TG, Hobson RW 2nd, Howard G, et al. Stenting versus endarterectomy for treatment of carotid-artery stenosis. *N Engl J Med.* 2010;363:11-23.
2. International Carotid Stenting Study investigators. Carotid artery stenting compared with endarterectomy in patients with symptomatic carotid stenosis International Carotid Stenting Study: an interim analysis of a randomized controlled trial. *Lancet.* 2010;376:985-97.
3. Almekhlafi MA, Demchuk AM, Mishra S, et al. Malignant emboli on transcranial Doppler during carotid stenting predict postprocedure diffusion-weighted imaging lesions. *Stroke.* 2013;44:1317-22.
4. Qazi U, Obeid TE, Enwerem N, Schneider E, et al. The effect of ballooning following carotid stent deployment on hemodynamic stability. *J Vasc Surg.* 2014;59:756-60.
5. Tallarita T, Rabinstein AA, Cloft H, et al. Are distal protection devices 'protective' during carotid angioplasty and stenting? *Stroke.* 2011;42:1962-6.
6. Pelz DM, Lownie SP, Lee DH, Boulton MR. CTA Plaque Morphology (The PLAC Scale) Predicts Long-Term Anatomic Success of Primary Carotid Stenting. *J Neurosurg.* 2014, In press.
7. Men S, Lownie SP, Pelz DM. Carotid stenting without angioplasty. *Can J Neurol Sci.* 2002;29:175-9.
8. Bussiere M, Pelz DM, Kalapos P, et al. Results using a self-expanding stent alone in the treatment of severe symptomatic carotid bifurcation stenosis. *J Neurosurg.* 2008;109:454-60.
9. Bussiere M, Lownie SP, Lee D, Gulka I, Leung A, Pelz DM. Hemodynamic instability during carotid artery stenting: the relative contribution of stent deployment versus balloon dilation. *J Neurosurg.* 2009;110:905-12.
10. Lopez-Ojeda P, Munoz C, Solo K, Lownie S, Pelz D. Safety evaluation of primary carotid stenting: Embolic detection on intra-procedural transcranial Doppler and correlation with diffusion weighted imaging lesions on postprocedure magnetic resonance imaging. Abstr. 0-891. American Society of Neuroradiology 52nd Annual Meeting, Montreal, Quebec May 2014.