

# Seizure Recurrence 29 Years After Hemispherectomy for Sturge Weber Syndrome

Danielle M. Andrade, Mary-Pat McAndrews, Clement Hamani, Julien Poublanc, Michael Angel, Richard Wennberg

Can. J. Neurol. Sci. 2010; 37: 141-144

Sturge-Weber syndrome (SWS) is a rare congenital disease associated with venous angiomatosis of the leptomeninges and ipsilateral, cutaneous facial port-wine stain (facial angiomatosis). Seizures are seen in more than 80% of cases, cognitive impairment in 50% and frequently glaucoma.<sup>1-2</sup> Seizures are the result of leptomeningeal angioma and underlying calcifications. These abnormalities are usually considered to be limited to one hemisphere.

Frequently, seizures in SWS are refractory to medical treatment. In those cases surgical resection of the affected areas is recommended. Some form of hemispherectomy is usually performed for SWS-associated intractable epilepsy and most patients become seizure-free after surgery.<sup>3-5</sup> Another possible benefit of hemispherectomy is a better cognitive profile in patients that became seizure-free after such a procedure. However, very long follow-ups addressing seizure control and cognitive deficits in hemispherectomized patients are rare and they usually show good outcomes. Here we report on a SWS patient who became seizure-free after hemispherectomy performed in the first year of life, however, seizures recurred 29 years later without any identifiable cause. She also had cognitive decline before the onset of seizures. To the best of our knowledge this is the longest seizure-free interval between hemispherectomy and seizure recurrence in SWS.

## CASE REPORT

This patient was born with a typical right facial port-wine lesion. At two months, she had a five-day period of frequent seizures characterized by head version to the left side and eye blinking. She also had a few secondarily generalized tonic clonic seizures. There is no definite history of clinical status epilepticus. The only electroencephalogram (EEG) report that we have around that period of time showed "continuous interictal epileptiform abnormalities and seizures on the right hemisphere". It is not clear how long it took for the EEG to normalize. A computed tomogram scan was suggestive of SWS with minimal right hemispheric atrophy and virtually no calcifications. An arterio/venogram confirmed abnormalities on the right hemisphere compatible with SWS. The left hemisphere was normal. After a short trial of phenobarbital and phenytoin, she underwent a right anatomical hemispherectomy at age three months. She remained seizure-free on no antiepileptic drugs (AEDs) until she was 29 years old, when she had three secondarily generalized tonic-clonic seizures. At that point she was treated with antiepileptic medication but started to

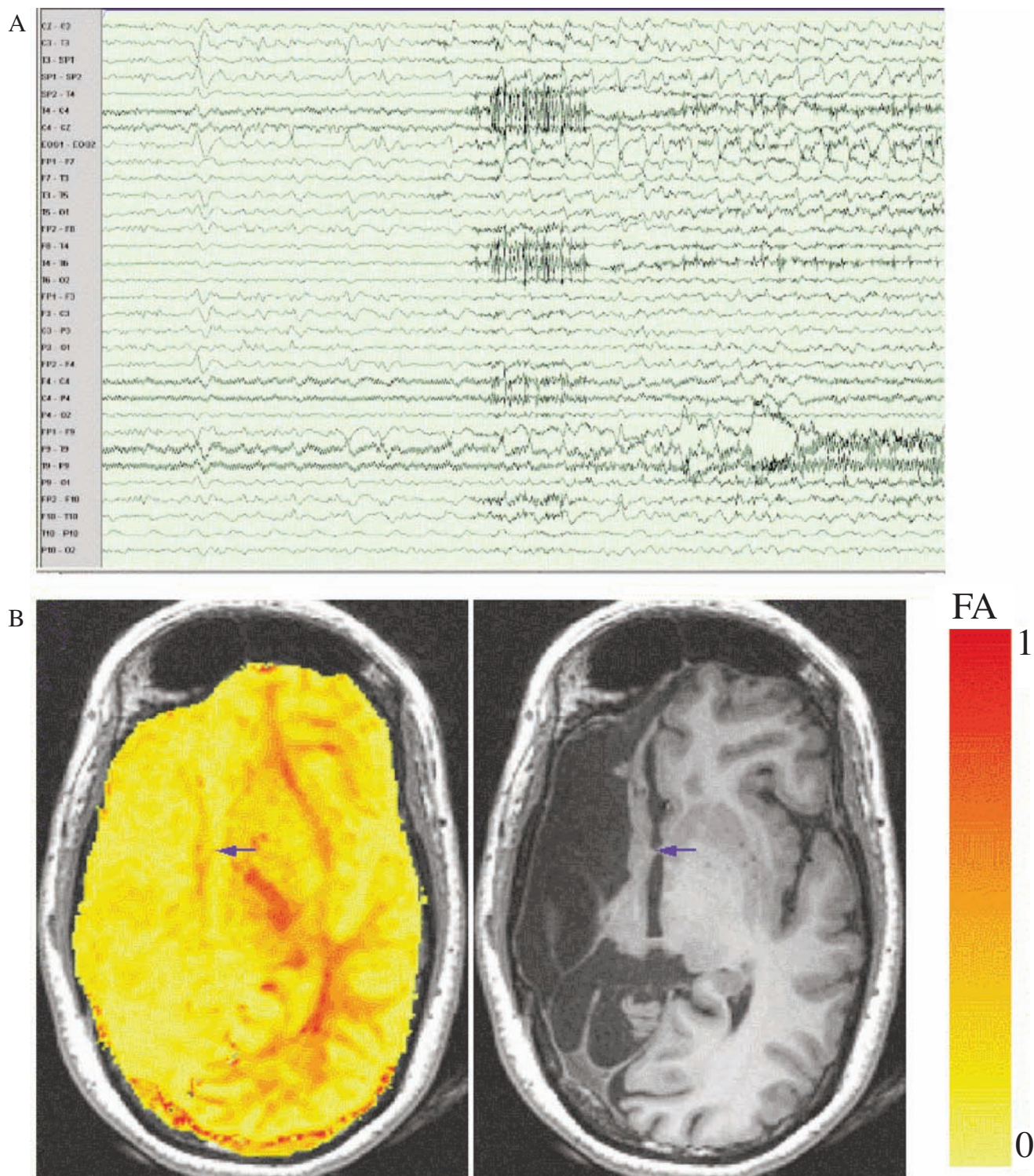
experience complex partial seizures (CPS) marked by unresponsiveness and gestural automatisms. When referred to us she was experiencing 3-10 CPS per month. She was admitted to the Epilepsy Monitoring Unit and six of her typical CPS were recorded, all with left hemispheric temporal lobe onset (Figure A). Interictal EEG revealed unilateral epileptiform potentials and intermittent rhythmic delta activity over the left frontotemporal region, maximal over the anterior temporal zone (in addition to a lateralized EEG suppression over the right hemisphere). Magnetic resonance imaging (MRI) showed no abnormalities in the left hemisphere, the right hemispherectomy and a small strip of retained right frontal lobe (Figure B). The anterior commissure (AC) connecting this strip to the left hemisphere was intact with a fractional anisotropy value low (0.41) but within normal limits for white matter in our control population (0.76 +/- 0.18). These findings suggest that although AC showed some degree of degeneration, its fibers were still connecting both hemispheres. The MR venography was normal.

Neuropsychological assessment at our institution was done when the patient was 31-years-old and at that point she was taking: phenobarbital 120 mg/day; topiramate 175 mg/day; carbamazepine 600 mg/day and gabapentin 300 mg/day. Neuropsychological testing revealed a profound impairment in the non-verbal domain, consistent with the previous hemispherectomy. However, she also showed depressed verbal processing (naming, reading, fluency and memory), reflecting dysfunction of the left temporal lobe. The patient had neuropsychological testing nine times from the time of the hemispherectomy (between ages 8 months and 21 years) until before the reappearance of seizures. The later reports also include reference to her academic development. She had been identified as a special needs student, but aside from a year in a special education classroom (Grade 9) and taking two years to complete Grade 12, she reportedly was able to succeed in the

From the Division of Neurology (DMA, MA, RW), Division of Neuropsychology (MPM), Division of Neurosurgery (CH), Department of Medical Imaging (JP), University of Toronto, Krembil Neuroscience Centre, Toronto Western Hospital, Toronto, Ontario, Canada.

RECEIVED JANUARY 12, 2009. FINAL REVISIONS SUBMITTED JULY 20, 2009.

Correspondence to: Danielle M. Andrade, University of Toronto, Krembil Neuroscience Centre, Toronto Western Hospital, 5-445, 399 Bathurst Street, Toronto, Ontario, M5T 2S8, Canada.



**Figure:** A: Ictal EEG using extended 10-20 system with subtemporal and surface sphenoidal (zygomatic) electrodes, displaying a combination circular and longitudinal bipolar montage. High amplitude ictal pattern is seen over the left hemisphere, maximal over the anterior temporal region (electrodes F7, F9, T3, Sp1). Ictal EEG changes always preceded clinical onsets by at least five seconds. B: MRI shows that the right cerebral hemisphere had been surgically removed. There is a loculated cystic collection filling some of the spaces within the right cranial vault. There is a marked shift of the septum pellucidum to the right. The MRI also shows a strip of retained right mesial frontal cortex. The arrow marks the anterior commissure (AC). Diffusion tensor imaging sequences (25 directions at 3 Tesla) were used to quantify peak fractional anisotropy (FA), which theoretically ranges from 0 (diffusion in all directions, characteristic of cerebrospinal fluid) to 1 (strong anisotropy as shown in major white matter tracts). The peak FA value in the AC for our patient was low (0.47) in comparison with a sample of four age-matched healthy controls (0.76+/- 0.18) but was nevertheless above the typical minimal value used to define white matter in tract-tracing studies.

regular academic classroom, taking basic and general level courses. The assessment reports also indicate that she showed broadly age-appropriate development in language skills for the first six to seven years but that she had some difficulties in later elementary and middle school with word identification, spelling, and verbal comprehension. Thus, although verbal intelligence ratings were at the 25th percentile at age ten, they showed decline afterward (to the low-average or borderline range) as she failed to make age-appropriate gains. Some relevant data include age-appropriate vocabulary with reduced naming, reading speed, comprehension, and fluency. The last assessment prior to the return of seizures was carried out at age 21 to assist with vocational planning. Having completed Grade 12, she showed lags in sight reading (Grade 8), spelling (Grade 6), and reading comprehension (Grade 5), although naming was described as falling within normal limits.

The patient initially failed many AEDs, but finally became seizure-free two years later on four different AEDs (carbamazepine, gabapentin, phenobarbital and topiramate).

## DISCUSSION

To date, there is no report of seizure recurrence this long after hemispherectomy. Our patient had no evidence of left-sided vascular malformation, strokes or calcifications. Secondary epileptogenesis resulting from a short period of frequent right hemispheric seizures in the first months of life might be one possibility. However, there was no MRI evidence of left hippocampal sclerosis to support such a hypothesis. Secondary epileptogenesis caused by subclinical seizures in the small area of residual right frontal cortex is a remote possibility. Although the peak fractional anisotropy value in AC was quite low relative to controls, it was within the range of other viable white matter tracts. However, the establishment of a temporal lobe “mirror” focus in response to contralateral subclinical mesial frontal seizures seems unlikely.

As expected given the right hemispherectomy, our patient had significant cognitive deficits in the non-verbal domain. However, she also had dysfunction of the dominant temporal lobe, which was present before the reappearance of seizures. Early neuropsychological assessments had shown a relative weakness in the verbal domain, before reappearance of seizures. As none of the actual data are available for comparison with performance levels during our assessment, our ability to draw precise conclusions about the nature and rate of verbal function decline is limited. However, it is clear that at the very earliest time points her skills were age-appropriate but that she failed to progress at the rate of her peers. Her performance on various tests of verbal memory parallels the language results.

Seizures starting in infancy are seen in 76-90% of patients with SWS and the majority of these individuals are resistant to pharmacological treatment.<sup>1</sup> In these cases, resective procedures, typically hemispherectomy, are indicated for seizure control. The ideal timing for hemispherectomy is controversial. Proponents of early surgery argue that unilateral seizures may induce bilateral blood flow and metabolic changes that cause progressive damage in SWS.<sup>6,7</sup> It is postulated that these changes may lead to neuronal damage ultimately resulting in cognitive deterioration.<sup>8</sup> This is corroborated by the fact that seizure severity,<sup>9</sup> early onset of seizures and multiple seizure types may predict poor cognitive

outcome.<sup>2,3,8</sup> However, seizures are not the sole offending factor in SWS. In fact, it has been suggested that thrombotic pial events, stagnation of venous blood and hypoxemia can cause gliosis and gradual tissue loss.<sup>10</sup> Hemispherectomy outcomes are usually good, with up to 100% of patients becoming seizure-free after the procedure.<sup>3,4</sup> Some authors have reported periods of seizure freedom as long as 17 years post-hemispherectomy in patients with SWS<sup>11</sup>. However these patients did not have recurrence of seizures for as long as they were followed. When hemispherectomy is not successful, seizures are usually seen shortly after surgery<sup>12</sup>. The longest seizure-free interval reported so far after hemispherectomy has been two years only in a patient that had functional hemispherectomy<sup>13</sup>. The usually poor cognitive profile in those cases is attributed to the effects of ongoing seizures, natural progression of the disease or a combination of these factors.

A recent study of 55 SWS patients followed for a prolonged period (some more than 30 years) documented a progressive character of the disorder. Sequential computed tomography and MRIs demonstrated an increase in density or signal of the cerebral lesion located in the zone subjacent to the leptomeningeal angioma. They also revealed the appearance of cortico-subcortical atrophy in those regions<sup>14</sup>. However, it should be noted that these progressive changes were seen in patients that did not have their leptomeningeal angiomas removed, either through lobectomy or hemispherectomy. In the cases described above, it is possible that the seizures lead to changes in blood flow and metabolism which may have contributed to progression of the structural lesions, as previously suggested<sup>6,7</sup>.

In conclusion, this SWS case demonstrated recurrence of seizures from the left hemisphere, which appeared to be structurally unaffected, 29 years after anatomical right hemispherectomy. To the best of our knowledge this is the longest seizure-free interval reported after hemispherectomy for SWS. There is still some controversy surrounding the surgical treatment of epilepsy, the ideal timing for hemispherectomy, and the hemispherectomy effect on cognitive profile. Some of the literature in this area suggests that active seizures promote tissue damage in the affected and non-affected hemisphere that further contribute to cognitive decline and maintenance of seizures.<sup>6-8</sup> However the present case shows that despite early and aggressive treatment, cognitive decline was still observed and that seizures can appear *de novo* in an apparently unaffected hemisphere.

## REFERENCE

1. Arzimanoglou A, Aicardi J. The epilepsy of Sturge-Weber syndrome: clinical features and treatment in 23 patients. *Acta Neurol Scand.* 1992;140:18-22.
2. Sujansky E, Conradi S. Sturge-Weber syndrome: age of onset of seizures and glaucoma and the prognosis for affected children. *J Child Neurol.* 1995 Jan;10(1):49-58.
3. Arzimanoglou AA, Andermann F, Aicardi J, Sainte-Rose C, Beaulieu M-A, Villemure J-G, et al. Sturge-Weber syndrome: indications and results of surgery in 20 patients. *Neurology.* 2000;55(10):1472-9.
4. Basheer SN, Connolly MB, Lautzenhiser A, Sherman EM, Henderson G, Steinbok P. Hemispheric surgery in children with refractory epilepsy: seizure outcome, complications, and adaptive function. *Epilepsia.* 2007;48(1):133-40.

5. Kossoff EH, Buck C, Freeman JM. Outcomes of 32 hemispherectomies for Sturge-Weber syndrome worldwide. *Neurology*. 2002;59(11):1735-8.
6. Aylett SE, Neville BG, Cross JH, Boyd S, Chong WK, Kirkham FJ. Sturge-Weber syndrome: cerebral haemodynamics during seizure activity. *Dev Med Child Neurol*. 1999;41(7):480-5.
7. Namer JJ, Battaglia F, Hirsch E, Constantinesco A, Marescaux C. Subtraction ictal SPECT co-registered to MRI (SISCOM) in Sturge-Weber syndrome. *Clin Nucl Med*. 2005;30(1):39-40.
8. Sujansky E, Conradi S. Outcome of Sturge-Weber syndrome in 52 adults. *Am J Med Genet*. 1995;57(1):35-45.
9. Kramer U, Kahana E, Shorer Z, Ben-Zeev B. Outcome of infants with unilateral Sturge-Weber syndrome and early onset seizures. *Dev Med Child Neurol*. 2000;42(11):756-9.
10. Hoffman HJ, Hendrick EB, Dennis M, Armstrong D. Hemispherectomy for Sturge-Weber syndrome. *Childs Brain*. 1979;5(3):233-48.
11. Bourgeois M, Crimmins DW, Oliveira RSD, Arzimanoglou A, Garnett M, Roujeau T, et al. Surgical treatment in epilepsy in Sturge-Weber syndrome in children. *J Neurosurg*. 2007;1 Suppl Pediatrics106:20-28
12. Zaiwalla Z, Adams CBT, Oxbury SM, Oxbury JM. Seizures post-hemispherectomy. *Seizure [abstract]* Vol 3, No. 2, 958.
13. Bilgin O, Vollmar C, Peraud A, la Fougere C, Beleza P, Noachtar S. Ictal SPECT in Sturge-Weber syndrome. *Epilepsy Res*. 2008; 78(2-3):240-3.
14. Pascual-Castroviejo I, Pascual-Pascual SI, Velazquez-Fragua R, Viano J. Sturge-Weber syndrome: study of 55 patients. *Can J Neurol Sci*. 2008;35(3):301-7.