

Main Article

Zhengcai Lou takes responsibility for the integrity of the content of the paper

Cite this article: Shen Y, Lou Z. Raising a mucosal flap vs. tympanomeatal flap to repair subtotal perforations. *J Laryngol Otol* 2025; 1–6. <https://doi.org/10.1017/S0022215124001324>

Received: 4 April 2024

Revised: 19 May 2024

Accepted: 28 May 2024

Keywords:

complications; eardrum; endoscope; myringoplasty

Corresponding author:

Zhengcai Lou;

Email: louzhengcai@163.com;

Fax number: +86-057985209678;

Raising a mucosal flap vs. tympanomeatal flap to repair subtotal perforations

Yajian Shen and Zhengcai Lou MD 

Department of Otorhinolaryngology, Yiwu Central Hospital, Yiwu City, Zhejiang Province, China

Abstract

Objectives. This study aimed to compare the graft success rate, hearing outcomes, operation time and complications between myringoplasty with raising of a mucosal flap (RMF) and raising of a tympanomeatal flap (RTF) for the repair of subtotal perforations.

Methods. Subtotal perforations were recruited and randomly allocated to either the RMF group or the RTF group. The graft success rate, hearing outcomes and complications were evaluated at 6 months post-operatively.

Results. The mean operation time was 31.4 ± 2.8 minutes (range: 26–47) in the RMF group and 57.6 ± 0.9 minutes in the RTF group ($p < 0.01$). The graft success rate was 96.0 per cent in the RMF group and 88.9 per cent in the RTF group ($p = 0.659$).

Conclusion. Endoscopic myringoplasty with the RMF achieved similar graft success and hearing gain compared to the tympanomeatal flap technique for repairing subtotal perforations, but with significantly shorter operation time and minimal temporary hypogeusia.

Introduction

The raising of a tympanomeatal flap via an external auditory canal (EAC) incision is a fundamental step in traditional myringoplasty for repairing marginal or large perforations,^{1–3} which can lead to complications such as damage to the chorda tympani, EAC stenosis, iatrogenic cholesteatoma, delayed healing and prolonged operation times.^{4–6} Moreover, it increases intra-operative bleeding and post-operative pain, which is disadvantageous for both patients and surgeons. Recently, some scholars have recommended raising the anterior fibrous annulus and medial EAC skin flap from its bony sulcus without additional anterior canal wall incisions to repair anterior marginal perforations, achieving high graft success.^{7–9} However, scant research has described the technique of raising a mucosal flap for repairing other marginal or subtotal perforations. This study compared the graft success rate, hearing outcomes, operation time and complications between myringoplasty with raising of a mucosal flap (RMF) and raising of a tympanomeatal flap (RTF) for the repair of subtotal perforations.

Materials and Methods

Ethical considerations

The study protocol received approval from the Institutional Ethical Review Board of Yiwu Central Hospital, Yiwu, Zhejiang, China (Ethics No.K2023-IRB-019(GZ)). Informed consent was obtained from all participants.

Study design

The study enrolled subjects from consecutive patients diagnosed with chronic subtotal perforation resulting from chronic suppurative otitis media. The inclusion criteria included marginal perforations with the absence of a tympanic membrane (TM) remnant on at least one side of the perforation; perforations occupying more than half and less than three-quarters of the TM area; patient aged between 18 and 70 years; and no requirement for ossicular chain reconstruction, with the ear being dry for at least 3 months prior to surgery. The exclusion criteria included revision surgery, need for ossicular chain reconstruction, presence of middle ear cholesteatoma or inflammation and fungal otitis externa.

Marginal perforation was defined as the absence of any TM remnant on at least one side before surgery or after de-epithelializing the margins. Subtotal perforation was defined as encompassing between half to three-quarters of the TM area. All procedures were conducted by the same surgeon, with patients undergoing pre-operative high-resolution computed tomography of the temporal bone. The operative time was calculated from the initiation of general anesthesia to the completion of surgery.

Audiometric data were collected before surgery and three months post-operatively. Pure-tone averages (PTAs) were determined at 500, 1000, 2000 and 3000 Hz for both air and bone conduction (BC). When necessary, the threshold at 4000 Hz was used to interpolate the threshold at 3000 Hz, in line with the recommendations of the Hearing

Committee of the American Academy of Otolaryngology–Head and Neck Surgery. Pre- and post-operative air–bone gaps (ABGs) were calculated by subtracting the air-conduction PTAs from the BC PTAs. ABG closure was assessed by the reduction in ABG from pre-operative to post-operative measurements.

Patients were randomly allocated to two groups using a block randomization method. Group allocation was performed using a sealed envelope approach; patients were allocated to either the RMF group ($n = 25$) or the RTF group ($n = 27$).

The mucosal flap was elevated via the middle ear, while the tympanomeatal flap required an additional incision in the EAC. Although the surgeon was aware of the treatment allocation, both the participants and the individual assessing the outcomes were blinded to it.

Surgical techniques

The patient was positioned supine with his or her head tilted upwards at 30°, facing away from the surgeon. Myringoplasty was performed using a cartilage–perichondrium graft and a 0° rigid endoscope (Hangzhou Tonglu Endoscope, Hangzhou City, Zhejiang, China) under total intravenous anesthesia.

Cartilage, including a one-sided perichondrium graft, was harvested from the ipsilateral tragus. The perichondrium was carefully elevated circumferentially, maintaining its connection to the cartilage. The cartilage was shaped approximately 1 mm larger than the perforation margins based on the size of the perforation, while the perichondrium was made 1–2 mm larger than the cartilage graft. A notch was also fashioned in the cartilage graft to accommodate the malleus handle, if present.

Raising mucosal flap group

An inside-out technique was utilized to raise the mucosal flap in cases lacking TM remnants. Approximately 2 mm of mucosa from the tympanic sulcus and 1–2 mm of EAC skin were elevated using a microscopic cross-cutting knife, creating a pocket for placing the perichondrium graft beneath. This approach was adopted particularly where the TM remnant was insufficient, eliminating the need for an additional EAC incision to raise a mucosal flap.

The perforation margins were left without de-epithelialization. In areas with inadequate TM remnants, the mucosal flap was raised approximately 2 mm from the tympanic sulcus via the middle ear using a microscopic cross-cutting knife, and 1–2 mm of EAC skin was elevated from bottom to top (Figures 1 and 2). Any epithelium on the distal malleus handle was removed.

The middle ear was filled to the level of the perforation with biodegradable synthetic polyurethane foam packing (Stryker Canada, Hamilton, Canada). The perichondrium–cartilage composite graft was inserted through the perforation, positioning the cartilage graft medial to the TM remnant and the bony annulus. The notch of the graft was designed to accommodate the malleus, if present. The perichondrium graft was placed medial to the TM remnant and the annulus, and beneath the mucosal flap but lateral to the cartilage and the malleus handle. No packing was used in the EAC.

Raising tympanomeatal flap

The EAC was infiltrated with 2 per cent lidocaine mixed with 1:100 000 epinephrine. The margin of the perforation was

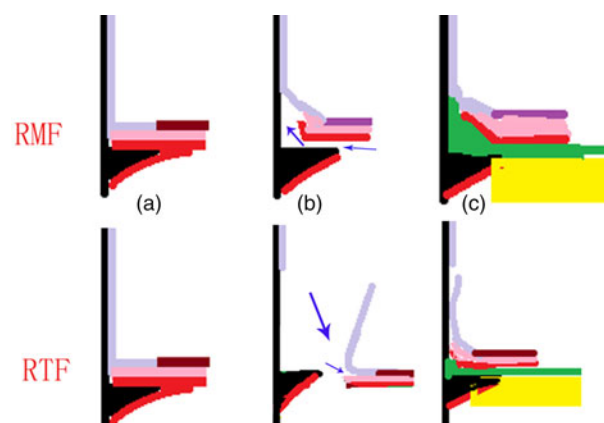


Figure 1. Illustrations of the surgical process. Black: EAC bone; mauve: EAC skin; purple: epidermis; rose: fibrous layer; red: mucosal layer; yellow: cartilage graft; green: perichondrium graft; lime arrows: direction of flap raising. (a) Preoperative view; (b) raising mucosal flap or tympanomeatal flap process; (c) graft placement.

freshened circumferentially. A canal incision was made approximately 3–5 mm lateral to the annulus, and then a tympanomeatal flap was elevated circumferentially from top to bottom through the EAC incision. The annulus was identified, allowing entry into the middle ear. The TM remnant was elevated until the long process of the malleus was visible. The anterior annulus was left undisturbed (Figure 1).

The cartilage–perichondrium graft was inserted trans-tympanomeatal flap into the middle ear, with the cartilage positioned medial to both the TM remnant and the annulus. A notch in the cartilage graft was made to accommodate the malleus handle. Conversely, the free perichondrium was positioned lateral to the long process of the malleus and medial to both the TM remnant and the tympanomeatal flap. Subsequently, the tympanomeatal flap was repositioned. Then EAC was packed with biodegradable synthetic polyurethane foam.

Post-operative follow-up

Patients were discharged the day after surgery and were prescribed a course of antibiotics, specifically amoxicillin, for the post-operative period. Follow-up appointments were scheduled using an endoscope in the outpatient department at two weeks, four weeks, three months and six months after surgery. For patients in the RTF group, the EAC packing was removed at the two-week post-operative visit. During each follow-up, patients were asked about any changes in taste, experiences of vertigo and occurrences of tinnitus. An audiometric evaluation was conducted three months after surgery. Graft success was defined by the presence of an intact graft without perforation, retraction, lateralization, significant blunting, or medialization. Each follow-up was conducted by a surgeon who had not participated in the surgery.

Statistical analyses

Data are presented as mean (standard deviation) for quantitative variables and frequency (percentage) for qualitative variables. Comparisons between groups were made using the independent-samples *t*-test for quantitative variables and the chi-square test for qualitative variables. The paired *t*-test was used to assess differences in ABG thresholds between the

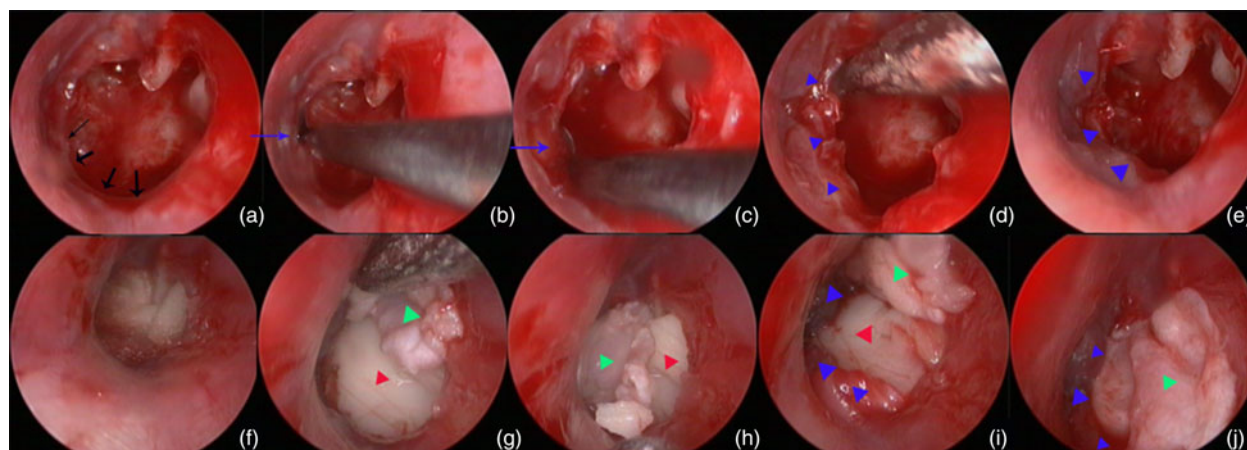


Figure 2. Raising mucosal flap technique. Preoperative perforation (a), process of raising the mucosal flap from the tympanic sulcus (a, b, c, d), middle ear packing (e), placement of the cartilage-perichondrium graft (f), positioning of the cartilage medial to the annulus (g and h), and tucking the perichondrium graft inside the mucosal flap (i). Black arrows: absence of TM remnant; blue arrows: process of raising the mucosal flap from the tympanic sulcus; blue triangle: raising of the mucosal flap; red triangle: cartilage; green triangle: perichondrium.

groups. Statistical analyses were carried out using SPSS (version 20; IBM), with $p < 0.05$ considered statistically significant.

Results

Demographic characteristics

A total of 52 patients met the inclusion criteria for the study, with 25 undergoing the RMF technique and 27 undergoing the RTF technique. The demographic, baseline and surgical characteristics of these patients are summarized in Table 1. There were no significant differences between the groups in terms of age, sex, presence of myringosclerosis, smoking status, duration of perforation, side of the ear affected and diabetes status.

Graft success rate

All patients completed the six-month follow-up. The mean operation time was significantly shorter in the RMF group at

31.4 ± 2.8 minutes (range: 26–47) compared to 57.6 ± 0.9 minutes in the RTF group ($p < 0.01$). At six months post-operatively, the RMF group had one patient with a residual gap-like perforation located between the anterior annulus and graft but no post-operative infections. By contrast, the RTF group had residual perforations in three cases; one was located between the inferior annulus and graft, while the other two small perforations were attributed to post-operative infection, resulting in partial necrosis of the graft. The graft success rate was 96.0 per cent (24/25 patients) in the RMF group and 88.9 per cent (24/27 patients) in the RTF group ($p = 0.659$). Figure 3 shows pre- and post-operative images at three months for a patient in the RTF group.

Hearing outcomes

Post-operative ABG showed significant improvement in both groups compared to pre-operative values. However, there were no significant differences between the groups in pre-operative ($p = 0.624$) or post-operative ($p = 0.583$) ABG values or mean ABG gain ($p = 0.712$). In addition, no significant differences were observed in pre-operative ($p = 0.673$) or post-operative ($p = 0.815$) mean BC PTA (Table 2).

Complications

There were no cases of graft medialization, lateralization, or significant blunting in either group. Temporary changes in taste were reported in two (8.0 per cent) patients in the RMF group and nine (33.3 per cent) patients in the RTF group, with this difference nearing significance ($p = 0.058$). No post-operative infections occurred in the RMF group, whereas two (7.4 per cent) patients in the RTF group experienced post-operative infections. There were no graft cholesteatomas observed in any group. Furthermore, no patients reported sensorineural hearing loss, vertigo or intractable tinnitus in either group.

Discussion

Raising a tympanomeatal flap increases the graft contact area and provides access to the middle ear, facilitating the observation of middle ear lesions. However, advancements in

Table 1. Demographic characteristic of patients

Parameter	RMF group (n = 25)	RTF group (n = 27)	p-Value
Sex (F:M)	14:11	16:11	0.966 ^a
Age (years)	47.9±2.3	48.1±0.8	0.794 ^b
Side of ear (L:R)	16:9	12:15	0.256 ^a
Myringosclerosis (Y:N)	6:19	9:18	0.663 ^a
Smoking status (Y:N)	4:21	6:21	0.828 ^a
Diabetes status (Y:N)	3:22	2:25	0.928 ^a
Duration (years)	8.3±2.1	8.6±1.1	0.853 ^b
Mean operation time (minutes)	31.4±2.8	57.6±0.9	<0.01 ^b
Graft success, n (%)	24 (96.0%)	24 (88.9%)	0.659 ^a
Residual perforation, n (%)	1 (4.0%)	3 (11.1%)	0.710 ^a
Altered taste, n (%)	2 (8.0%)	9 (33.3%)	0.058 ^a
Post-operative infection, n (%)	0 (0.0%)	2 (7.4%)	0.505 ^a

RMF = raising of a mucosal flap; RTF = raising of a tympanomeatal flap.

^aChi-square test.

^bIndependent-samples t-test.

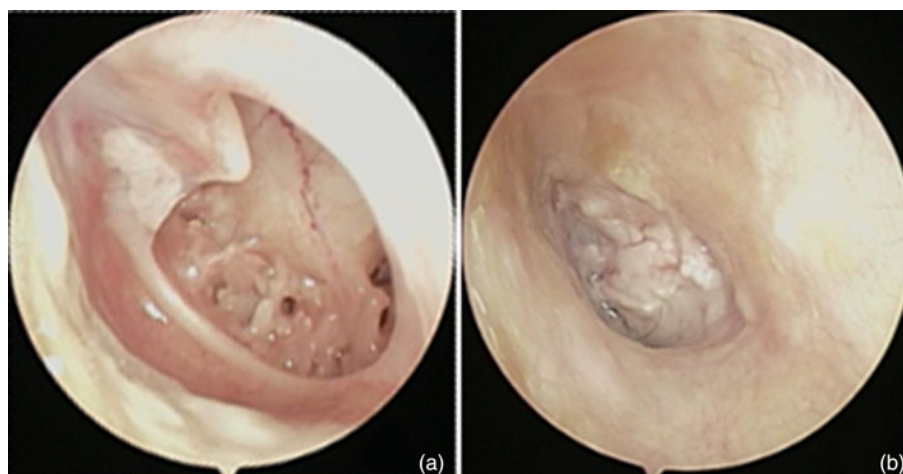


Figure 3. Raising mucosal flap technique. Preoperative perforation (a), and postoperative view at 3 months (b).

endoscopic techniques, particularly with the use of different angles, allow clear observation of the middle ear through perforations, particularly in cases of subtotal or marginal perforations. Moreover, creating a tympanomeatal flap via an EAC incision presents several disadvantages: it increases intra-operative bleeding, contaminating the endoscopic lens and damaging the vascular network of the EAC; it elevates the risk of post-operative infection and EAC scarring, thereby delaying healing; it may induce iatrogenic cholesteatoma; the procedure and associated bleeding prolong operation times; and circumferential elevation of the tympanomeatal flap and tunnel creation are challenging for beginners.^{4–6} From an endoscopic perspective, the primary function of raising a tympanomeatal flap is to increase the graft contact area. Consequently, we used the technique of raising a mucosal flap via the middle ear to enhance the graft contact area while avoiding additional incisions in the absence of a TM remnant. Theoretically, this approach may reduce intra-operative bleeding, post-operative infection and scarring.

Previous studies have described the technique of raising a laterally based anterior EAC skin flap via the anterior fibrous annulus to repair anterior perforations, achieving high graft success.^{7,8,10} Building on this, we developed a method of raising a mucosal flap from the bottom up in cases lacking a TM remnant. This technique starts from the tympanic sulcus via the middle ear to elevate approximately 2 mm of mucosa and then 1–2 mm of EAC skin from the bottom up to create a pocket. By contrast, raising a tympanomeatal flap begins in the EAC and necessitates an additional EAC incision, followed by elevating the annulus fibrosus and TM remnant from top to

bottom. In addition, the mucosal flap is raised only in the absence of a TM remnant, as opposed to the circumferential elevation of the tympanomeatal flap. The perichondrium graft is placed trans-perforation beneath the pocket of the mucosal flap in the mucosal flap technique, while in the tympanomeatal flap technique, it is placed trans-tympanomeatal flap medial to the TM remnant. In our study, the RMF technique significantly reduced the mean operation time compared to the RTF group. Notably, we did not perform the removal of perforation margins, aligning with previous findings that preserving perforation margins does not impact the success of grafts for central perforations.^{11,12} This study reinforces these findings.

Packing the EAC after myringoplasty is a common practice in many hospitals.^{13,14} However, recent studies, including ours, have indicated that omitting EAC packing does not adversely affect graft success.^{15,16} Consequently, the omission of certain routine procedures and the reduced need for elevating EAC skin in the mucosal flap technique account for the approximately 20-minute difference in operation time between the two groups.

In this study, the graft success rate and hearing improvement did not significantly differ between the two groups. The complete closure of the perforation is a critical factor for hearing improvement in myringoplasty cases without ossicular chain lesions. The status of the ossicular chain and the removal of epithelium from the malleus handle were similar between the two groups, indicating that the graft technique did not impact hearing improvement once the perforation was closed. Typically, a contact area of at least 1 mm is

Table 2. Comparison of hearing gains, the air–bone gap and bone conduction

Parameter	Pre-operative (dB ± SD)	Post-operative (dB ± SD)	p ¹	Gain (mean)	p ²
RMTF group (n=25)					
Average ABG, dB	28.6±3.1	16.2 ±4.6	0.001*	12.5 ±2.9	
Average BC PTA, dB	12.9±2.7	13.1±3.2	0.794		
RTYF group (n=27)					
Average ABG, dB	29.1± 1.7	17.2 ±2.5	0.001*	12.1 ±4.1	0.956
Average BC PTA, dB	13.0±1.9	13.7±2.4	0.831		

ABG = air–bone gap; BC = bone conduction; dB = decibel; PTA = pure-tone average; SD = standard deviation.

*p < 0.01.

P¹ indicates paired samples test comparison between the same groups in regard to ABG or bone conduction, pre- and post-operatively.

P² indicates Mann–Whitney U test comparison between two groups in terms of ABG gain.

required between the graft and perforation margins in myringoplasty.^{1,2} In this study, the length of the mucosal flap raised was approximately 2 mm in cases without a TM remnant, with the perichondrium graft placed beneath the mucosal flap to ensure sufficient contact. Some authors have suggested filling any residual gap between the graft and the perforation edge with free perichondrial grafts, creating a continuous surface and thus improving graft success.^{17,18} In addition, the technique of raising a mucosal flap was not affected by the location of the TM remnant's absence and could be easily performed in any direction (anterior, posterior or inferior). This contrasts with raising a tympanomeatal flap via an EAC incision, where creating an anterior EAC flap is more challenging than in other directions.

- The raising of a tympanomeatal flap via an external auditory canal (EAC) incision is a fundamental step in traditional myringoplasty; however, scant research has described the technique of raising a mucosal flap for repairing other marginal or subtotal perforations.
- Endoscopic myringoplasty with the raising of a mucosal flap achieved similar graft success and hearing gain compared to the tympanomeatal flap technique for repairing subtotal perforations.
- Raising a mucosal flap technique resulted in significantly shorter operation time and minimal temporary hypogeusia.

The graft success and hearing improvement achieved with these two techniques are comparable to those reported in other studies using a tympanomeatal flap raised via an EAC skin incision. Angeli *et al.*¹⁹ demonstrated a success rate of 91 per cent with the lateral technique, while Cohen-Vaizer *et al.*²⁰ reported a success rate of 90.8 per cent using inlay triple-C tympanoplasty. Other studies have reported success rates of 94.4 per cent using the L-shaped cartilage graft technique,²¹ 90.3 per cent using the U flap technique²² and 89.8 per cent using the anterior tab flap technique.²³

None of the patients in either group developed worsened sensorineural hearing loss, facial nerve palsy or graft-related complications, such as graft lateralization, significant blunting or medialization, during follow-up. Although the incidence of residual perforation was not significantly different between the two groups, two-thirds of the cases with residual perforations in the tympanomeatal flap technique group were due to partial necrosis of the graft caused by post-operative infection. Previous studies have indicated that prolonged operation times and EAC skin injury increase the risk of post-operative infection in clean perforations,^{24,25} with post-operative infection being a key risk factor for graft failure.²⁶

The incidence of changes in taste was significantly higher in the RTF group than in the RMF group (33.3 per cent vs. 8.0 per cent). Previous reports have noted an initial incidence of taste disturbances after myringoplasty of up to 58 per cent.⁶ Ziylan *et al.*²⁷ reported taste disturbance in 53 per cent of patients following non-inflammatory ear surgery, and Takahashi *et al.*²⁸ found that more than 60 per cent of patients experienced lingual symptoms after surgery. Although specific information on such changes following RTF is scant, some authors suggest that endoscopic surgery does not necessarily reduce the incidence of chorda tympani nerve (CTN) transection during middle ear surgery.^{27,28} This might be because taste disturbances after myringoplasty tend to be underreported, as patients do not often associate these disturbances with their ear surgery unless directly questioned.

The higher incidence of CTN damage may be attributable to the requirement for raising a posterior tympanomeatal flap in all perforations in the RTF group, whereas the RMF group

necessitated only a limited mucosal flap raising in the area lacking a TM remnant. In addition, in the tympanomeatal flap technique, the graft placement followed a post-chorda tympani approach, contrasting with the pre-chorda tympani approach used in the mucosal flap technique, where Takahashi *et al.*²⁸ observed a significantly lower CTN damage score. Notably, EAC packing, used to secure the tympanomeatal flap and prevent EAC stenosis, was found to increase CTN damage, a step avoided in the mucosal flap technique.

The strengths of this study include the complete follow-up of all patients from each group, reinforcing the findings. In addition, the presented approach is adaptable to microscopic graft techniques. However, limitations include the small sample size, potential bias due to the absence of blinding and the relatively short follow-up period.

Conclusions

Endoscopic myringoplasty using the raising of a mucosal flap technique achieved comparable graft success and hearing improvement to the raising of a tympanomeatal flap technique for repairing subtotal perforations but had the advantages of significantly shorter operation times and minimal temporary hypogeusia.

Author contributions. Yajian Shen: Interpretation of data for the work, design of the work, analysis of data for the work, drafting the work, final approval of the version to be published. Zhengcai Lou: Interpretation of data for the work, design of the work, analysis of data for the work, drafting the work, agreement to be accountable for all aspects of the work; final approval of the version to be published.

Data availability statements. All data generated or analyzed during this study are included in the published article.

Competing interests. The author declared no potential conflicts of interest with respect to the research, authorship and/or publication of this article.

Funding. This study was supported by Technology Agency of Jinhua city, China (Grant #2022-3-042).

References

- 1 Schwam ZG, Cosetti MK. Endoscopic myringoplasty and type I tympanoplasty. *Otolaryngol Clin North Am* 2021;**54**:75–88
- 2 Nicholas Jungbauer W Jr, Jeong S, Nguyen SA, Lambert PR. Comparing myringoplasty to type I tympanoplasty in tympanic membrane repair: a systematic review and meta-analysis. *Otolaryngol Head Neck Surg* 2023;**168**:922–34
- 3 Huang Y-B, Hu L-L, Ren D-D, Han Z. Myringoplasty with an ultrathin cartilage-perichondrium complex graft versus temporalis fascia graft: a propensity score-matched analysis. *Otolaryngol Head Neck Surg* 2021;**164**:1287–93
- 4 Iynen I, Dundar R. Chorda Tympani nerve injury during tympanoplasty. Comparison of endoscopic and microscopic methods. *Ann Ital Chir* 2021;**92**:119–22
- 5 Quancheng L, Jiangtao Z, Liang C. Variation and protection of the chorda tympani nerve in endoscopic ear surgery. *Laryngoscope Invest Otolaryngol* 2022;**7**:1107–12
- 6 Berglund M, Suneson P, Florentzon R, Fransson M, Hultcrantz M, Westman E, *et al.* Tinnitus and taste disturbances reported after myringoplasty: data from a national quality registry. *Laryngoscope* 2019;**129**:209–15
- 7 Gülşen S, Arıcı M. Reply to the letter to the editor concerning 'The elevation of the mucosal flap without additional anterior canal wall incisions for repairing anterior perforations using endoscopic cartilage tympanoplasty.' *Eur Arch Otorhinolaryngol* 2020;**277**:1853–4
- 8 Shoman NM. Clinical and audiometric outcomes of palisade cartilage myringoplasty under local anesthetic in an office setting. *Am J Otolaryngol* 2019;**40**:482–6

- 9 Lou Z. Endoscopic cartilage myringoplasty with inside out elevation of a tympanomeatal flap for repairing anterior tympanic membrane perforations. *Ann Otol Rhinol Laryngol* 2020;**129**:795–800
- 10 Gülşen S, Arıcı M. Endoscopic transcanal versus conventional microscopic tympanoplasty in treatment of anterior tympanic membrane perforations. *Eur Arch Otorhinolaryngol* 2019;**276**:3327–33
- 11 Lou Z, Lou Z, Jin K, Sun J, Chen Z. Excising or preserving perforation margins in endoscopic transtympanic cartilage myringoplasty does not affect surgical success. *Clin Otolaryngol* 2022;**47**:94–9
- 12 Lou Z, Lou Z, Lv T, Chen Z. Comparison of endoscopic modified and typical myringoplasty: A randomized controlled trial. *Laryngoscope* 2023;**133**:2779–85
- 13 Borgstein J, de Zwart G, Bruce IA. Ear packing after ear surgery: Is it really necessary? *J Laryngol Otol* 2008;**122**:253–4
- 14 Nakhla V, Takwoingi YM, Sinha A. Myringoplasty: A comparison of bismuth iodoform paraffin paste gauze pack and tri-adcortyl ointment ear dressing. *J Laryngol Otol* 2007;**121**:329–32
- 15 Lou Z, Lou Z, Chen Z. Effect of packing versus no packing in transperforation myringoplasty for chronic tympanic membrane perforations. *Otolaryngol Head Neck Surg* 2023;**169**:1170–8
- 16 Lou Z, Lou Z, Yu D, Wang J, Lv T, Chen Z. Comparison of endoscopic over-underlay technique with and without packing for repairing chronic perforation. *Eur Arch Otorhinolaryngol* 2022;**279**:4761–8
- 17 Wuesthoff C, Hardman J, Saxby AJ, Jufas N, Patel N. How I do it: endoscopic composite cartilage graft tympanoplasty. *Aust J Otolaryngol* 2018;**1**:33
- 18 Vamanshankar H, Mokshagundam R. Endoscopic tragal cartilage graft for tympanoplasty: a case series. *Jpn J Otolaryngol* 2020;**1**:102
- 19 Angeli SI, Kulak JL, Guzmán J. Lateral tympanoplasty for total or near-total perforation: prognostic factors. *Laryngoscope* 2006;**116**:1594–9
- 20 Cohen-Vaizer M, Barzilai R, Shinnawi S. Inlay triple- “C” tympanoplasty: a comparative study for its use in large, marginal perforations. *Eur Arch Otorhinolaryngol* 2021;**278**:3715–22
- 21 Linares Casas A, Ruiz R, De Pauli D. Endoscopic type 1 tympanoplasty: a composite graft technique for subtotal and total perforations. *Eur Arch Otorhinolaryngol* 2022;**279**:181–6
- 22 Dhungana S, Rayamajhi P, Shrivastav RP. Outcome of graft uptake and hearing results between ‘U’ flap technique and conventional tympanomeatal flap technique for anterior and subtotal tympanic membrane perforation. *J Nepal Health Res Counc* 2018;**16**:297–301
- 23 Faramarzi M, Atashi S, Edalatkhah M, Roosta S. The effect of anterior tab flap technique on graft success rate in large tympanic membrane perforation. *Eur Arch Otorhinolaryngol* 2021;**278**:1765–72
- 24 Govaerts PJ, Raemaekers J, Verlinden A, Kalai M, Somers T, Offeciers FE. Use of antibiotic prophylaxis in ear surgery. *Laryngoscope* 1998;**108**:107–10
- 25 Cheng H, Chen BP, Soleas IM, Ferko NC, Cameron CG, Hinoul P. Prolonged operative duration increases risk of surgical site infections: A systematic review. *Surg Infect (Larchmt)* 2017;**18**:722–35
- 26 Jackson CG. Antimicrobial prophylaxis in ear surgery. *Laryngoscope* 1988;**98**:1116–23
- 27 Ziylan F, Smeeing DPJ, Bezdjian A, Stegeman I, Thomeer HGXM. Feasibility of preservation of chorda tympani nerve during noninflammatory ear surgery: a systematic review. *Laryngoscope* 2018;**128**:1904–13
- 28 Takahashi M, Motegi M, Yamamoto K, Yamamoto Y, Kojima H. The pre-chorda and post-chorda tympani approach in endoscopic stapes surgery based on the chorda tympani nerve classification. *Eur Arch Otorhinolaryngol* 2022;**279**:5945–49