

## Does disorder of gastrointestinal motility affect food intake in the post-surgical patient?

BY T. E. BOWLING

*Department of Gastroenterology and Nutrition, Central Middlesex Hospital, London NW10 7NS*

Post-operative ileus (POI) is a predictable, self-terminating event which occurs after most general anaesthetic procedures. Paralytic ileus, on the other hand, is unpredictable, and can complicate a wide variety of medical and surgical conditions, such as pancreatitis, peritonitis, myocardial infarction, pneumonia, trauma and drug toxicity. Only if POI is prolonged is it termed a paralytic ileus. In both there is an acute and potentially reversible loss of motor function in the gastrointestinal tract. Clinically this leads to abdominal distension and pain, nausea and/or vomiting, loss of bowel sounds, and cessation of passage of flatus or stool. Because of the unpredictability of paralytic ileus it is virtually impossible to examine systematically the motor disturbances of the gastrointestinal tract. POI, however, is much more amenable to evaluation and has been studied in some detail. Whether the difference between POI and paralytic ileus is merely one of semantics or whether there are genuine differences of intestinal motor activity is still not known.

From a clinical standpoint, most clinicians do not consider that an ileus has resolved until bowel sounds reoccur and flatus is passed and, hence, feeding is not usually restarted until this has happened. This, however, is a somewhat crude assessment of returning intestinal function. Bowel sounds depend on luminal gas and the presence of intestinal motor activity, and take 1–3 d to reappear clinically (Clevers & Smout, 1989). Sensitive microphones attached to the anterior wall have detected bowel sounds, that could not be heard with a stethoscope, within a few hours of surgery (Wells *et al.* 1964). The passage of flatus follows the reappearance of bowel sounds and usually takes 2–3 d, with defaecation occurring at 4–5 d post-abdominal surgery (Clevers & Smout, 1989, Fig. 1). This often means that patients are not fed for several days after surgery. While this may be acceptable for the fit, well-nourished patient, it will compound malnutrition and increase the incidence of post-operative complications in those patients who are poorly nourished pre-operatively. In the present paper I will review what is known of the changes in gastrointestinal motor activity that are observed in POI, and illustrate why a delay in post-operative feeding may be unnecessary.

### MOTOR ACTIVITY CHANGES

#### *Stomach*

In a study by Nachlas *et al.* (1972), gastric emptying of barium was assessed both pre- and post-operatively in patients undergoing extra- and intra-abdominal surgery. Pre-operatively almost all the patients had emptied their stomachs of barium within 4 h; 24 h post-operatively, 38% of patients undergoing extra-abdominal surgery and 60% undergoing intra-abdominal surgery still had barium in their stomachs after 4 h. This study, therefore, demonstrated that gastric emptying is delayed for at least 24 h post-operatively in most patients. This has also been observed in other studies, both in

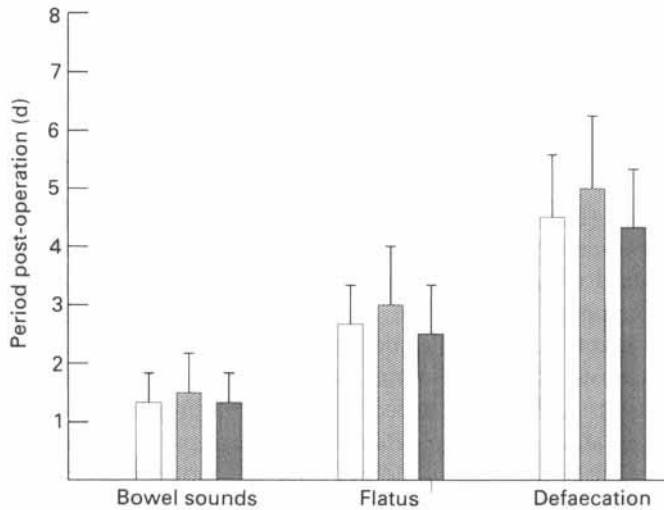


Fig. 1. Physical signs in patients following abdominal surgery; patients undergoing: (□), cholecystectomy; (▨), colonic surgery; (■), other laparotomies. Values are means and standard deviations represented by vertical bars. (Data from Clevers & Smout, 1989.)

animals (Dubois *et al.* 1973; Smith *et al.* 1977) and man (Rothnie *et al.* 1963; Wells *et al.* 1964).

If gastrograffin is placed in the stomach immediately post-operatively it collects in the fundus while the patient remains supine, but it flows freely into the duodenum if the patient is placed at an angle of 45° (Rothnie *et al.* 1963). This implies that the pylorus does not act as a physical barrier to the flow of gastric contents, and that delayed gastric emptying is likely to arise as a result of disordered motor activity.

The basal electrical, or pacemaker, activity of the stomach, normally three cycles/min, has been demonstrated as early as 12 h post-operatively (Coelho *et al.* 1990; Waldenhausen *et al.* 1990), but propagative activity is suppressed for at least 24 h in dogs (Smith *et al.* 1977) and man (Ingram & Catchpole, 1981; Waldenhausen *et al.* 1990). It is likely, therefore, that this disturbed propagation plays an important role in delaying gastric emptying post-operatively.

Normal gastric emptying is controlled by a combination of five factors: (a) fundal tone, (b) antral phasic activity, (c) pyloric diameter and tone, (d) duodenal tone, (e) the coordination of antral and duodenal phasic activity. Only studies referring to antral phasic activity have appeared in the literature and, hence, there is much more to be learned of the mechanisms of the delayed gastric emptying observed during POI.

#### *Small intestine*

Small-intestinal gas shadows are not usually seen post-operatively, but progressive colonic gas shadows are often seen in the first 48 h (Rothnie *et al.* 1963; Wells *et al.* 1964; Nachlas *et al.* 1972; Wilson, 1975). As intestinal gas is mainly derived from swallowed air, this would imply that there must be some kind of propulsive activity in the small

intestine. However, this transport of intraluminal gas does not necessarily imply that small-intestinal propagation is normal. Most studies of small-intestinal transit in POI have examined progression of barium or gastrograffin from the stomach to the colon, but much of the observed delay could be accountable to the delayed gastric emptying. Rothnie *et al.* (1963) placed barium capsules in the duodenum at surgery in six patients, and 24 h later the barium had reached the colon in all of the patients. This finding has been repeated in another study, where barium was put either into the stomach or into the duodenum of patients undergoing gastroduodenal surgery (Nachlas *et al.* 1972). Barium had reached the colon 24 h later in only 11% of those with barium placed intragastrically, and in 58% of those with barium placed intraduodenally, implying that small-intestinal transit recovers more rapidly than gastric emptying.

Small-intestinal transit is regarded as the return of phase III activity of the interdigestive migrating motor complex (MMC). There are conflicting reports of the timing of the return of phase III activity in man. Some have found an early return of activity (Catchpole & Duthie, 1978; Stoddard *et al.* 1978; Sarna, 1985; Waldenhausen *et al.* 1990; Benson *et al.* 1992), while others have found it to be markedly reduced or absent in the first 24 h (Dauchel *et al.* 1976; Soper *et al.* 1990; Schippers *et al.* 1991). The length of the surgery does not appear to be an important factor, but the type of surgery is likely to be of more relevance, with major colonic resections delaying the return of phase III activity longer than open cholecystectomies (Schippers *et al.* 1991). It is difficult, therefore, to reach a conclusion concerning the timing of returning phase III activity as these trials are studying varying types of surgery using different anaesthetic and analgesic agents.

The return of phase III activity does not necessarily imply normal propagation. It has been observed that MMC periodicity is shortened in the immediate post-operative period, gradually increasing to normal over 24–48 h (Schippers *et al.* 1991; Benson *et al.* 1993). Uncoordinated phase III activity has been recorded in the second and third post-operative days in dogs (Smith *et al.* 1977) and in the first 24 h in man (Stoddard *et al.* 1978; Benson *et al.* 1992). In addition, contractile amplitude is also significantly decreased for up to 72 h (Benson *et al.* 1992). The significance of these findings, however, has not been fully evaluated.

### Colon

There are virtually no studies examining colonic function in POI. Those available have demonstrated a suppression of motor activity in the proximal colon for at least 24 h (Wilson, 1975), and for 2–3 d in the distal colon (Condon *et al.* 1986; Roberts *et al.* 1993). The recordings in these studies, however, lasted for less than 3 h, which is insufficient to gain proper understanding of the motor responses in the post-operative situation.

### FACTORS AFFECTING DURATION OF POI

A full discussion of the aetiology of POI is inappropriate in this review and has been covered in detail elsewhere (Livingstone & Passaro, 1990), but there are a few points which are of particular relevance to the duration of POI. Surgery is both a psychological and a physiological stressor, and signals from the central nervous system undoubtedly affect the enteric nervous system and hence intestinal motor activity. How this influences POI, however, has not been addressed. The role of circulating catecholamines in POI is

also debated. Adrenalectomy does not alter the duration of ileus in dogs (Douglas *et al.* 1941; Dubois *et al.* 1974), and it is known that paralytic ileus is rare in patients with phaeochromocytomas (Cruz & Cowell, 1972). Some anaesthetic agents, such as halothane (Marshall *et al.* 1961; Condon *et al.* 1987) and enflurane (Condon *et al.* 1987), can also alter gastrointestinal motility, as can opiates used as pre-medication agents and/or as post-operative analgesics (Miller & Hirning, 1989). Clearly, therefore, there are many factors involved in POI which will influence the duration of the ileus.

#### MANAGEMENT OF POI

The standard management of POI is intravenous fluid replacement with or without nasogastric aspiration and/or nutritional support, until clinical resolution of the ileus. In the search for methods to shorten the duration of POI, many agents, including sympatholytics (Thorup *et al.* 1983), cholinomimetics (Heimbach & Crout, 1971), and electrical pacing (Barker *et al.* 1984), have been studied, generally with unsuccessful outcomes.

Cisapride, normally used as a pro-motility agent in the treatment of gastro-oesophageal reflux disease, when given intravenously has been shown to bring forward significantly the reoccurrence of flatus (Boghaert *et al.* 1987; Verlinden *et al.* 1987). When given throughout the post-operative period it can promote an earlier return of propulsive activity, as assessed by the movement of markers, in all regions of the colon (Tolleson *et al.* 1991) and an increase in left colonic pressure activity (Clevers *et al.* 1988) when compared with controls. Cisapride, given rectally, has been shown to prolong significantly the small-intestinal MMC periodicity and migration velocity in the immediate post-operative period compared with a control group, but there was no difference in the timing of the return of phase II activity or the clinical duration of POI between the two groups (Benson *et al.* 1993). The effect of cisapride on gastric activity in the post-operative situation has not yet been studied.

Ceruletide, which is pharmacodynamically similar to cholecystokinin, has brought about restoration of small-intestinal peristalsis within a few hours when infused 24 h post-operatively, but the response diminished rapidly after cessation of infusion (Montero *et al.* 1980). However, other trials have demonstrated a significant reduction in the duration of POI when ceruletide is given either intramuscularly (Madsen & Lykkegaard-Neilson, 1983) or intravenously (Sadek *et al.* 1988), allowing earlier resumption of oral alimentation. Fedotozine, a peripheral opioid agonist which stimulates gastrointestinal motility in animals (Pascaud *et al.* 1990) and man (Karaus *et al.* 1990), has recently been shown to reverse POI in rats by actions at peripheral K-opioid receptors (Riviere *et al.* 1993). No studies in man have been carried out.

Of considerable interest is the role of feeding in the treatment of POI. Early enteral feeding has been advocated on the basis that nutrition *per se*, by stimulating the gastrointestinal tract, might effect a decrease in the length of POI. In all trials to date, feeding has been directly into the duodenum or proximal jejunum within a few hours of surgery and, in general, patients have demonstrated good tolerance of the diets (Hoover *et al.* 1980; Bower *et al.* 1986). No one has studied the effects of post-operative intragastric feeding. Of these trials, only one has looked at the influence of post-operative feeding on gastrointestinal motor activity (Moss, 1981). In this trial full strength elemental diet was infused intraduodenally at 100–150 ml/h immediately

following colorectal excision in eighteen patients. Digestion and absorption of protein, as judged by urinary excretion of  $^{125}\text{I}$ -albumin incorporated into the diet, was within normal limits; and barium studies 24 h post-operatively showed prompt passage of barium from the stomach to the small and large intestines. The first bowel action occurred within 48 h of surgery in all patients, and the diet was well tolerated. There were, however, no control patients in this trial, and there have been no other studies to support or refute these findings.

#### SUMMARY

In summary, POI is a predictable event with actual return of bowel function preceding clinically detectable signs of function by at least 24 h. All parts of the gastrointestinal tract are affected, but small-intestinal function returns first, probably as early as 4–8 h after surgery in many cases. The timing of restarting feeding could be earlier than current practice would suggest, and because of the more rapid recovery of small-intestinal function it could be argued that post-pyloric feeding, at least in the first 24–48 h, may be preferable. While a policy of refeeding only when bowel function is clinically detectable is acceptable for many patients, there are certainly some who would benefit from feeding at an earlier stage. Parenteral feeding is expensive and a greater knowledge of the mechanisms underlying POI may lead clinicians to different and perhaps more appropriate methods of management.

#### REFERENCES

- Barker, P., Allcut, D. & McCollum, J. (1984). Pulsed electromagnetic energy fails to prevent postoperative ileus. *Journal of the Royal College of Surgeons of Edinburgh* **29**, 147–150.
- Benson, M. J., Roberts, J. P., Rogers, J., Deeks, J. J., Castillo, F. D., Williams, N. S. & Wingate, D. L. (1993). The effect of cisapride on postoperative small bowel motor activity. *Gastroenterology* **104**, A476.
- Benson, M. J., Roberts, J. P., Wingate, D. L., Rogers, J., Castillo, F. D. & Williams, N. S. (1992). Small bowel motility following major bowel surgery. *Gastroenterology* **102**, A424.
- Boghaert, A., Haesaert, G., Mourisse, P. & Verlinden, M. (1987). Placebo-controlled trial of cisapride in postoperative ileus. *Acta Anaesthesiologica Belgica* **38**, 195–199.
- Bower, R. H., Talamini, M. A., Sax, H. C., Hamilton, F. & Fischer, J. E. (1986). Postoperative enteral vs parenteral nutrition. *Archives of Surgery* **121**, 1040–1045.
- Catchpole, B. N. & Duthie, H. L. (1978). Postoperative gastrointestinal complexes. In *Gastrointestinal Motility in Health and Disease*, pp. 33–41 [H. L. Duthie, editor]. Lancaster: MTP Press Ltd.
- Clevers, G. J. & Smout, A. J. (1989). The natural course of postoperative ileus following abdominal surgery. *Netherlands Journal of Surgery* **41**, 97–99.
- Clevers, G. J., Smout, A. J., Akkermans, L. M. A. & Wittebol, P. (1988). Restoration of gastrointestinal transit and colonic motility after major abdominal surgery; effects of cisapride. *Surgery Research Communications* **4**, 205–213.
- Coelho, J. C. U., Pupo, C. A., Campos, A. C. L. & Moss, A. A. (1990). Electromyographic activity of the gastrointestinal tract following cholecystectomy. *World Journal of Surgery* **14**, 523–528.
- Condon, R. E., Cowles, V. E., Ekboum, G. A., Schulte, W. J. & Hess, G. (1987). Effects of halothane, enflurane, and nitrous oxide on colonic motility. *Surgery* **101**, 81–85.
- Condon, R. E., Cowles, V. E., Schulte, W. J., Frantzides, C. T., Mahoney, J. L. & Sarna, S. K. (1986). Resolution of postoperative ileus in humans. *Annals of Surgery* **203**, 574–581.
- Cruz, S. R. & Cowell, L. J. A. (1972). Pheochromocytoma and ileus. *Journal of the American Medical Association* **219**, 155–158.
- Dauchel, J., Schang, J. C., Kachelhoffer, J., Eloy, R. & Grehier, J. F. (1976). Gastrointestinal myoelectric activity during post-operative period in man. *Digestion* **14**, 293–303.

- Douglas, D. M., Henry, D. P. & Kopin, I. J. (1941). The effect of peritoneal irritation on the activity of the intestine. *British Medical Journal* **15**, 277–281.
- Dubois, A., Kopin, I. J., Pettigrew, K. D. & Jacobowitz, D. M. (1974). Chemical and histochemical studies of post-operative sympathetic activity in the digestive tract in rats. *Gastroenterology* **66**, 403–407.
- Dubois, A., Weise, V. K. & Kopin, I. J. (1973). Postoperative ileus in the rat: physiopathology, etiology and treatment. *Annals of Surgery* **178**, 781–786.
- Heimbach, D. M. & Crout, J. R. (1971). Treatment of paralytic ileus with adrenergic neuronal blocking drugs. *Surgery* **69**, 582–587.
- Hoover, H. C., Ryan, J. A., Anderson, E. J. & Fischer, J. E. (1980). Nutritional benefits of immediate postoperative jejunal feeding of an elemental diet. *American Journal of Surgery* **139**, 153–159.
- Ingram, D. M. & Catchpole, B. N. (1981). Effect of opiates on gastroduodenal motility following surgical operation. *Digestive Diseases and Sciences* **26**, 989–992.
- Karaus, M., Kittelman, R., Lubke, H. J. & Erckenbrecht, J. R. (1990). Selective stimulation of phase 3 activity by fedotozine (JO 1196) in men. *Gastroenterology* **98**, A364.
- Livingstone, E. H. & Passaro, E. P. (1990). Postoperative ileus. *Digestive Diseases and Sciences* **35**, 121–132.
- Madsen, P. V. & Lykkegaard-Neilson, M. (1983). Ceruletide reduces postoperative intestinal paralysis: a double-blind placebo-controlled trial. *Diseases of the Colon and Rectum* **26**, 159–160.
- Marshall, F. N., Pittinger, C. B. & Long, J. P. (1961). Effects of halothane on gastrointestinal motility. *Anesthesiology* **22**, 363–366.
- Miller, R. J. & Hirning, L. D. (1989). Opioid peptides and the gut. In *Handbook of Physiology: Section IV: The Gastrointestinal System*, vol. 2, pp. 631–660 [S. G. Schultz, editor]. Bethesda: American Physiological Society.
- Montero, V. F., Laganga, A. M. & Garcia, E. A. (1980). Usefulness of caerulein in the treatment of postoperative intestinal atony. *Journal of International Medical Research* **8**, 98–104.
- Moss, G. (1981). Maintenance of gastrointestinal function after bowel surgery and immediate enteral full nutrition. II. Clinical experience, with objective demonstration of intestinal absorption and motility. *Journal of Parenteral and Enteral Nutrition* **5**, 215–220.
- Nachlas, M. M., Younis, M. T., Pio Roda, C. & Wityk, J. J. (1972). Gastrointestinal motility studies as a guide to postoperative management. *Annals of Surgery* **175**, 510–522.
- Pascaud, X., Honde, C., Le Gallou, B., Chanoine, F., Roman, F., Bueno, L. & Junien, J. L. (1990). Effects of fedotozine on gastrointestinal motility in dogs: mechanism of action and related pharmacokinetics. *Journal of Pharmacy and Pharmacology* **42**, 546–552.
- Riviere, P. J., Pascaud, X., Chevalier, E., Le Gallou, B. & Junien, J. (1993). Fedotozine reverses ileus induced by surgery or peritonitis: action at peripheral K-opioid receptors. *Gastroenterology* **104**, 724–731.
- Roberts, J. P., Benson, M. J., Rogers, J., Deeks, J. J., Wingate, D. L. & Williams, N. S. (1993). Distal colonic motility and postoperative ileus: the effect of recto-sigmoid anastomosis. *Gastroenterology* **104**, A571.
- Rothnie, N. G., Harper, R. A. & Catchpole, B. N. (1963). Early post-operative gastrointestinal activity. *Lancet* **ii**, 64–67.
- Sadek, S. A., Cranford, C., Eriksen, C., Walker, M., Campbell, C., Baker, P. R., Woods, R. A. B. & Cuschieri, A. (1988). Pharmacological manipulation of adynamic ileus: controlled randomised double-blind trial study of ceruletide on intestinal motor activity after elective abdominal surgery. *Alimentary Pharmacology and Therapeutics* **2**, 47–54.
- Sarna, S. K. (1985). Cyclic motor activity: migrating motor complex. *Gastroenterology* **89**, 894–913.
- Schippers, E., Holscher, A. H., Bollschweiler, E. & Siewert, J. R. (1991). Return of the inter-digestive motor complex after abdominal surgery: end of postoperative ileus? *Digestive Diseases and Sciences* **36**, 621–626.
- Smith, J., Kelly, K. & Weinshilboum, R. M. (1977). Pathophysiology of postoperative ileus. *Archives of Surgery* **122**, 203–209.
- Soper, N. J., Sarr, M. G. & Kelly, K. A. (1990). Human duodenal myoelectric activity after operation and with pacing. *Surgery* **107**, 63–68.
- Stoddard, C. J., Smallwood, R. H. & Duthie, H. L. (1978). Migrating myoelectric complexes in man. In *Gastrointestinal Motility in Health and Disease*, pp. 9–15 [H. L. Duthie, editor]. Lancaster: MTP Press Ltd.
- Thorup, J., Wille-Jorgensen, T., Jorgensen, T. & Kjaergaard, J. (1983). Dihydroergotamine in post-operative ileus. *Clinical Pharmacology and Therapeutics* **34**, 54–55.
- Tolleson, P. O., Cassuto, J., Rimback, G., Faxen, A., Bergman, L. & Mattsson, E. (1991). Treatment of postoperative paralytic ileus with cisapride. *Scandinavian Journal of Gastroenterology* **26**, 477–482.
- Verlinden, M., Michiels, G., Boghaert, A., de Coster, M. & Dehertog, P. (1987). Treatment of postoperative gastrointestinal atony. *British Journal of Surgery* **74**, 614–617.

- Waldenhausen, J. H. T., Shaffrey, M. E., Skenderis, B. S., Jones, R. S. & Schirmer, B. D. (1990). Gastrointestinal myoelectric and clinical patterns of recovery after laparotomy. *Annals of Surgery* **211**, 777–784.
- Wells, C., Tinkler, L., Rawlinson, K., Jones, H. & Saunders, J. (1964). Post-operative gastrointestinal motility. *Lancet* **1**, 4.
- Wilson, J. P. (1975). Postoperative motility of the large intestine in man. *Gut* **16**, 689–692.