

# X-Linked Hydrocephalus

Ruben I. Kuzniecky, Gordon V. Watters, Lise Watters  
and Kathleen Meagher-Villemure

**ABSTRACT:** Two French-Canadian families with seven cases of hydrocephalus in two generations are presented. The pattern of inheritance is consistent with an X-linked recessive transmission. The clinical and pathologic characteristics of this entity are reviewed. The anomaly of adducted thumbs was present in one patient and its cause is considered. The hypothesis of primary hydrocephalus and secondary compression of the aqueduct as the mechanism for aqueductal stenosis is discussed.

**RÉSUMÉ:** L'hydrocéphalie liée au chromosome X Deux familles canadiennes-françaises avec sept cas d'hydrocéphalie sur deux générations sont présentées. Le mode d'hérédité est compatible avec une transmission récessive liée au chromosome X. Les auteurs font une revue des caractéristiques cliniques et pathologiques de cette entité. Un patient présentait des pouces en adduction et la cause de cette anomalie est examinée. L'hypothèse d'une hydrocéphalie primaire et d'une compression secondaire de l'aqueduc comme mécanisme de production de la sténose de l'aqueduc est discutée.

*Can. J. Neurol. Sci.* 1986; 13:344-346

Congenital hydrocephalus is commonly associated with neural tube defects, most often with spina bifida and meningo-myelocele. According to Shannon and Nadler<sup>1</sup> the incidence of this entity varies between 0.9 to 1.8 per 1000 births. The etiologies are varied including genetic and acquired forms. Different mechanisms are involved in the pathogenesis. Genetic forms of neonatal hydrocephalus have been described in the Dandy-Walker malformation and in an X-linked entity associated with cerebellar agenesis.<sup>2</sup> Among these forms, familial aqueductal stenosis is probably the most common type with inheritance as an X-linked recessive.<sup>3</sup>

The purpose of this paper is to report two families with seven cases of hereditary X-linked hydrocephalus with probable aqueductal stenosis.

## CASE REPORTS

### Family I (Figure 1)

This French-Canadian family originates from a small town southwest of Montreal. The family has four affected males in two generations.

**Case 1 (III4)** Birth date 57/11/03: This boy was born after an uneventful pregnancy. Birth weight was 4791 grams. Caesarian section was done for cephalopelvic disproportion. The child was hydrocephalic at birth. He died at 48 hours. No autopsy was performed.

**Case 2 (III6)** Birth date 59/08/07: This boy was born after a normal pregnancy. Birth weight was 5245 grams. A Caesarian section was done for cephalopelvic disproportion. The head circumference at birth was 57.5 cm (normal 34 cm) with a striking degree of hydrocephalus. The child died at 45 days of age. No autopsy was done.

**Case 3 (III8)** Birth date 62/03/23: This boy was born after a normal pregnancy. The birth weight was 4337 grams. A Caesarian section was done because of hydrocephalus. The head circumference was 47.5 at birth. A ventriculogram showed aqueductal stenosis. The child died at 42 days of age. No autopsy was performed.

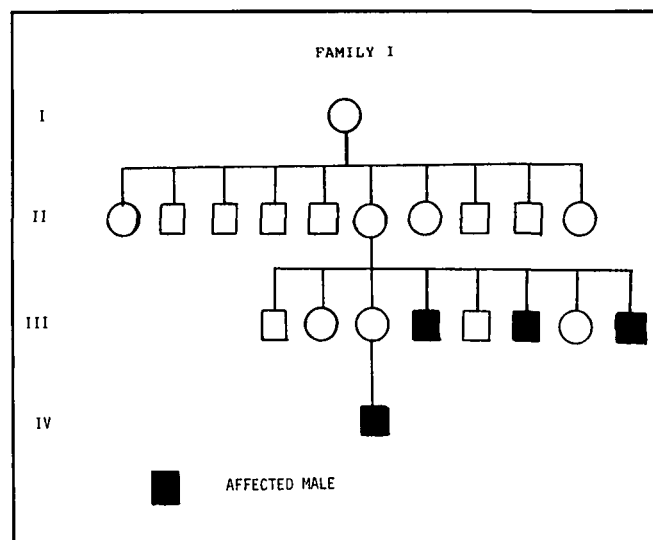


Figure 1 — Pedigree of Family I. Patient IV1 is presently alive.

**Case 4 (IV1)** Birth date 82/07/13: This boy was born at 41 weeks gestation after a normal pregnancy. Caesarian section was done for hydrocephalus diagnosed by ultrasound *in utero*. He weighed 4082

grams and his head circumference at birth was 42 cms. Cranial computerized tomography showed dilatation of the lateral and third ventricles. At birth, the patient was noted to have both thumbs flexed across the palms and also there were wide spaces between the first and second toes. Because of constipation, a rectal biopsy was done at two weeks of age and was consistent with Hirschsprung's disease. A ventriculoperitoneal shunt was inserted but the patient remained severely handicapped. At three years of age he has severe neurological deficits.

#### Family II (Figure 2)

This French-Canadian family originates from a village adjacent to that of family I. This family has three affected males in two generations, and there is evidence that the infant who died (II3) may have had hydrocephalus at birth. Parish records showed no relationship with family I.

**Case 1 (III4)** Birth date 49/05/16: This boy was born after a normal pregnancy by forceps delivery. He was described as hydrocephalic and hypotonic at birth. He died on the first day of life. No autopsy was done.

**Case 2 (III6)** Birth date 56/08/06: This boy was born after a normal pregnancy. He was hydrocephalic at birth. No associated malformations were documented. He died at 18 days of age. No autopsy was performed.

**Case 3 (IVI)** Birth date 84/12/31: This boy was born at 34 weeks gestation after hydrocephalus was diagnosed *in utero* by ultrasound. At birth his head circumference was 41 cm (mean for gestational age: 31 cm). No associated malformations were documented. Cranial ultrasound diagnosed hydrocephalus with aqueductal stenosis. The patient had a ventriculoperitoneal shunt installed, but he died of sepsis at four days of age.

On postmortem examination there were no extracranial anomalies. The brain weighed 235 grams (normal: 275 grams). On examination of the cerebrum there was marked dilatation of the lateral and third ventricles with attenuated cortex and white matter. The basal ganglia and thalamus were normal. In the brainstem the aqueduct was not visible and the cerebellum was normal. Sections from the aqueduct showed that the aqueduct was linear and stenotic throughout, but more stenotic at the level of the anterior portion. On cross section it measured approximately 0.15 mm and had a normal ependymal lining. There was no evidence of gliosis or forking. (Figure 3)

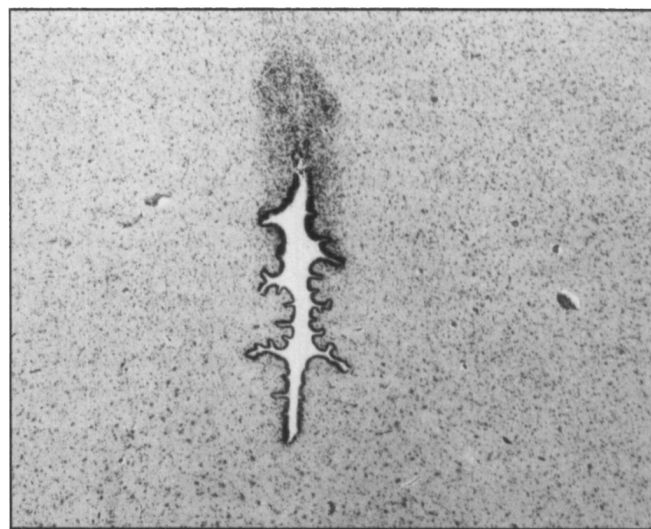


Figure 3 — Section through the inferior portion of the Aqueduct, showing stenosis with a normal ependymal lining. (magnification x 50)

patients had X-linked hydrocephalus of the type reported by others and whether they should all therefore be considered as examples of this entity.

In our two families the hydrocephalus was inherited as an X-linked recessive trait. In contrast to Edwards cases, all the children but one were severely affected and died within two months. The only child who is still alive shows the abnormal palmar thumbs previously described in some of the other families with X-linked hydrocephalus.<sup>5</sup>

Considerable debate persists concerning the abnormal position of the thumbs in X-linked hydrocephalus. Although Edwards<sup>5</sup> described it as a cardinal manifestation of this entity, it is only reported in 17% to 25% of cases of X-linked hydrocephalus.<sup>6</sup> Moreover, there are other syndromes in which palmar thumbs are also seen without hydrocephalus. Weckesser et al<sup>7</sup> have described a number of cases of sex-linked clasped thumbs without other abnormalities. We have studied a patient with X-linked familial agenesis of corpus callosum and no hydrocephalus who had clasped thumbs and, curiously, also had Hirschsprung's disease. Although some authors are of the opinion that the abnormal position of the thumbs is due to corticospinal tract lesions,<sup>8</sup> there is evidence that an alternative mechanism may be an X-linked mediated agenesis of the abductor and extensor muscles of the thumb.<sup>9</sup> This has been confirmed by direct exploration and by electromyographic studies in several patients with X-linked hydrocephalus.<sup>7</sup> Thus, although adducted thumbs may be due to corticospinal tract involvement induced by the hydrocephalus it may also be considered a possible concomitant anomaly in patients with X-linked hydrocephalus when other clinical and electrophysiological abnormalities are present.

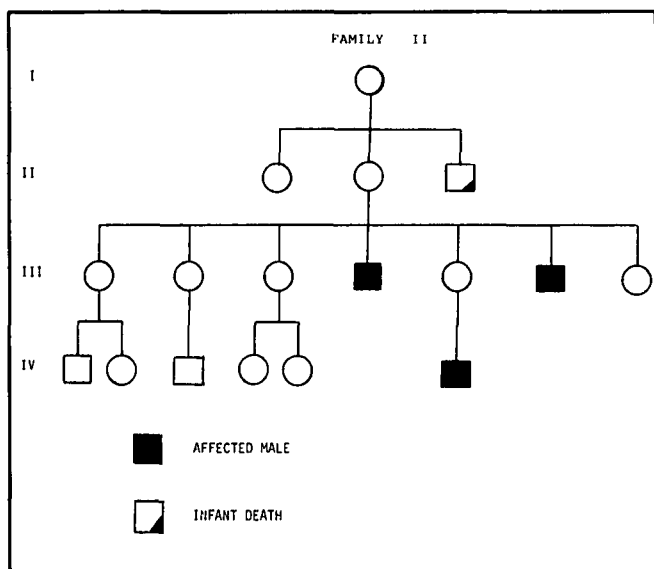


Figure 2 — Pedigree of Family II.

#### DISCUSSION

The first well documented case of X-linked recessive hydrocephalus and aqueductal stenosis was reported by Bickers and Adams in 1949.<sup>4</sup> Since their original description, another twenty families have been reported with full details, including genetic and pathologic studies.

Severe narrowing of the aqueduct is usually associated with hydrocephalus. In reported cases, the aqueduct has been described as narrow, especially in the region anterior to the ampulla, with a mean measurement of only 0.25 mm in comparison to a control of 1 mm. The ependymal lining remains normal without evidence of gliosis or forking. These findings have been grouped under the term "simple stenosis", although additional findings such as fusion of the corpora quadrigemina have been described by Sovik et al.<sup>8</sup>

Controversy arises regarding the pathogenesis of the hydrocephalus which occurs in patients with X-linked aqueductal stenosis. Many authors have assumed that the hydrocephalus is secondary to aqueductal stenosis. However, there is strong morphological evidence from animal models of inherited hydrocephalus that the temporal sequence of events is communicating hydrocephalus followed by aqueductal stenosis.<sup>9,10</sup> The aqueducts in these animals are compressed by the expanding lateral ventricles of the cerebral hemispheres. As Williams<sup>11</sup> has pointed out, "if the stenosis were truly the cause of the hydrocephalus it should be expected that no hydrocephalus would be found until stenosis is severe or complete". While in most reported autopsies the aqueduct was stenotic, Landrieu et al<sup>9</sup> have reported one case of X-linked hydrocephalus where no aqueductal stenosis was found on autopsy, substantiating William's proposal.

The relative frequency of X-linked hydrocephalus is difficult to estimate. It represents approximately 2% of all cases of isolated congenital hydrocephalus. Burton<sup>14</sup> studied 205 cases of congenital hydrocephalus without associated malformations and found that 43% had aqueductal stenosis. The estimated recurrence rate among male siblings was 12%. Further, if all cases of arrested hydrocephalus and/or stillborn infants were to be included then the frequency would be higher than the one obtained.

Because congenital hydrocephalus can be due to acquired forms (tumors, postinflammatory fibrosis, malformations) or genetic forms (Dandy-Walker syndrome, X-linked aqueductal stenosis, atresia of foramen of Magendie), the problem of genetic counselling is complex. Thus, in the child with congenital hydrocephalus, investigations must first be carried out to define its type, which will aid in establishing its possible mode of inheritance. In X-linked cases, the sex of the proband and the pathological findings remain the most important factors for genetic counselling, despite the fact that aqueductal stenosis may not be present at autopsy.

In counselling families who have had a child with congenital hydrocephalus all the above factors must be taken into account. Evidence for other causes of hydrocephalus such as infection must be sought in the affected infant and a careful history of

that pregnancy obtained in regards to maternal exposure and illness. During pregnancy high resolution Ultrasonography should be performed to exclude ventricular dilatation or spinal abnormalities.<sup>15</sup> Serum alpha-fetoprotein determination should be carried out to determine if the fetus is at risk for spina bifida since there is evidence that uncomplicated hydrocephalus in one infant may increase the risk of dysraphic states in subsequent pregnancies.<sup>15</sup> In cases of X-linked aqueductal stenosis the sex of the fetus may be determined by amniocentesis or chorionic villous biopsy if it is intended to terminate a potentially affected male fetus.

#### ACKNOWLEDGEMENT

We wish to thank Yvonne Zelenka for her criticism and assistance during the preparation of the manuscript.

#### REFERENCES

1. Shannon MH, Nadler HL. X-Linked hydrocephalus. *J Med Genet*, 1968; 5: 326-328.
2. Ricciardi VM, Marcus ES. Congenital hydrocephalus and cerebellar agenesis. *Clin Genet*, 1978; 13: 433-447.
3. McMillan P, Williams B. Aqueductal stenosis: case review and discussion. *J Neur, Neurosurg, Psych*. 1977; 40: 521-532.
4. Bickers DS, Adams RD. Hereditary stenosis of the aqueduct of sylvius as a cause of congenital hydrocephalus. *Brain*, 1949; 72: 246-262.
5. Edwards JH. The syndrome of x-linked hydrocephalus. *Arch Dis Child*. 1961; 36: 486-493.
6. Jansen J. Sex linked hydrocephalus. *Devel Med and Child Neurology*. 1975; 17: 633-640.
7. Weckesser E, Reed S, Heiple K. Congenital clasped thumbs — a syndrome, not a specific entity. *Journal of Bone and Joint Surgery*. 1968; 50A: 1417.
8. Yakovlev P. Paraplegias of hydrocephalics. *American Journal of Mental deficiency*. 1947; 51: 561.
9. Landrieu P, Ninane J, Ferriere G et al. Aqueductal stenosis in x-linked hydrocephalus: a secondary phenomenon? *Devel Med and Child Neurology*, 1979; 21: 637-641.
10. Sovik O, Van Der Hagen C, Loken A. X-Linked aqueductal stenosis. *Clinical Genetics*, 1977; 11: 416-420.
11. Borit A, Sidman RL. New mutant mouse with communicating hydrocephalus and secondary aqueductal stenosis. *Acta Neuropathol*, 1972; 21: 316-331.
12. Raimondi AJ, Clark SJ, McLone DG. Pathogenesis of aqueductal occlusion in congenital murine hydrocephalus. *J Neurosurgery*. 1976; 45: 66-67.
13. Williams B. Is aqueductal stenosis a result of hydrocephalus? *Brain* 1977; 96: 399-412.
14. Burton B. Recurrence risks for congenital hydrocephalus. *Clinical Genetics*, 1979; 16: 47-53.
15. Hobbins JC, Grannum PA. Ultrasound in the diagnosis of congenital anomalies. *Am J Obstet Gynecol* 1979; 134: 331.
16. Lorber J. The family history of simple congenital hydrocephalus: An epidemiologist study based on 270 probands. *Z. Kinderchir* 1984, Supplement II, 94-95.