

Lipid therapy for the treatment of a refractory amitriptyline overdose

Mathew B. Kiberd, BSc*; Samuel F. Minor, MD*†

ABSTRACT

Tricyclic antidepressant (TCA) overdose is a leading cause of death among intentional overdoses. Intravenous lipid emulsion therapy is an emerging antidote for local anesthetic toxicity, and there is animal evidence that lipid therapy may be efficacious in TCA overdose. Furthermore, case reports in humans have described the use of lipid therapy to reverse the toxicity of other lipophilic drugs. Here we report a 25-year-old female presenting with coma and hemodynamic instability following intentional ingestion of amitriptyline. She had multiple episodes of pulseless wide-complex tachycardia despite conventional treatment with chest compressions, cardioversion, lidocaine, epinephrine, norepinephrine, magnesium sulphate, sodium bicarbonate, activated charcoal, and whole bowel irrigation. Twenty percent lipid emulsion was administered intravenously (an initial 150 mL bolus, followed by an infusion at 16 mL/h and a second bolus of 40 mL) over 39 hours (total dose 814 mL) yet resulted in no dramatic changes in hemodynamics or level of consciousness. However, there was a decrease in the frequency of wide-complex tachycardia during the lipid emulsion infusion and a recurrence of wide-complex tachycardia shortly after the infusion was stopped. The patient was discharged from the intensive care unit 11 days later with no lasting physiologic sequelae.

Keywords: amitriptyline, intravenous fat emulsions, tricyclic antidepressive agents

Tricyclic antidepressant (TCA) overdose is an important cause of mortality following intentional overdose despite timely and aggressive treatment.¹ Intravenous lipid emulsion therapy is an exciting new treatment for lipophilic drug overdoses. Lipid therapy is widely advocated for local anesthetic toxicity² and is increasingly reported in the literature for overdoses of other

pharmaceuticals.²⁻¹³ We report the use of lipid therapy in a case of refractory pulseless wide-complex tachycardia resulting from an amitriptyline overdose.

CASE REPORT

A 50 kg, 25-year-old female was discovered unconscious in her house near several empty bottles of amitriptyline. The patient had a history of anorexia and depression and had stockpiled multiple amitriptyline prescriptions from different physicians specifically for the purpose of committing suicide. The total number and dose were not recorded, and there were possible coingestions of her regular medications, which included fluoxetine, escitalopram, olanzapine, quetiapine, and gabapentin. Paramedics found her to be unresponsive with a Glasgow Coma Scale score of 3, a heart rate of 60 beats/min, a wide QRS (186 ms), and a blood pressure of 60 mm Hg systolic. She was intubated without sedation and taken to the emergency department (ED).

In the ED, the patient went into a pulseless wide-complex tachycardia three times over the next 2 hours. Each episode was treated with chest compressions, synchronized cardioversion, lidocaine, and epinephrine. After cardioversion, the patient reverted to sinus rhythm with a wide QRS duration and a prolonged Q-Tc interval (Figure 1). A norepinephrine infusion was begun for hypotension, and she received 2 g magnesium sulphate, 350 mL 8.4% sodium bicarbonate, 50 g activated charcoal, and 4 L polyethylene glycol-3350 (GoLYTLEY) over 2 hours.

From the Departments of *Medicine and †Surgery, Dalhousie University, Halifax, NS.

Correspondence to: Dr. Samuel F. Minor, Department of Medicine, Dalhousie University, Rm 813 Victoria Bldg, 1278 Tower Road, Halifax, NS B3H 2Y9.

Submitted July 29, 2010; Revised January 30, 2011; Accepted March 4, 2011.

This article has been peer reviewed.

© Canadian Association of Emergency Physicians

CJEM 2012;14(3):193-197

DOI 10.2310/8000.2011.110486

DECKER



CJEM • JCMU

2012;14(3) 193

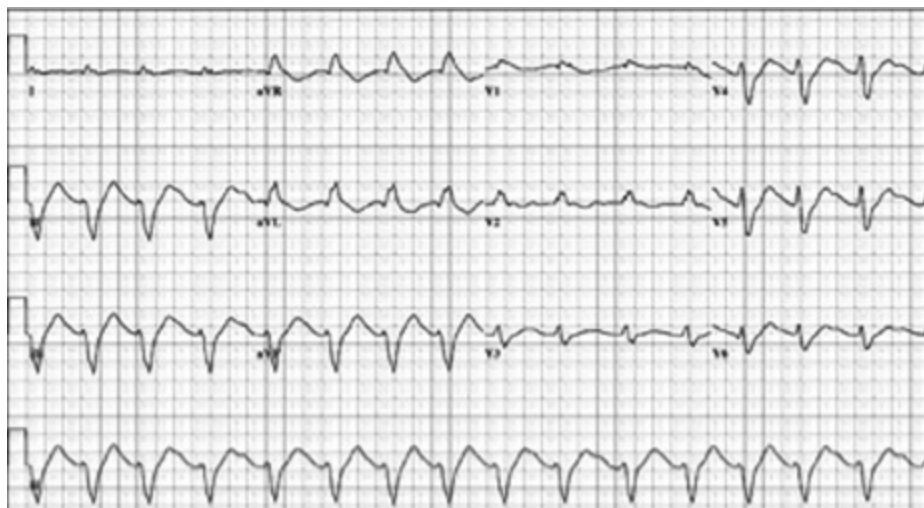

Figure 1. EKG demonstrating wide QRS and prolonged Q-Tc.

On arrival at the intensive care unit (ICU), the patient had lactate 7.6 mmol/L, pH 7.66, sodium 150 mmol/L, and potassium 3.0 mmol/L. She required a low-dose norepinephrine infusion intermittently for a target mean arterial pressure > 65 mm Hg, but after the initial resuscitation, hypotension was not a dominant feature. A sodium bicarbonate infusion was used for a target pH > 7.5, and the hypokalemia and hypocalcemia were treated. Over the next hour, the patient had three further episodes of pulseless wide-complex tachycardia, which were treated with synchronized cardioversion and each time reverted to a wide-complex sinus rhythm with a prolonged Q-Tc interval.

Given that the patient continued to have episodes of wide-complex tachycardia with traditional therapy, other treatment options were explored. A literature search found an animal model where lipid therapy reversed the toxicity from clomipramine, another TCA.¹¹ Also, two case reports of lipid therapy reversing the toxicity of other lipophilic drug overdoses were found.^{12,13} Based on this literature, the patient was administered a 150 mL bolus of 20% lipid (Intralipid, Baxter, Deerfield, IL). Although the intended dose of 20% lipid was 100 mL (2 mL/kg), another 50 mL was given by nursing error. After the initial bolus of lipid, there was no change in the QRS duration, blood pressure, or Glasgow Coma Scale score. Despite this apparent lack of effect, the patient was started on a continuous infusion of 20% lipid at 16 mL/h because of the long half-life of the ingested drugs. We selected a familiar and safe dose of 16 mL/h derived from typical dosing used during total parenteral nutrition

feeding. Given that it was not apparent that the lipid emulsion had any positive effect, we were concerned that a more aggressive prolonged infusion could cause toxicity. This infusion dose was substantially lower than the 0.25 mL/kg/min commonly recommended for reversal of local anesthetic toxicity, typically administered over less than an hour. Although there was no appreciable change in conduction intervals after administration of the lipid, the patient did have a relatively stable cardiac rhythm. After 3 hours, the patient had another episode of pulseless wide-complex tachycardia, which was converted into a stable wide-complex normal sinus rhythm with synchronized cardioversion, followed by another 40 mL bolus of 20% lipid, 20 mmol potassium chloride (for a potassium of 3.1 mmol/L), and 1g calcium chloride (for a calcium of 1.82 mmol/L). Figure 2 summarizes the treatment and timing of wide-complex tachycardia treated with electrical cardioversion.

For the next 36 hours, the patient received an infusion of 20% lipid at 16 mL/h, 3% hypertonic saline, and sodium bicarbonate. During this interval, there were no further episodes of wide-complex tachycardia, despite a QRS duration of 120 to 240 ms and a Q-Tc interval of 511 to 661 ms. Fifty millilitres of sodium bicarbonate was administered whenever the QRS duration lengthened to more than 120 ms, and the QRS duration consistently narrowed following each bolus.

After 36 hours, the intravenous lipid emulsion infusion was discontinued. Over 36 hours, our patient had received a total of 814 mL of 20% lipid (i.e., 16.3 mL/kg or 3.3 g of fat/kg body weight). Three

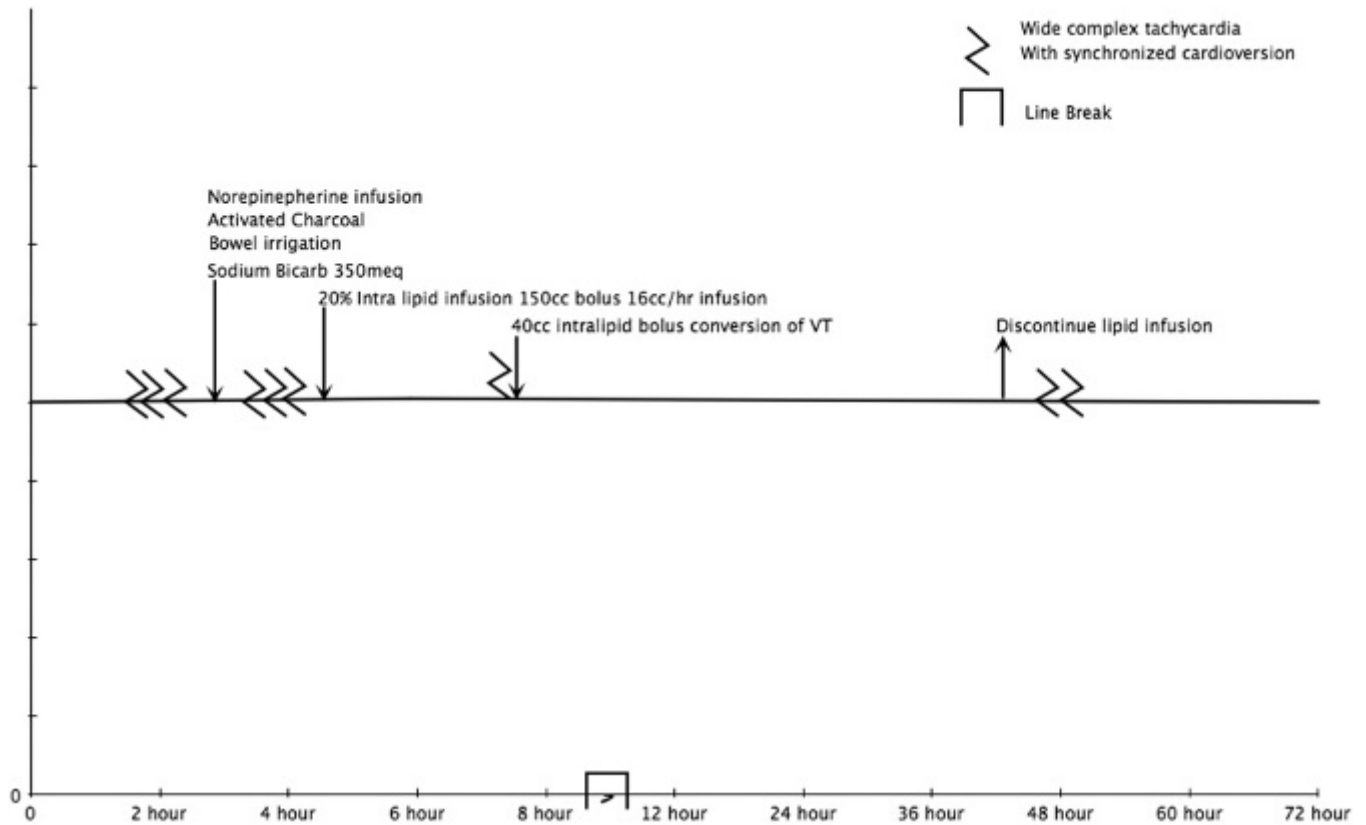


Figure 2. Summary of the treatment and timing of wide-complex tachycardia treated with electrical cardioversion.

hours after discontinuing the lipid infusion, the QRS duration widened again. There was no change in the sodium or pH targets, and the patient had a normal potassium. The patient became progressively hypotensive and again developed pulseless wide-complex tachycardia requiring synchronized electrical cardioversion. A 100 mg bolus of lidocaine was administered, but lipid therapy was not restarted. One and a half hours later, the patient had yet another episode of pulseless, wide-complex tachycardia requiring synchronized electrical cardioversion and again was successfully converted into a normal sinus rhythm.

After this, the patient had no further episodes of arrhythmia or hypotension. For the next 72 hours, she continued to have a prolonged QRS duration and prolonged QTc interval requiring intermittent treatment with sodium bicarbonate until day 8 postadmission. The patient was discharged from hospital with no physiologic or gross neurologic compromise.

DISCUSSION

Although intentional TCA overdose carries only a 3% mortality rate, it represents a leading cause of ICU

admission and in-hospital death among all intentional overdoses.¹⁴ The current mainstay of therapy is sodium bicarbonate, which treats the wide-complex ventricular arrhythmias and hypotension that characteristically develop. Vasopressors, gastrointestinal decontamination, antiarrhythmic therapy, electrical cardioversion, and antiseizure medications are often used in the management of TCA overdose,¹⁵ yet such overdoses may be refractory to therapy.²⁵

The role of intravenous lipid emulsion therapy in refractory TCA overdose is uncertain, reflecting uncertainty in the mechanism of action and clinical effectiveness of this new antidote as its use is extrapolated beyond cases of local anesthetic toxicity. As a class, TCAs are generally highly lipophilic and could be sequestered in the “lipid sink” created by the lipid infusion.^{3,5,9,11,16–19} Animal studies and human case reports describe the use of lipid emulsion in the treatment of clomipramine (a TCA), verapamil, propranolol, bupropion/lamotrigine, and quetiapine/sertraline.^{11–13,20–22}

When our patient demonstrated repeated episodes of wide-complex tachycardia despite conventional therapy, we felt that we had to explore nonconventional

therapies. Unfortunately, we did not observe a convincing change in end-organ toxicity following each bolus of lipid emulsion, as measured by QRS duration or level of consciousness.

However, the patient's cardiac rhythm was more stable during the lipid emulsion infusion, as indicated by the frequency of pulseless wide-complex tachycardia both during and immediately after discontinuation of the infusion. Recurrence of toxicity after cessation of lipid therapy has also been described in bupivacaine overdose.²⁵

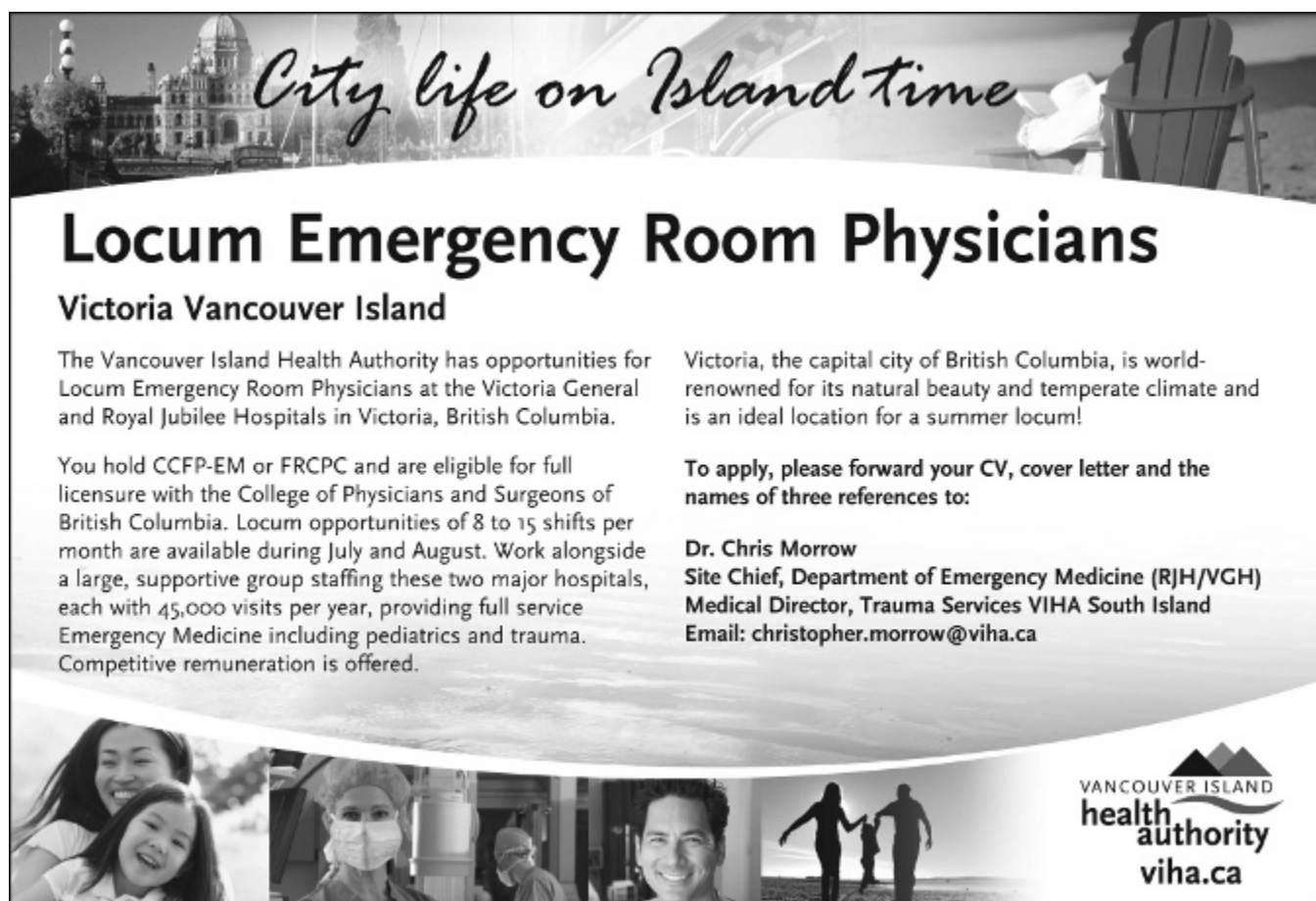
We used a relatively low rate of lipid infusion, which may have been insufficient to reverse the toxicity in this severe overdose. Nevertheless, dosing infusion rates and end points commonly recommended for local anesthetic toxicity following inadvertent intravascular penetration (e.g., 0.25 mL/kg/min for 30 to 60 minutes, with repeat boluses of 1.5 mL/kg every 3 to 5 minutes, to a maximum of 8 mL/kg, of 20% lipid) appear inappropriately short and intense for treating oral overdoses, many of which need prolonged therapy over many hours to days. We did not independently verify or attempt to quantify the exposure to amitriptyline in our case. Our patient also had possible coingestions of a variety of other medications that may have modified the effect of the lipid emulsion or contributed to cardiac toxicity. Although TCAs as a class share many common features, it is likely that differences in partition coefficients and perhaps other important properties render lipid therapy more or less effective for any given TCA, such as amitriptyline or clomipramine. Finally, we are unable to estimate the indirect effects of lipid emulsion in reducing the therapeutic efficacy of medications used during the resuscitation (e.g., lidocaine). Given our observations, and the inevitable effects of publication bias that inflate the efficacy of any new therapy, this case should moderate the clinician's expectations for the effectiveness of this therapy. Our case would suggest that TCA toxicity is not substantially reversed at the dose used.

Competing interests: None declared.

REFERENCES

1. Bebarta VS, Waksman JC. Amitriptyline-induced brugada pattern fails to respond to sodium bicarbonate. *Clin Toxicol (Phila)* 2007;45:186-8, doi:10.1080/15563650600981186.
2. Picard J, Ward SC, Zumpe R, et al. Guidelines and the adoption of 'lipid rescue' therapy for local anaesthetic toxicity. *Anaesthesia* 2009;64:122-5, doi:10.1111/j.1365-2044.2008.05816.x.
3. Cave G, Harvey M. Lipid emulsion therapy in lipophilic drug toxicity. *Ann Emerg Med* 2008;51:449-50; author reply 450, doi:10.1016/j.annemergmed.2007.10.014.
4. Cave G, Harvey MG, Castle CD. Intralipid ameliorates thiopentone induced respiratory depression in rats: investigative pilot study. *Emerg Med Australas* 2005;17:180-1, doi:10.1111/j.1742-6723.2005.00714.x.
5. Corman SL, Skledar SJ. Use of lipid emulsion to reverse local anesthetic-induced toxicity. *Ann Pharmacother* 2007;41:1873-7, doi:10.1345/aph.1K244.
6. Picard J, Harrop-Griffiths W. Lipid emulsion to treat drug overdose: past, present and future. *Anaesthesia* 2009;64:119-21, doi:10.1111/j.1365-2044.2008.05830.x.
7. Picard J, Meek T, Weinberg G, et al. Lipid emulsion for local anaesthetic toxicity. *Anaesthesia* 2006;61:1116-7, doi:10.1111/j.1365-2044.2006.04841.x.
8. Weinberg G. Lipid rescue resuscitation from local anaesthetic cardiac toxicity. *Toxicol Rev* 2006;25:139-45, doi:10.2165/00139709-200625030-00001.
9. Weinberg G. Lipid infusion resuscitation for local anesthetic toxicity: proof of clinical efficacy. *Anesthesiology* 2006;105:7-8, doi:10.1097/0000542-200607000-00005.
10. Weinberg G, Ripper R, Feinstein DL, et al. Lipid emulsion infusion rescues dogs from bupivacaine-induced cardiac toxicity. *Reg Anesth Pain Med* 2003;28:198-202.
11. Harvey M, Cave G. Intralipid outperforms sodium bicarbonate in a rabbit model of clomipramine toxicity. *Ann Emerg Med* 2007;49:178-85, doi:10.1016/j.annemergmed.2006.07.016.
12. Sirianni AJ, Osterhoudt KC, Calello DP, et al. Use of lipid emulsion in the resuscitation of a patient with prolonged cardiovascular collapse after overdose of bupropion and lamotrigine. *Ann Emerg Med* 2008;51:412-5.
13. Finn SD, Uncles DR, Willers J, et al. Early treatment of a quetiapine and sertraline overdose with intralipid. *Anaesthesia* 2009;64:191-4, doi:10.1111/j.1365-2044.2008.05744.x.
14. Zuidema X, Dunser MW, Wenzel V, et al. Terlipressin as an adjunct vasopressor in refractory hypotension after tricyclic antidepressant intoxication. *Resuscitation* 2007;72:319-23, doi:10.1016/j.resuscitation.2006.07.005.
15. Hutchinson M, Traub S. Tricyclic antidepressant poisoning. In: Ewald MB, editor. UpToDate. Waltham (MA): 2011.
16. Weinberg GL. In defence of lipid resuscitation. *Anaesthesia* 2006;61:807-8, doi:10.1111/j.1365-2044.2006.04723.x.
17. Weinberg GL, Di Gregorio G, Ripper R, et al. Resuscitation with lipid versus epinephrine in a rat model of bupivacaine overdose. *Anesthesiology* 2008;108:907-13, doi:10.1097/ALN.0b013e31816d91d2.
18. Weinberg GL, Ripper R, Murphy P, et al. Lipid infusion accelerates removal of bupivacaine and recovery from bupivacaine toxicity in the isolated rat heart. *Reg Anesth Pain Med* 2006;31:296-303.
19. Weinberg GL. Lipid infusion therapy: translation to clinical practice. *Anesth Analg* 2008;106:1340-2, doi:10.1213/ane.0-b013e31816a6c09.
20. Tebbutt S, Harvey M, Nicholson T, et al. Intralipid prolongs survival in a rat model of verapamil toxicity. *Acad Emerg Med* 2006;13:134-9, doi:10.1111/j.1553-2712.2006.tb01661.x.

21. Yoav G, Odelia G, Shaltiel C. A lipid emulsion reduces mortality from clomipramine overdose in rats. *Vet Hum Toxicol* 2002;44:30.
22. Bania TC, Chu J, Perez E, et al. Hemodynamic effects of intravenous fat emulsion in an animal model of severe verapamil toxicity resuscitated with atropine, calcium, and saline. *Acad Emerg Med* 2007;14:105-11, doi:[10.1111/j.1553-2712.2007.tb01752.x](https://doi.org/10.1111/j.1553-2712.2007.tb01752.x).
23. Kline JA, Raymond RM, Leonova ED, et al. Insulin improves heart function and metabolism during non-ischemic cardiogenic shock in awake canines. *Cardiovasc Res* 1997;34:289-98, doi:[10.1016/S0008-6363\(97\)00022-9](https://doi.org/10.1016/S0008-6363(97)00022-9).
24. Doursout MF, Joseph PM, Liang YY, et al. Role of propofol and its solvent, intralipid, in nitric oxide-induced peripheral vasodilatation in dogs. *Br J Anaesth* 2002;89:492-8.
25. Marwick PC, Levin AI, Coetzee AR. Recurrence of cardiotoxicity after lipid rescue from bupivacaine-induced cardiac arrest. *Anesth Analg* 2009;108:1344-6, doi:[10.1213/ane.0b013e3181979e17](https://doi.org/10.1213/ane.0b013e3181979e17).



City life on Island time

Locum Emergency Room Physicians

Victoria Vancouver Island


The Vancouver Island Health Authority has opportunities for Locum Emergency Room Physicians at the Victoria General and Royal Jubilee Hospitals in Victoria, British Columbia.

You hold CCFP-EM or FRCPC and are eligible for full licensure with the College of Physicians and Surgeons of British Columbia. Locum opportunities of 8 to 15 shifts per month are available during July and August. Work alongside a large, supportive group staffing these two major hospitals, each with 45,000 visits per year, providing full service Emergency Medicine including pediatrics and trauma. Competitive remuneration is offered.

Victoria, the capital city of British Columbia, is world-renowned for its natural beauty and temperate climate and is an ideal location for a summer locum!

To apply, please forward your CV, cover letter and the names of three references to:

Dr. Chris Morrow
 Site Chief, Department of Emergency Medicine (RJH/VGH)
 Medical Director, Trauma Services VIHA South Island
 Email: christopher.morrow@viha.ca


 VANCOUVER ISLAND
 health
 authority
 viha.ca