

## Letter to the Editor

# A cluster of postoperative *Pseudomonas aeruginosa* endophthalmitis infection at an outpatient cataract surgery center

Santhi Singanamala MD<sup>1</sup>, Kutluhan Incekara MS<sup>2</sup> , Donna Nucci RN, CIC<sup>3</sup> and Scott C Roberts MD<sup>1,3</sup> 

<sup>1</sup>Section of Infectious Diseases, Department of Internal Medicine, Yale School of Medicine, New Haven CT, USA, <sup>2</sup>Connecticut Department of Public Health, Rocky Hill, CT, USA and <sup>3</sup>Infection Prevention, Yale New Haven Hospital, New Haven, CT, USA

*To the Editor*—Intracameral antibiotics are commonly used in cataract surgery as an off-label adjunctive therapy to prevent postsurgical endophthalmitis. Since commercially produced, single-use formulations are not available in the United States, administration is reliant on compounding, which can be at a central pharmacy or on-site at the surgical center. Compounding increases the risk of contamination, and potentially iatrogenic infection, if not done properly.

A 65-year-old man, patient A, presented to Yale New Haven Hospital with acute onset right eye pain and redness one day after routine cataract surgery (Figure 1A). His physical examination was notable for upper and lower eyelid swelling, conjunctival injection, and hypopyon of the anterior chamber. An MRI was concerning for an optic globe infection. An intravitreal culture grew pan-sensitive *Pseudomonas aeruginosa* and he was started on intravitreal and intravenous ceftazidime. A second patient, patient B, an 87-year-old man presented with left eye pain, redness, and loss of vision (Figure 1B) 5 days after cataract surgery received at the same center on the same day as patient A. An MRI confirmed endophthalmitis with preseptal and postseptal cellulitis. Intravitreal cultures grew pan-sensitive *Pseudomonas aeruginosa* phenotypically identical to patient A and he was also started on intravitreal and intravenous ceftazidime. Given the similarities in case presentations, an epidemiologic investigation was pursued.

## Methods

An epidemiologic investigation was performed by surveilling patients who received surgery at the same outpatient surgical center on the same day, and patients who underwent surgery in the subsequent 30 days. Intra-operative case details were obtained from the primary surgical team, the operating room environment was inspected, and surgical practices, including hand hygiene and medication compounding, were observed. Whole genome sequencing on the two *Pseudomonas aeruginosa* isolates cultured from patients A & B using Illumina Miseq with a 2 x 150 paired-end design was performed, and genomes were assembled *de novo* (Spades 3.15.5) to determine the clonality of the isolates. Data were analyzed by the SNVPhyl\_Nextflow v1.0.0 pipeline ([https://github.com/DHQP/SNVPhyl\\_Nextflow](https://github.com/DHQP/SNVPhyl_Nextflow)) and confirmed by the NCBI Pathogen Detection Pipeline. MLST typing (mlst 2.22.0) and AMR

(NCBI AMRFinder Plus 3.10.40) gene detection was also performed. This work satisfied Yale University's 100CH10 Quality Improvement checklist and was except from Institutional Review Board evaluation.

## Results

Eight patients, including patients A & B, underwent cataract surgery on the same day with identical surgical teams in the same operating room at a local surgical center. Six of these patients had uncomplicated postoperative courses without infection. No additional cases were noted on surveillance, and the facility subsequently reported no infections after 1-year of follow up. Intra-operative investigations revealed potential non-sterile techniques used in compounding intracameral cefuroxime that was routinely given to all patients intraoperatively. During the beginning of the COVID-19 pandemic, the facility transitioned from a central compounding pharmacy to manual compounding on site due to supply chain issues. Compounding of the intracameral cefuroxime was performed in a dedicated medication room near a sink with a splashguard in place. The break in sterility was thought due to preoperative compounding by a healthcare personnel with an injured upper extremity who was wearing a household soft brace. The brace was a barrier to hand hygiene which may have precluded appropriate sterile technique. Whole genome sequencing confirmed clonality of the *Pseudomonas aeruginosa* isolates, which differed by one single nucleotide variant.

Both patients were treated with intravitreal ceftazidime and intravenous ceftazidime, which was transitioned to oral ciprofloxacin. Endophthalmitis in both patients resolved after 3 weeks, however, one patient sustained permanent vision loss and the other had poor vision limited to hand movement perception.

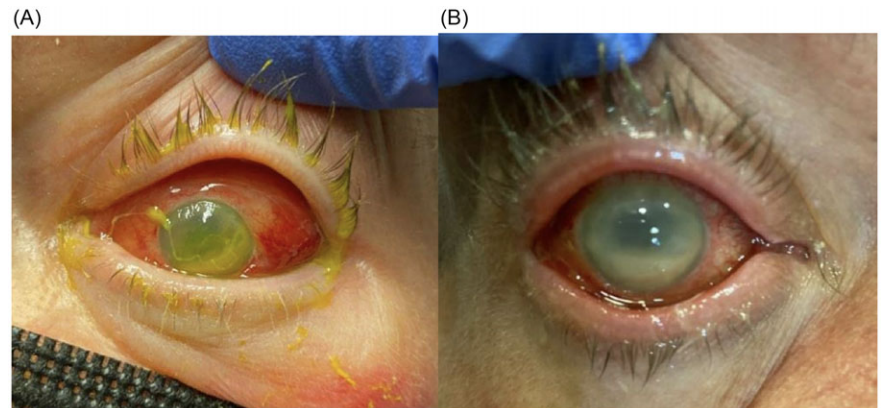
## Discussion

We present two cases of genomically confirmed postcataract *Pseudomonas aeruginosa* endophthalmitis which resulted in vision loss in both patients. While we do not definitively know the source of the *Pseudomonas aeruginosa*, we suspect this was due to inadequate hand hygiene in the healthcare personnel given the individual compounding the single-use injections had a brace on one of their hands and likely was unable to maintain sterility through routine hand hygiene. Contaminated antibiotic stock solution is less likely, as six of the eight cases performed in the same operating room with the same operating team that day did not

**Corresponding author:** Scott C Roberts; Email: [scott.c.roberts@yale.edu](mailto:scott.c.roberts@yale.edu)

**Cite this article:** Singanamala S, Incekara K, Nucci D, Roberts SC. A cluster of postoperative *Pseudomonas aeruginosa* endophthalmitis infection at an outpatient cataract surgery center. *Infect Control Hosp Epidemiol* 2024. 45: 1146–1147, doi: [10.1017/ice.2024.74](https://doi.org/10.1017/ice.2024.74)





**Figure 1.** Presenting symptoms of endophthalmitis for patients A and B, respectively. Noted findings included swelling of upper and lower eyelids, conjunctival injection, and hypopyon of the anterior chambers.

develop endophthalmitis. This cluster illustrates the risk of on-site compounding of intracameral antibiotics.

Endophthalmitis is a rare complication of cataract surgery, and most centers administer intracameral antibiotics, commonly vancomycin, cefuroxime, or moxifloxacin through off-label use as prevention. Despite limited randomized controlled trials and a lack of United States Food and Drug Administration approval, use of intracameral antibiotics as supplements to topical antibiotics remains widespread. While multiple studies support intracameral injection with either cefuroxime or moxifloxacin to reduce the incidence of endophthalmitis,<sup>1,2</sup> use is not without risk. Commercially available formulations do not exist, so individual practices often perform on-site compounding. Manually diluting and separating stock antibiotic into single-use injections introduces the risk of contamination if not performed sterilely, and outbreaks due to this have been reported.<sup>3</sup> Noninfectious complications can arise as well. This includes errors in dosing, which can lead to macular edema and infarction,<sup>4</sup> toxic anterior segment syndrome, and more recently, hemorrhagic occlusive retinal vasculitis associated with intracameral vancomycin<sup>5,6</sup> which has led to recommendations against routine use.

While the benefits of intracameral antibiotic injection in preventing postcataract endophthalmitis may outweigh the risk of complication on a population level, additional data are needed to guide optimal use of intracameral antibiotics. For instance, administering centrally compounded prepackaged single-use vials

may have mitigated the infections introduced by manual compounding in this cluster.

**Financial support.** This work was not funded.

**Competing interests.** All authors report no conflicts of interest in this work.

## References

1. Gower EW, Lindsley K, Tulenko SE, Nanji AA, Leyngold I, McDonnell PJ. Perioperative antibiotics for prevention of acute endophthalmitis after cataract surgery. *Cochrane Database Syst Rev* 2017;2:CD006364.
2. Haripriya A, Chang DF, Ravindran RD. Endophthalmitis reduction with intracameral moxifloxacin in eyes with and without surgical complications: Results from 2 million consecutive cataract surgeries. *J Cataract Refract Surg* 2019;45:1226–1233.
3. Cakir M, Imamoglu S, Cekiç O, *et al.* An outbreak of early-onset endophthalmitis caused by *Fusarium* species following cataract surgery. *Curr Eye Res* 2009;34:988–995.
4. Wong DC, Waxman MD, Herrinton LJ, Shorstein NH. Transient macular edema after intracameral injection of a moderately elevated dose of cefuroxime during phacoemulsification surgery. *JAMA Ophthalmol* 2015;133:1194–1197.
5. Centers for Disease Control and Prevention (CDC). Toxic anterior segment syndrome after cataract surgery—Maine, 2006. *MMWR Morb Mortal Wkly Rep* 2007;56:629–630.
6. Witkin AJ, Chang DF, Jumper JM, *et al.* Vancomycin-Associated Hemorrhagic Occlusive Retinal Vasculitis: Clinical Characteristics of 36 Eyes. *Ophthalmology* 2017;124:583–595.