

Selective Sparing of Human Nucleus Accumbens in Aging and Anoxia

Ke-Wei Huang and Yan Zhao

ABSTRACT: *Objective:* To investigate the effects of aging and anoxia on the nucleus accumbens. *Methods:* The number of neurons in nucleus accumbens and caudate nucleus in 35 patients over 65 and 35 under 65 years, all without neurological or psychiatric diseases were counted. *Results:* There was no statistically significant difference between the number of neurons in the accumbens in the two groups, but there was a decrease in the number of neurons in the elderly group. There was no reduction in volume of the neuronal nucleoli of the accumbens measured in 12 elderly patients compared to controls. These data suggest a sparing of the accumbens from changes associated with aging. There was relative preservation of the nucleus accumbens in 3 patients with anoxic encephalopathy. *Conclusions:* These results show that accumbens was resistant to both aging and anoxia, the mechanism of which is discussed.

RÉSUMÉ: *Invulnérabilité du noyau accumbens humain à différents facteurs.* *Objectif:* L'étude porte sur les effets du vieillissement et de l'anoxie sur le noyau accumbens. *Méthode:* Nous avons dénombré les neurones du noyau accumbens (Acc) et du noyau caudé (NC) chez 35 patients de plus de 65 ans et 35 patients de moins de 65 ans, sans maladie neurologique ou psychiatrique. *Résultats:* Il n'existait pas de différence significative au point de vue statistique entre le nombre de neurones dans l'Acc entre les deux groupes. Cependant, il y avait une diminution du nombre de neurones dans le NC du groupe âgé. Il n'y avait pas de diminution du volume des nucléoles neuronaux de l'Acc chez 12 patients âgés comparés à des contrôles. Ces observations suggèrent une épargne sélective de l'Acc par le vieillissement. Chez 3 patients avec encéphalopathie anoxique, l'Acc était relativement préservé. *Conclusions:* Ces résultats indiquent que l'Acc est résistant au vieillissement et à l'anoxie, et nous discutons des mécanismes en cause.

Can. J. Neurol. Sci. 1995; 22: 290-293

In the past, the nucleus accumbens (Acc) was considered a phylogenetically ancient extension of the head of the caudate nucleus,¹ which in most mammals appears morphologically distinct, because of the relative absence of perforating fiber bundles, clustering of neurons and Islands of Calleja.² Recently, much work has been done to show connection of Acc with various parts of the brain: 1) Afferent fibers from hippocampus,³ thalamus,⁴ cortex⁵ and ventral tegmental area;⁶ 2) Efferent fibers originating from Acc and ending in pallidum, substantia innominata and lateral preoptic region,⁷ substantia nigra, hypothalamus and ventral tegmental area.^{2,8} The Acc is assumed to serve as an interface between limbic and motor system for the translation of the "motivational-emotional" determinants of behavior into "action".^{7,9,10}

There has been very little work on the role of the nucleus accumbens in any diseases, besides the fact that it is relatively spared by the pathologic process in Huntington's disease^{11,12} and that the Acc is somewhat concerned with schizophrenia.^{13,14} Although there have been quite a number of reports on the deteriorating effect of anoxia on the putamen and caudate,¹⁵ basal ganglia and thalami,¹⁶ putamen and cerebellum¹⁷ and globus Pallidus,¹⁸ which were only demonstrated by MRI, there have

been no articles on the effect of anoxia on the nucleus accumbens, or on the effects of aging.

The purpose of the present work is to investigate the effect of aging and anoxia on the nucleus accumbens and to discuss the mechanism.

MATERIALS AND METHODS

Subjects

Our subjects were divided into two groups:

Elderly Group Thirty-five elderly subjects (16 men and 19 women all above 65 years) and 35 control cases, (26 men and 9 women varying from 20-65 years); both groups had no neurological or psychiatric diseases.

From the Neuropathology Laboratory, Chinese PLA General Hospital, Beijing.

RECEIVED AUGUST 10, 1994. ACCEPTED IN FINAL FORM MAY 17, 1995.

Reprint requests to: K.W. Huang, M.D., Neuropathology Laboratory, Chinese PLA General Hospital, Beijing, 100853, People's Republic of China

Anoxia Group There were 3 cases: the first was a man of 55 years suffering from cardiac arrest for 5 minutes; afterwards, he suffered from repeated pulmonary infections resulting in decortication and died 7 months after onset. The second, a man of 75 also suffering from repeated pulmonary infections with severe cerebral anoxia leading to vegetative existence, died 7 months after onset. The third was a woman of 63, suffering from uremia and acidosis leading to bradypnea with respiratory arrest who died after one month.

Histopathological Methods

Specimens were coronal sections, taken from the middle region of Acc (Figure 1) according to standard level suggested by von Brockhaus¹⁹ and Walsh et al.²⁰ It was characterized by scarcity of perforating fibers, clustering of neurons and Islands of Calleja.^{21,22} These specimens were embedded in paraffin, cut at a thickness of 8 μm and stained with Luxol-fast-blue hematoxylin and eosin (LH&E) and Nissl stain.

Quantitative Assessment

A) Cell Counting The cell population of the Acc and that of the head of caudate nucleus (CN) of subject group 1 were counted according to the method of Vonsattel et al.²³ using a Nikon microscope giving a magnification of 400X. Each field covered a surface of 0.0087 mm^3 of the slide, which was defined by means of an eyepiece grid. The first 1 mm^3 from ependymal surface was skipped, and all "dead" areas (e.g., vessels or bundles of fibers) larger than 0.0015 mm on the slides were deleted. For each case, the average number of neurons was counted in 15 fields of Acc as well as CN was taken.

B) Measurement of the nucleolar volume This was done according to Mann's view²⁴ which regards nucleolar volume as an accurate reflection of the levels of protein synthesis in nerve cells. Neuronal nucleoli of Acc were measured by using an Image Analysis System (IBAS 2000). Twelve cases were randomly selected from the elderly group and 12 from the control group. For each case, 35 neuronal nucleoli were measured.

Neuropathological Observation

For the anoxic group, both macroscopic and microscopic features of the Acc, CN and putamen were observed.

RESULTS

Quantitative Study

A) Cell Counting: There was no significant difference in the number of neurons in Acc of elderly subjects and that of control subjects ($P > 0.2$), while there was a definite decrease in the number of neurons in CN of the elderly group compared to controls ($P < 0.001$) (Table 1).

B) The volume of the nucleoli of Acc. There was again no difference between the elderly and control groups (Table 2).

Table 1: Comparison of the Number of Neurons (cells/field) of Acc and CN in 2 Groups ($X \pm Sx$).

	Age 20 to 65 (N = 35)	Age greater than 65 (N = 35)	Percentage difference (%)	P Value
Acc	25.57 \pm 0.53	25.15 \pm 0.51	1.6	0.2
CN	18.88 \pm 0.38	16.53 \pm 0.205	12.4	0.001

Acc = nucleus accumbens

CN = caudate nucleus

N = number of cases examined

Table 2: Comparison of Mean Volume of the Nucleoli of Acc in 2 Groups ($X \pm Sx$).

	N	mean volume (μm)	P Value
control	14	8.61 \pm 0.41	
elderly	12	8.57 \pm 0.41	> 0.5

N = number of cases examined

Acc = nucleus accumbens

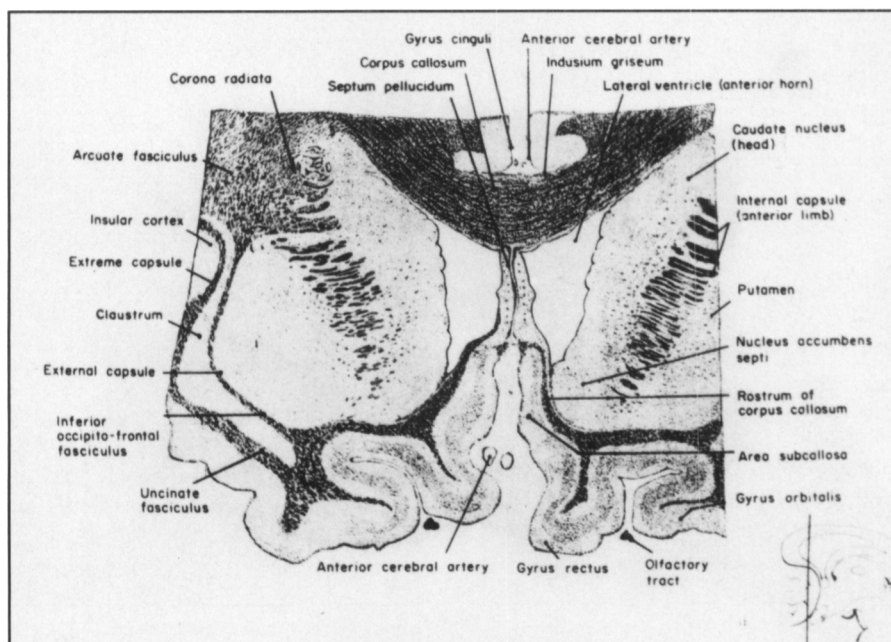


Figure 1: A sketch of the coronal section from the middle region of nucleus accumbens.

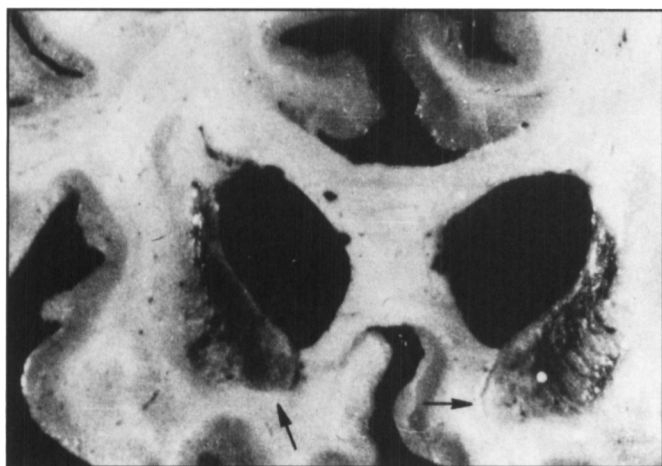


Figure 2: A section from an anoxic encephalopathic brain showing relative preservation of the nucleus accumbens (arrows) with severe bilateral damage to the caudate nucleus.

Neuropathological Observation

Anoxic Group There were 2 cases of anoxic change at late stage where the Acc was relatively preserved bilaterally, while the caudatoputamen was severely damaged on both sides (Figure 2). Light microscopy revealed an absence of neurons with gliosis of CN, while there was partial preservation of neurons and only slight gliosis of Acc, (Figure 3). Another subject died in acute stage; the caudatoputamen showed complete necrosis, while Acc was completely spared (Figure 4). Light microscopy confirmed the macroscopic findings.

DISCUSSION

The fact that the number of neurons and the volume of the nucleoli of neurons of Acc of the elderly patients showed no reduction implies that aging has no deteriorating effect on that nucleus, while it has a definite effect on CN. There is a decreased number of neurons in elderly amygdala²⁵ and in elderly hippocampus;²⁶ the two structures have close connections with

Acc, all three belonging to limbic system; this again supports the sparing of Acc in aging.

The symmetrical sparing of Acc in 3 cases of anoxic encephalopathy speaks eloquently for the sparing of this nucleus during anoxia. This cannot be explained by vascular factors, because the nucleus accumbens is supplied by the recurrent artery of Heubner, which also supplies the rest of the striatum (Perlmutter et al.,²⁷ Dunker et al.²⁸ and Earpenter et al.²¹). Furthermore, in anoxic encephalopathy, the selective vulnerability of the Purkinje cells of cerebellum, CA1, CA3 and endfolium of hippocampus and sparing of CA2 and the motor nuclei of the brain stem and anterior horn cells of the spinal cord cannot be due to impairment of blood supply and has been already explained by pathocllisis; this is also the mechanism in our three cases.

According to the report of Herkenham et al.²² and Myers et al.²⁹ the Acc was completely intact, at the early stage of Huntington's disease, while CN suffered degenerative change; at later stages, the Acc revealed only slight change, while the CN was almost completely destroyed. These data also point to the fact that Acc is resistant to degenerative processes.

Uemura et al.³⁰ showed in their experiment on gerbils that NADPH-diaphorase positive neurons were strikingly preserved in the ischemic dorsolateral portion of the striatum, in which there was severe neuronal loss. Beal et al.³¹ did experimental research on rats with quinolinic acid and found that concentrations of both somatostatin and neuropeptide Y as well as the density of NADPH-diaphorase neurons and terminals are 2-3-fold higher in Acc than in the remainder of striatum. Ferrente et al.³² did research on six cases of Huntington's disease and found the sparing of NADPH-diaphorase neurons of CN in a honeycomb pattern along a 50 µm-wide track in the middle of the CN, excluding the Acc. It may be concluded that the mechanism of the sparing of nucleus accumbens in aging, anoxia and Huntington's disease is due to the presence of large amount of NADPH-diaphorase neurones in that nucleus.

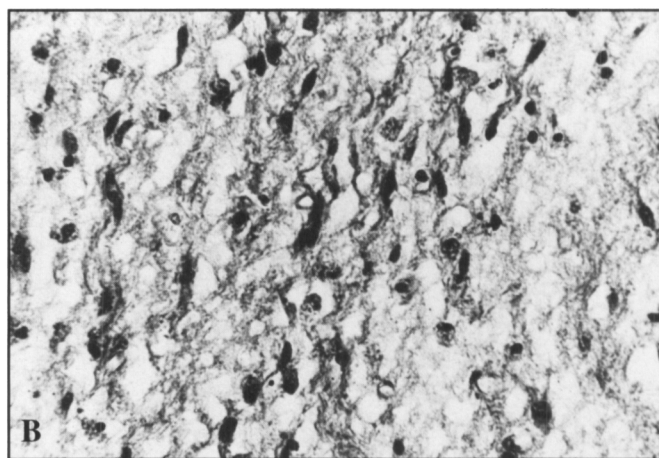
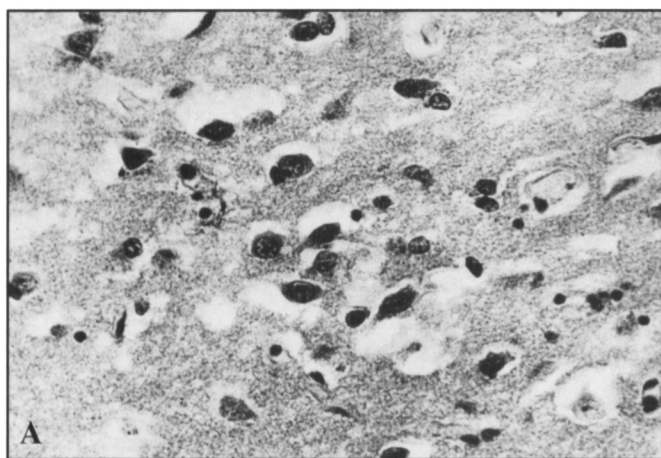


Figure 3: A) Photomicrograph showing preserved neurons in nucleus accumbens of the brain shown in Figure 2. B) Complete loss of neurons with gliosis of the caudate nucleus in the brain shown in Figure 2. Magnification 400x.

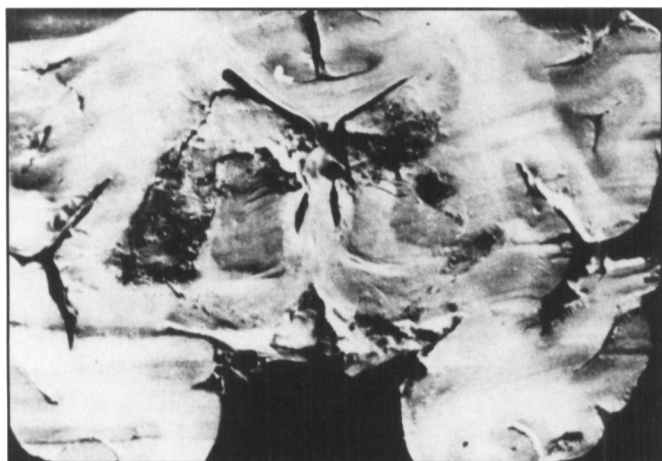


Figure 4: A case of acute encephalopathy showing spared nucleus accumbens with destruction of caudate and putamen.

ACKNOWLEDGEMENT

This work was supported by Sandoz Foundation for Gerontological Research.

REFERENCE

- Ariens-Kappers CU, Theunissen WF. Die Phylogense des Rhinencephalons, des Corpus Striatum und der Vorderhirn Commissuren. *Folia Neurobiol* 1907; 1: 173-288.
- Swanson LW, Cowan WM. A note on the connections and development of the nucleus accumbens. *Brain Res* 1975; 92: 324-330.
- Totterdell S, Smith AD. Cholecystokin in immunoreactive boutons in synaptic contact with hippocampal pyramidal neurons that project to the nucleus accumbens. *Neuroscience* 1986; 19: 181-192.
- Jayaraman A. Organization of thalamic projections in the nucleus accumbens and the caudate nucleus in cats and its relation with hippocampal and other subcortical afferents. *J Comp Neurol* 1985; 231: 396-420.
- Phillipson OT, Griffiths AC. The topographic order of inputs to nucleus accumbens in the rat. *Neuroscience* 1985; 16: 275-296.
- Studler JM, Reibaud M, Tramu G, et al. Pharmacological study on the mixed CCK 8/DA mesonucleus accumbens pathway: evidence for the existence of storage sites containing the two transmitters. *Brain Res* 1984; 298: 91-97.
- Swerdlow NR, Koob GF. The neural substrates of apomorphine-stimulated locomotor activity following denervation of the nucleus accumbens. *Life Sci* 1984; 35: 2537-2544.
- Chang HT, Kitai ST. Projection neurons of the nucleus accumbens: an intracellular labeling study. *Brain Res* 1985; 347: 112-116.
- D'Angio M, Serrano A, Rivy JP, Scatton B. Tail-pinch stress increases extracellular DORPAC levels (as measured by *in vivo* voltammetry) in the rat nucleus accumbens but not frontal cortex: antagonism by diazepam and zolpidem. *Brain Res* 1987; 409: 169-563.
- Phillips S, Sangalang V, Sterns G. Basal forebrain infarction. A clinicopathologic correlation. *Arch Neurol* 1987; 44: 1134-1138.
- McCaughey WTE. The pathologic spectrum of Huntington's chorea. *Nerv Ment Dis* 1961; 133: 91-103.
- Bots GT, Bruyn GW. Neuropathological changes of nucleus accumbens in Huntington's chorea. *Acta Neuropathol (Berl)* 1981; 55: 21-22.
- Stevens JR. An anatomy of schizophrenia. *Arch Gen Psychiat* 1973; 29: 177-189.
- Mattysse S. Nucleus accumbens and schizophrenia. *In: Chronister RB, De France JF, eds. The Neurobiology of the Nucleus Accumbens.* Brunswick, Maine: Haer Institute, 1981: 351-359.
- Hori A, Hirose G, Kataoka S, et al. Delayed postanoxic encephalopathy after strangulation. Serial neuroradiological and neurochemical studies. *Arch Neurol* 1991; 48: 871-874.
- Rutherford MA, Pennock JM, Murodoch-Eaton DM, Cowan FM, Dubowitz LM. Athetoid cerebral palsy with cysts in the putamen after hypoxic-ischemic encephalopathy. *Arch Dis Child* 1992; 67: 846-850.
- Mascalchi M, Dal-Pozzo-Ge, Pinto F. MRI demonstration of the cerebellar damage in diffuse hypoxic-ischemic encephalopathy. Case report. *Ital J Neurol Sci* 1992; 13: 517-519.
- Fève AP, Fenelon G, Wallays C, Remy P, Guillard A. Axial motor disturbances after hypoxic lesion of the globus pallidus. *Mov Disord* 1993; 8: 321-326.
- Von Brockhaus H. Zur feineren Anatomie des Septum und des Striatum. *J Psychol Neurol* 1942; 51: 1-55.
- Walsh FX, Stevens TJ, Langlais PJ, Brid ED. Dopamine and homovanillic acid concentrations in striatal and limbic regions of human brain. *Ann Neurol* 1982; 12: 52-55.
- Carpenter MB, Sutin J. The corpus striatum. *In: Carpenter MB, Sutin J, eds. Human Neuroanatomy, 8th Edition.* Chapter 17. Baltimore: Waverly Press, 1983; 17: 579-611.
- Herkenham M, Edley SM, Stuart J. Cell clusters in the nucleus accumbens of the rat, and the mosaic relationship of opiate receptors, acetylcholinesterase and subcortical afferent terminations. *Neuroscience* 1984; 11: 561-593.
- Vonastel JP, Myers RH, Stevens TJ, et al. Neuropathological classification of Huntington's disease. *J Neuropathol Exp Neurol* 1985; 44: 559-577.
- Mann D.M.A. Annotation. Nerve cell protein metabolism and degeneration disease. *Neuropathol Appl Neurobiol* 1982; 8: 161-167.
- Herzog AG, Kang Kemper TL. Amygdaloid changes in aging and dementia. *Arch Neurol* 1980; 37: 625-629.
- Mani RB, Lohr JB, Jeste DV. Hippocampal pyramidal cells and aging in the human: a quantitative study of neuronal loss in sectors CA 1 to CA4. *Exp Neurol* 1986; 94: 29-40.
- Perlmutter D, Rhoton AL. Microsurgical anatomy of the anterior cerebral-anterior communicating recurrent artery complex. *J Neurosurg* 1976; 45: 259-272.
- Dunker RO, Harris AB. Surgical anatomy of the proximal anterior cerebral artery. *J Neurosurg* 1976; 44: 359-367.
- Myers RH, Vonsattel JP, Stevens TJ, et al. Clinical and neuropathologic assessment of severity in Huntington's disease. *Neurology* 1988; 38: 341-347.
- Uemura Y, Kowall NW, Beal MF. Selective sparing of NADPH-diaphorase-somatostatin-neuropeptide Y neurons in ischemic gerbil striatum. *Ann Neurol* 1989; 27: 620-625.
- Beal MF, Kowall NW, Ellison DW, et al. Replication of the neurochemical characteristics of Huntington's disease by quinolinic acid. *Nature* 1986; 321: 168-171.
- Ferrante RJ, Kowall NW, Beal MF, et al. Selective sparing of a class of striatal neurons in Huntington's disease. *Science* 1985; 230: 561-563.