

University of Toronto Neurosurgical Rounds No. 1.

Massive Osteolysis in Association with Multiple Cerebrospinal Fluid Fistulae

HAROLD J. HOFFMAN, DEREK C. HARWOOD-NASH, T. P. MORLEY and N. BARRY REWCASTLE

CASE HISTORY

A female child, TK, was born January 12, 1965, and was initially admitted to the Hospital for Sick Children, Toronto, on January 13, 1972, at age seven years with a seven-day history of runny nose, earache, headache, and fever. On the day before admission, she had a grand mal seizure and lumbar puncture revealed purulent cerebrospinal fluid (C.S.F.) which grew pneumococci. She was treated with antibiotics, her meningitis resolved, and she was discharged home nine days after admission.

Over the next two years, she continued to drain fluid from her nose so that her mother would note a damp ring on her pillow.

She was re-admitted on March 12, 1974 with a two-day history of headache, increasing drowsiness, and lethargy. She had a stiff neck and was febrile. Lumbar puncture showed a purulent pneumococcal meningitis. Blood culture grew pneumococci.

Her meningitis improved quickly with antibiotic therapy and we were asked to see her about the C.S.F. rhinorrhea on March 18, 1974 by which time her meningitis had resolved. Her face was asymmetric, with underdevelopment of the left side, the left lateral superior orbital rim, lateral orbital rim, left maxilla, and left mandible. She was deaf on the left. Plain roentgenographs and polytomography showed destruction of the left petrous apex and a flattened posterior clinoid process together with a poorly mineralized body of the sphenoid bone. Bone scan of skull showed increased uptake in the petrous pyramid on the left. A C.S.F. scan suggested a C.S.F. leak via the eustachian tube. Angiography was

normal and an air encephalogram showed only an unusual and unexplained ballooning of the anterior third ventricle. A pantopaque myelogram showed fistulae through the petrous bone on the left into the eustachian tube, into the nasopharynx, and also through the sella into the sphenoid sinus and nose (Figs. 1 and 2).

The two fistulae through the petrous bone were repaired. One of these was in the middle fossa going through the region of the tegmen tympani with a tongue of brain sticking down into the middle ear. The other was in the posterior fossa, where a tongue of cerebellum was protruding anteriorly into the posterior portion of the petrous bone. The leak through the sphenoid sinus was repaired by Dr. D. Mitchell through a transthemoidal approach.

Examination of the removed bony tissue by Dr. Margaret Norman showed only a few residual thinned trabeculae lying in dense fibrous tissue that contained numerous vascular channels and collections of mononuclear cells (Fig. 3). Some vessels were filled with blood, others with a proteinaceous coagulum (Fig. 4). The endothelial lining cells were flattened or slightly ovoid, but no histological evidence of proliferation was seen. On one edge of the specimen there was a channel surrounded by proliferating fibroblasts and mononuclear cells that might have represented a tract. No dura mater was seen.

The rhinorrhea recurred and investigation showed a leak through the sphenoid sinus, but obliteration of the leak through the petrous bone. Dr. Mitchell carried out a second and successful repair of the sphenoid leak.

These case reports are taken from the neurosurgical rounds of the various teaching hospitals of the University of Toronto. They are expected to be a regular feature in each issue.

Reprint requests to: H. J. Hoffman, MD, Hospital for Sick Children, Division of Neurosurgery, Room 1504, 555 University Avenue, Toronto, Ontario M5G 1X8, Canada

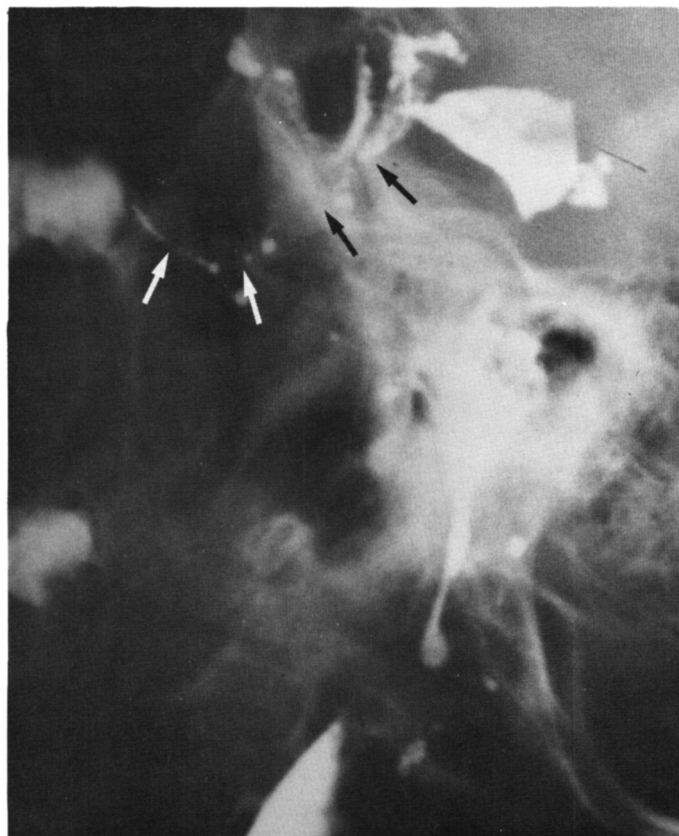


Figure 1 — Lateral view of posterior fossa myelogram showing pantopaque passing through sella into sphenoid sinus and nose.

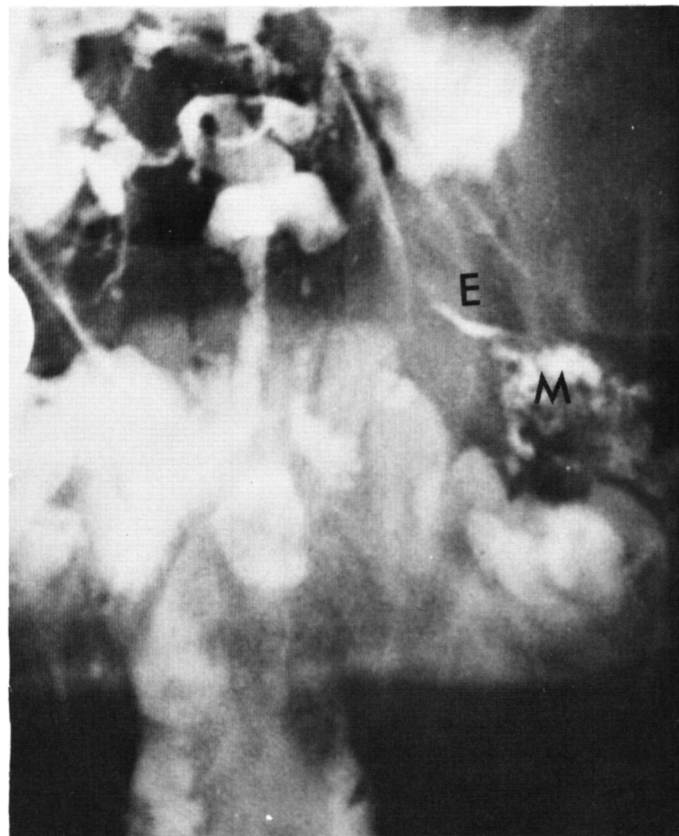


Figure 2 — AP view of posterior fossa myelogram showing pantopaque passing into eustachian tube (E) and mastoid air cells (M).

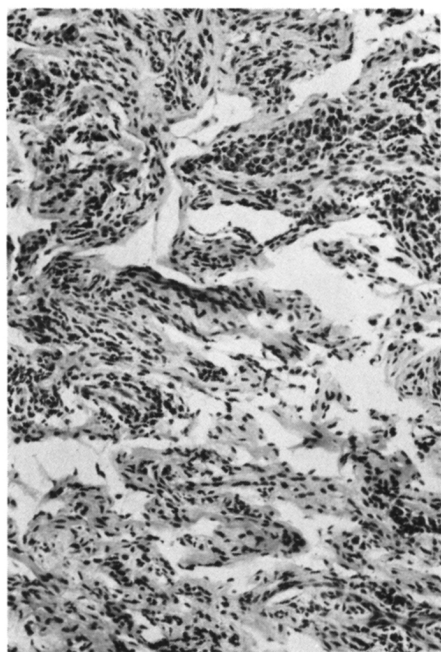


Figure 3 — Specimen of petrous bone showing dense fibrous tissue replacing the bone and containing many endothelial-lined channels and foci of mononuclear cells. HE x 200

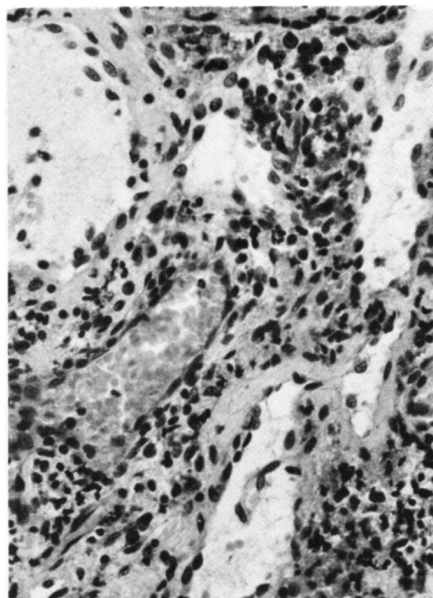


Figure 4 — Same specimen as Figure 3 lesion in which the endothelial-lined cells are a little plump in some areas without proliferative activity. Some vascular channels are filled by erythrocytes, others by a coagulum of protein. HE x 500

She had no further rhinorrhea. However, on September 12, 1977 she was admitted with a two-week history of neck stiffness associated with torticollis and headache. X-rays of cervical spine showed marked demineralization and expansion of C1 and C2. Computed tomography of the base of the skull and the upper cervical vertebrae demonstrated a sponge-like expansion of these bony structures (Figs. 5a and b).

At operation the rim of the foramen magnum was exposed and removed. The bone was friable and soft. Histology reported by Dr. L. E. Becker showed prominent blood-filled endothelial channels between the bony trabeculae suggestive of a vascular hamartoma (Fig. 6).

On the basis of this pathology, a diagnosis of disappearing bone disease (massive osteolysis — secondary to hemangiomas/malformation of bone of skull and cervical spine) was made and she was transferred to the Princess Margaret Hospital for a

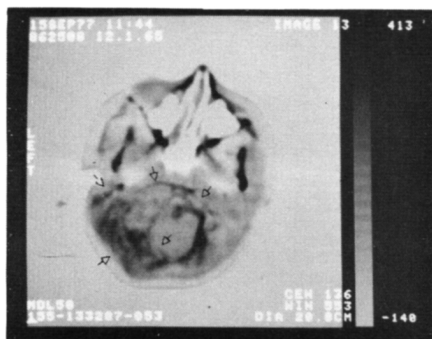


Figure 5a — Axial C.T. scan through base of skull demonstrates foam-like destruction of the left occiput and clivus (arrows) involving the left rim of the foramen magnum. The tip of the odontoid is visible.

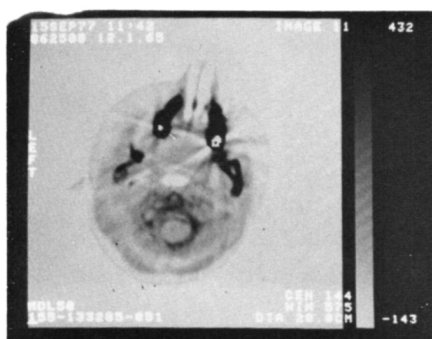


Figure 5b — The entire body of C2, particularly anteriorly and laterally, is similarly involved.

course of radiotherapy. She received a dose of 3,000 rads in fifteen fractions to the base of the skull and upper cervical spine.

X-rays of the cervical spine following the treatment showed considerable re-ossification with the partial disappearance of the destructive lesions.

Cervical spine X-rays of May 1978 are shown in Figure 7a and X-rays of June 18, 1979 show a relatively well-ossified, well-formed cervical spine as seen in Figure 7b.

DISCUSSION

There is a variety of forms of osteolysis:

1. Osteolysis in association with well recognized disorders such as osteomyelitis, rheumatoid arthritis, tabes dorsalis, or trauma.
2. Idiopathic hereditary osteolysis

involving carpal and tarsal bones, inherited as an autosomal dominant without renal disease or angioma.

3. Idiopathic osteolysis with nephropathy, involving tarsal and carpal bones in children who also get hypertension and azotemia and who die in early adult life. It is not inherited and is without angioma.
4. Hemangiomas with massive osteolysis; a congenital proliferation of blood vessels in skin, subcutaneous tissue, muscle, and bone. When it involves a limb, the bone may disappear.
5. Massive osteolysis where single or adjacent bones are involved by angioma with resulting demineralization and atrophy. The patient described here is an unusual example of this condition.

Osteolysis of the massive type was first described by Jackson (1838) as "A singular case of absorption of bone (a boneless arm)". Further examples of this entity have been published under a variety of descriptive titles that include: vanishing bone disease, phantom bone, cryptogenic osteolysis, spontaneous resorption of bone, essential osteolysis, acute spontaneous absorption of bone, progressive atrophy of bone, hemangiomas, and lymphangiectasis. However, the publications of Gorham et al (1954, 1955) established this phenomenon as a distinct clinical, radiological, and pathological entity under the name of massive osteolysis, subsequently giving rise to the eponym "Gorham's Disease".

The disease is characterized by spontaneous and massive osteolysis and occurs most commonly in adolescents and young adults. Typically, the involved bone shows prominent thin-walled vessels, usually containing blood, occupying the trabecula spaces, as was seen in the bone removed from the foramen magnum. Though it is rare to see microscopic evidence of endothelial proliferation, the adjacent trabeculae are eventually resorbed. Osteoblastic activity is readily apparent, yet osteoclasts are rarely seen. The result is replacement of the bone by vascularized dense fibrous tissue, as

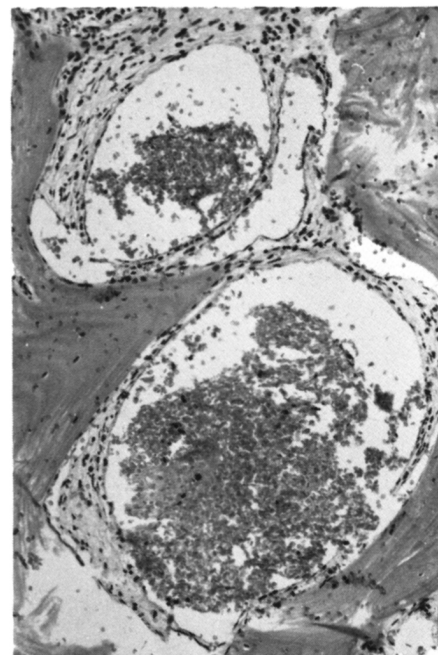


Figure 6 Specimen of bone from edge of foramen magnum shows prominent thin-walled vascular channels lined by flattened endothelial cells containing blood replacing the marrow between bony trabeculae. HE x 50

typified by the tissue removed at the first operation.

At operation, the bone may be soft and of a spongy texture. The cortex is markedly thinned and the marrow brown. There is often an apparent increase in vascularity which may not be confined to the bone, but may extend into adjacent soft tissue and even involve neighboring bones.

Although most patients develop the disorder before the third decade, the disease has occurred from eighteen months to 60 years of age. There is no evidence of genetic transmission, sex or racial predilection, nor associated endocrine or metabolic abnormalities. The frequency of bony involvement as indicated by Johnson and McClure (1958) is: clavicle, scapula, proximal end of humerus, ilium, ischium, and sacrum. Of the approximately 60 cases described by 1978, only about thirteen involved the vertebral column and/or skull, often in a minor way.

The disorder begins insidiously with pain, is chronic, and is characterized by progressive regional loss of bone with resulting deformity, atrophy, or

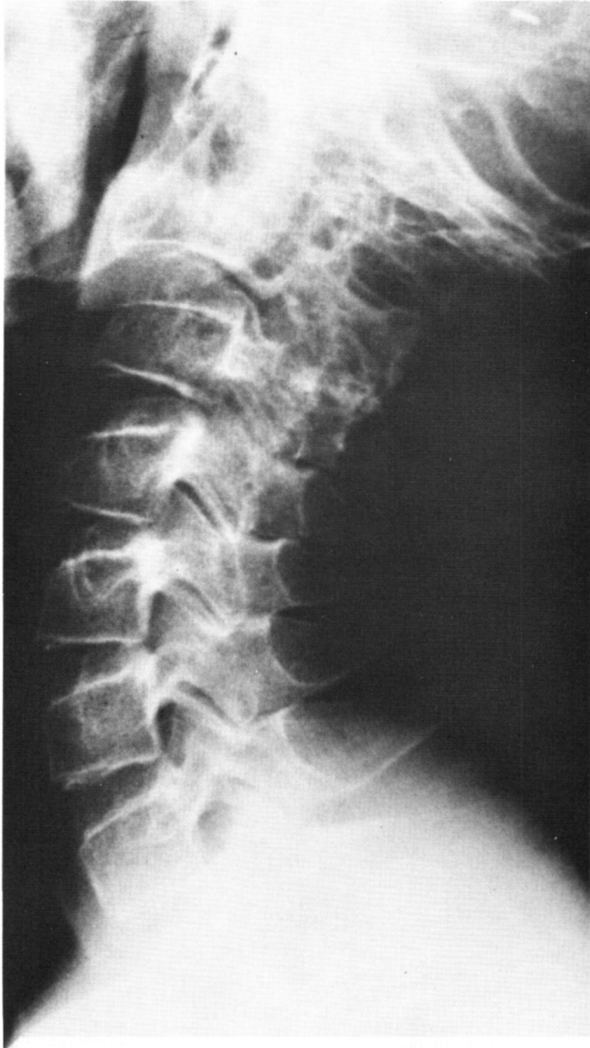

Figure 7a — Lateral cervical spine x-ray on May 1, 1978, showing lysis of posterior arches of C1, C2, and C3.

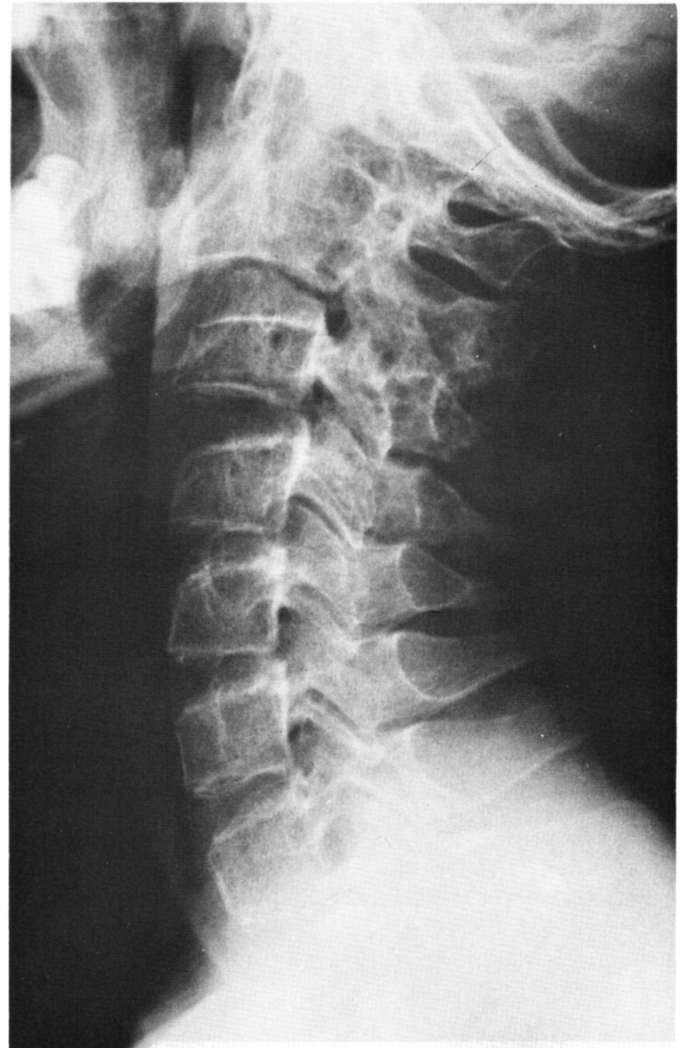

Figure 7b — Lateral cervical spine x-rays on June 18, 1979, showing reossification of posterior arches of C1, C2, and C3.

limitation of motion of the part. Despite this, patients are frequently left with little disability because the dense fibrous tissue can replace the bone and contribute to the maintenance of internal rigidity of the affected area. On occasion, serious sequelae have occurred. Patients with rib involvement can collapse their thoracic cages and present with respiratory impairment, while those with vertebral involvement have occasionally developed spinal cord compression and paraplegia from collapse (Reiley et al, 1972).

The process usually arrests spontaneously after a variable time. New bone formation with ossification does

not occur after such arrest (Halliday et al, 1964).

ETIOLOGY

Although recognized as a distinct clinical, radiological and pathological entity, the true nature of this condition remains unclear. King (1946) introduced the term "hemangiomas" on observing non-neoplastic proliferation of blood vessels in osteoporotic bone. Thomson and Schurman (1974) suggested the disease was a primary aberration of vascular tissue and bone related to unchecked granulation-like tissue, since patients with this disease can present with a history of trauma which allegedly triggered the disease.

Whether an underlying vascular malformation is already present in the bone or adjacent tissues prior to the onset of the osteolysis, remains unknown. Localized vascular malformations within bone are well recognized entities and if irradiated may thrombose and regress. However, these latter lesions are most frequent in the vertebral column and skull (Sherman, 1944) which is not the typical distribution of massive osteolysis. Furthermore, massive osteolysis has shown a poor response to irradiation.

Trauma has been suggested as a possible stimulus, and thus Lichtenstein (1965) regards massive osteolysis as a more severe expression of trauma

that gives rise to local osteolysis of bone encountered in Sudeck's atrophy of hand and foot bones and Kimmell's disease of the vertebral body. However, in many instances no evidence of trauma exists and it is considered unlikely that it plays an important role. Gorham (1966) demonstrated that hyperemia induced by experimental tumor implantation causes bone resorption, and that the active hyperemia of the hemangiomas, by acting as a vascular shunt in contact with the bone, would be expected to produce bone resorption. Ross et al (1978) raised the possibility of prostaglandins in the absorption of bone, since prostaglandins have been implicated in bone resorption in rheumatoid arthritis.

Of the cases that have been studied pathologically, the majority have been hemangiomas of bone alone or in association with soft tissue involvement. However, on occasion lymphangiomatous tissue is encountered, as described by Bickel and Broders (1947), Jacobs and Kimmelsteil (1953), and Case I of Halliday et al (1964). The latter authors proposed that congenital nests of lymphatic tissue in bone and soft tissue increase in size to cause destruction of bone by pressure. The first biopsy from our patient showed many coagulum-filled channels indistinguishable from lymphatics, though none were seen in the second biopsy from the foramen magnum, which was a less chronic process, and the soft tissues surrounding the bone were unremarkable. Histochemical and ultrastructural studies (Caulet et al, 1968) have cast little light on the etiology.

TREATMENT

Attempts at treatment of disappearing bone disease with bone graft generally have not been successful. Aston (1958) reported involvement of the bone graft by the osteolytic process. Bronco and DaSilva (1958) tried a variety of methods of management, including hormones, compounds of magnesium and calcium and aluminum, ultraviolet radiation, and various vitamins, as well as transfusions of placental blood and blood from growing young children. None of

these had any effect on the disease. Others have resorted to amputation of severely involved extremities (Sage and Allen, 1974).

Radiotherapy was suggested in the treatment of this disorder (Halliday et al, 1964). Heyden et al (1977) reported on three patients treated with radiotherapy who showed massive new bone formation which they felt was stimulated by the radiotherapy.

In our patient, radiotherapy seemed to arrest the disease and led to virtual re-ossification of the cervical spine in a rather dramatic fashion.

CONCLUSION

Although there has been no report of dural invasion by the vascular tissue of disappearing bone disease, there have been reports of this vascular tissue invading soft tissues adjacent to bone. It is presumed that in our case the vascular hamartoma invaded the dura about the petrous bone, creating the picture seen on X-ray. This led to the adherence of brain to the invaded dura and the fistulae. A similar process no doubt occurred in the region of the sella leading to the fistula through the sphenoid sinus into the nose. Operative patching of the fistulae effectively ended the rhinorrhea and the risk of meningitis. Radiotherapy appears to have successfully arrested the disease.

DISCUSSION BY PROFESSOR T. P. MORLEY

Since I have no experience of this particular condition, I shall have to limit myself to a few general remarks on C.S.F. fistulae.

1. As soon as C.S.F. rhinorrhea is identified, diagnostic steps must immediately be taken to trace the site of the fistula. When the flow stops, there is no certain method of telling where it came from and if the site of the fistula cannot be localized, more extensive exploratory surgery than would otherwise be required may have to be undertaken.

2. In most cases, an intradural exploration for the fistula is advisable, rather than extradural or trans-nasal. The intradural exposure gives a far wider view of the cranial fossa floor. Extradural exposure often results in

surgically-induced tears in the dura. An approach through the para-nasal air sinuses can be satisfactory if one fistula, and only one, has been accurately identified. In fistulae involving the sphenoid sinus, the trans-sphenoidal view may be better than the intracranial. The sphenoid sinus presents in all five cranial fossae (right and left anterior, right and left temporal, and posterior) and the fistula may occur through any of these presenting surfaces. Close cooperation between rhinologists and neurosurgeon is important.

The sphenoid sinus may be less suitable for repair from within if it has lateral extensions reaching out into the floor of the middle fossa. These cannot be seen through the usual trans-sphenoidal approach, and packing the sinus may result in the isolation of a lateral extension with mucocele formation and possible infection. I have not encountered this development, but it is a possibility.

3. Dr. Douglas Snell and I have, almost without exception, used and preferred the intrathecal fluorescein dye technique in more than 100 cases. We find the fistula easier to identify with fluorescein than with other dyes or with radioactive tracers. It is not neurotoxic if used in diagnostic doses (0.25 - 0.5 ml of 5% fluorescein generously mixed with C.S.F. before injection into the subarachnoid space). Carefully pre-positioned pledgets covering each nasal stoma are labelled and, when withdrawn, examined under the ultra-violet light. While it is not a difficult technique, it must be done precisely, otherwise it will not impart the correct information. At least four hours should elapse between instillation of fluorescein and withdrawal of the pledgets.

4. Unless there is a very special reason for giving it, the prophylactic administration of antibiotics in cases of non-infected C.S.F. fistulae through the skull base should be resisted.

REFERENCES

- ASTON, J. N. (1958). A case of massive osteolysis of the femur. *J. Bone Joint Surg.*, 40B, 514.
BICKEL, W. H. and BRODERS, A. C. (1947).

- Primary lymphangioma of ilium. Report of a Case, *J. Bone and Joint Surg.*, 29, 517.
- BRANCO, F. and DaSILVA, H. J. (1958). Notes on a rare case of essential osteolysis, *J. Bone Joint Surg.*, 40B, 519.
- CAULET, T., FANDRE, M., ADNET, J. J., COFFIN, R., PENNAFORTE, F. and MATHEY, J. (1968). Osteolyse massive scapulo-cleido-costale. Étude histochemique et ultrastructurale, *Ann. d'Anat. Path.*, 13, 177.
- FORNASIER, V. L. (1970). Hemangiomas with massive osteolysis, *J. Bone Joint Surg.*, 53B, 444.
- GORHAM, L. W., WRIGHT, A. W., SHULTZ, H. H. and MAXON, F. C., JR. (1954). Disappearing Bones: A rare form of massive osteolysis. Report of two cases, one with autopsy findings, *Am. J. Med.*, 17, 674-682.
- GORHAM, L. W. and STOUT, A. P. (1955). Massive osteolysis, *J. Bone Joint Surg.*, 37A, 985.
- GORHAM, L. W. (1966). Circulatory changes associated with osteolytic and osteoblastic reactions, *Arch. Int. Med.*, 105, 199.
- HALLIDAY, D. R., DAHLIN, D. C., PUGH, D. G. and YOUNG, H. H. (1964). Massive osteolysis and angiomatosis, *Radiology*, 82, 637-644.
- HEYDEN, G., KINDBLOM, L. G. and NIELSEN, J. M. (1977). Disappearing bone disease, *J. Bone Joint Surg.*, 59A, 57-61.
- JACKSON, J. B. S. (1838). A singular case of absorption of bone (a boneless arm), *Boston Med. Surg. J.*, 18, 368.
- JACOBS, J. E. and KIMMELSTIEL, P. (1953). Cystic angiomatosis of the skeletal system, *J. Bone Joint Surg.*, 35A, 409.
- JOHNSON, P. M. and McCLURE, J. G. (1958). Observations on massive osteolysis, *Radiology*, 71, 28.
- KING, D. J. (1946). Case resembling hemangiomas of the lower extremity, *J. Bone Joint Surg.*, 28, 623.
- LICHTENSTEIN, L. (1965). *Bone tumours*, St. Louis, The C. V. Mosby Co.
- REILEY, B. J., DAVIDSON, J. W., BAIN, H. (1972). Lymphangiectasis of the skeleton — a case report, *Radiology*, 103, 385.
- ROSS, J. L., SCHINELLA, R. and SHENKMAN, L. (1978). Massive osteolysis. An unusual cause of bone destruction, *Am. J. of Med.*, 65, 367-372.
- SAGE, M. R., ALLEN, P. W. (1974). Massive osteolysis, *J. Bone Joint Surg.*, 56B, 130.
- SHERMAN, M. W. (1944). Capillary hemangioma of bone, *Arch. Path.*, 38, 158.
- THOMPSON, J. W. and SCHURMAN, D. J. (1974). Massive osteolysis, *Clin. Orthop.*, 103, 206.