

## Original Article

# The Value of Etoposide for Recurrent Glioma

Matthijs van der Meulen<sup>1,2</sup> , Manik Chahal<sup>1,3</sup> and Warren P. Mason<sup>1</sup>

<sup>1</sup>Departments of Neurology and Medical Oncology and Hematology, Princess Margaret Cancer Centre, University of Toronto, Toronto, ON, Canada, <sup>2</sup>Department of Neurology, Medisch Spectrum Twente, Enschede, The Netherlands and <sup>3</sup>Department of Medical Oncology, BC Cancer Vancouver Centre, Vancouver, BC, Canada

**ABSTRACT: Background:** For multiply recurrent glioma, options are few and choices are very limited. Etoposide in combination with carboplatin and/or bevacizumab has been evaluated in recurrent glioma with modest efficacy. This retrospective study describes the efficacy of etoposide monotherapy in adults with multiply recurrent diffuse glioma. **Methods:** In this single center retrospective series, all adult patients with radiographically proven multiply recurrent diffuse glioma (WHO grade 2–4) treated with etoposide between 2016 and 2020 were evaluated. Progression-free survival (PFS) and overall survival (OS) after initiating etoposide were calculated for the total group and for different histologic tumor types. In addition, treatment-related toxicity was recorded. **Results:** Totally, 48 patients with a median age 43 years-old (range 24–78) were included. Etoposide was given as 3rd line of treatment in 18 patients (37.5%) and as 4th or 5th line of treatment in 30 patients (62.5%). The majority were diagnosed with a glioblastoma, WHO grade 4 (27, 56.3%). The median PFS was 8.6 weeks (95% confidence interval [CI]: 8.3–8.9). The median OS of the total population was 4.0 months (95% CI: 2.4–5.6). Patients with an oligodendroglioma had the best OS (median 13 months), compared to astrocytoma and glioblastoma, but the difference was not statistically significant ( $p = 0.15$ ). Etoposide was stopped due to progression in the majority of the patients (81.3%). Only 1 patient had a grade 3 toxicity. **Conclusion:** Etoposide is a well-tolerated chemotherapy in heavily pretreated patients with multiply recurrent glioma and could be considered when other options are not available. OS was 4 months after initiating etoposide.

**RÉSUMÉ : L'intérêt de l'étoposide dans le cas des gliomes récurrents** *Contexte :* Dans le cas des gliomes récurrents multiples, les options thérapeutiques sont peu nombreuses et les choix très limités. L'étoposide, en association avec le carboplatine et/ou le bévacizumab, a été évalué dans le cas des gliomes récurrents, son efficacité ayant été jugée modeste. Cette étude rétrospective entend décrire l'efficacité de l'étoposide en monothérapie chez des adultes atteints de gliome diffus dont la récurrence est multiple. *Méthodes :* Dans cette série rétrospective monocentrique, tous les patients adultes atteints de gliome diffus (récurrence multiple) prouvés par radiographie (grades 2 à 4 de l'OMS) et traités au moyen de l'étoposide entre 2016 et 2020 ont été évalués. La survie sans progression (SSP) et la survie globale (SG) après l'amorce d'un traitement d'étoposide ont été calculées pour l'ensemble du groupe et pour les différents types histologiques de tumeurs. En outre, la toxicité liée au traitement a été consignée. *Résultats :* Au total, 48 patients de 24 à 78 ans dont l'âge médian était de 43 ans ont été inclus dans cette étude. L'étoposide a été administré à titre de troisième ligne de traitement chez 18 patients (37,5 %) et à titre de quatrième ou de cinquième ligne de traitement chez 30 patients (62,5 %). La majorité des patients avaient été diagnostiqués avec un glioblastome de grade 4 selon l'OMS ( $p = 27$ , soit 56,3 %). La SSP médiane était de 8,6 semaines (IC 95 % : 8,3 - 8,9). La SG médiane de la population totale était de 4,0 mois (IC 95 % : 2,4 - 5,6). Par rapport à l'astrocytome et au glioblastome, les patients atteints d'un oligodendrogliome ont donné à voir la meilleure SG (médiane de 13 mois) même si la différence n'était pas statistiquement notable ( $p = 0,15$ ). Enfin, notons que l'étoposide a été arrêté en raison d'une progression de la maladie chez la majorité des patients (81,3 %) et qu'un seul patient a présenté une toxicité de grade 3. *Conclusion :* L'étoposide est une chimiothérapie bien tolérée chez les patients lourdement prétraités atteints de gliomes dont la récurrence est multiple. Il pourrait être envisagé lorsque d'autres options thérapeutiques ne sont pas disponibles. À noter que la SG a été de 4 mois après le début d'un traitement d'étoposide.

**Keywords:** Glioma; recurrent; etoposide; chemotherapy

(Received 14 June 2023; final revisions submitted 19 July 2023; date of acceptance 10 August 2023; First Published online 29 August 2023)

## Introduction

Guidelines for treatment of diffuse glioma in adults at diagnosis and at first recurrence are well established.<sup>1,2</sup> However, there is no general

consensus on how to treat further recurrences of glioma. Patient-related factors and the effect of previous treatments influence the decision for re-resection, radiotherapy, and/or further lines of systemic therapy. Although re-resection or radiation might be

**Corresponding author:** M. van der Meulen; Email: [matthijs.vandermeulen@mst.nl](mailto:matthijs.vandermeulen@mst.nl)

**Cite this article:** van der Meulen M, Chahal M, and Mason WP. (2024) The Value of Etoposide for Recurrent Glioma. *The Canadian Journal of Neurological Sciences* 51: 509–512, <https://doi.org/10.1017/cjn.2023.276>

© The Author(s), 2023. Published by Cambridge University Press on behalf of Canadian Neurological Sciences Federation. This is an Open Access article, distributed under the terms of the Creative Commons Attribution licence (<http://creativecommons.org/licenses/by/4.0/>), which permits unrestricted re-use, distribution and reproduction, provided the original article is properly cited.

**Table 1:** Baseline characteristics of patients treated with etoposide

Baseline Patient Characteristics	N = 48 patients	
	N	% Total
Age (median, range)	43 (24–78)	
Age $\geq$ 65	4	8.3
Sex (F)	15	31.3
Pathology		
Grade 4 glioma (IDH wt, mutant, or unknown)	27	56.3
Grade 2/3 astrocytoma (IDH wt, mut, or unknown)	12	25.0
Oligodendroglioma (or oligoastrocytoma)	9	18.8
Other (PXA)	1	2.1
Extent of resection		
Biopsy	8	16.7
Partial resection	27	56.3
Gross total resection	11	22.9
Unknown	2	4.2
MGMT status		
Unmethylated	11	22.9
Methylated	4	8.3
Unknown	33	68.8

considered, these options are of limited impact due to an unfavorable prognosis and potential complications and toxicities. Options for systemic therapy for patients with multiply recurrent gliomas are limited, and few trials have been conducted for glioma beyond first progression. Prior cohort studies have evaluated the effect of etoposide combined with carboplatin in heavily pretreated patients with glioma.<sup>3–5</sup> There are no data available on the efficacy of oral etoposide monotherapy in recurrent glioma. This retrospective study evaluated the efficacy and toxicity of oral etoposide chemotherapy for multiply recurrent WHO grade 2–4 diffuse glioma.<sup>6</sup>

## Methods

In this retrospective, single-center observational cohort study, we included all adult ( $\geq$ 18 years-old) patients diagnosed with a histologically proven diffuse glioma (WHO grade 2–4) and with a radiographically proven recurrent diffuse glioma, treated with oral etoposide chemotherapy between January 2016 and December 2020 at the Princess Margaret Cancer Centre, Toronto, Canada. Patient-related characteristics (sex, age at diagnosis, and performance status before starting etoposide) and tumor characteristics (tumor type: astrocytoma/oligodendroglioma/glioblastoma, WHO grade, and MGMT methylation status) were collected from chart analysis. Detailed treatment history (extent of resection, previous chemotherapy and radiation) was obtained. Oral etoposide was given at a dose of 50mg/m<sup>2</sup> for 21 days of a 28-day cycle. PFS was defined as time from starting etoposide to radiographic progression or death from any cause. OS was defined as time from starting etoposide to death from any cause.

Survival was calculated for the total cohort and separately for oligodendroglioma (grade 2 or 3), astrocytoma (grade 2 or 3), and glioblastoma (grade 4) as defined by the 2016 WHO guidelines. These categories were based on histological information, since molecular data were not available on all samples. Survival was also

**Table 2:** Etoposide treatment details. \*The administration of bevacizumab monotherapy could be before or after the administration of etoposide, or both

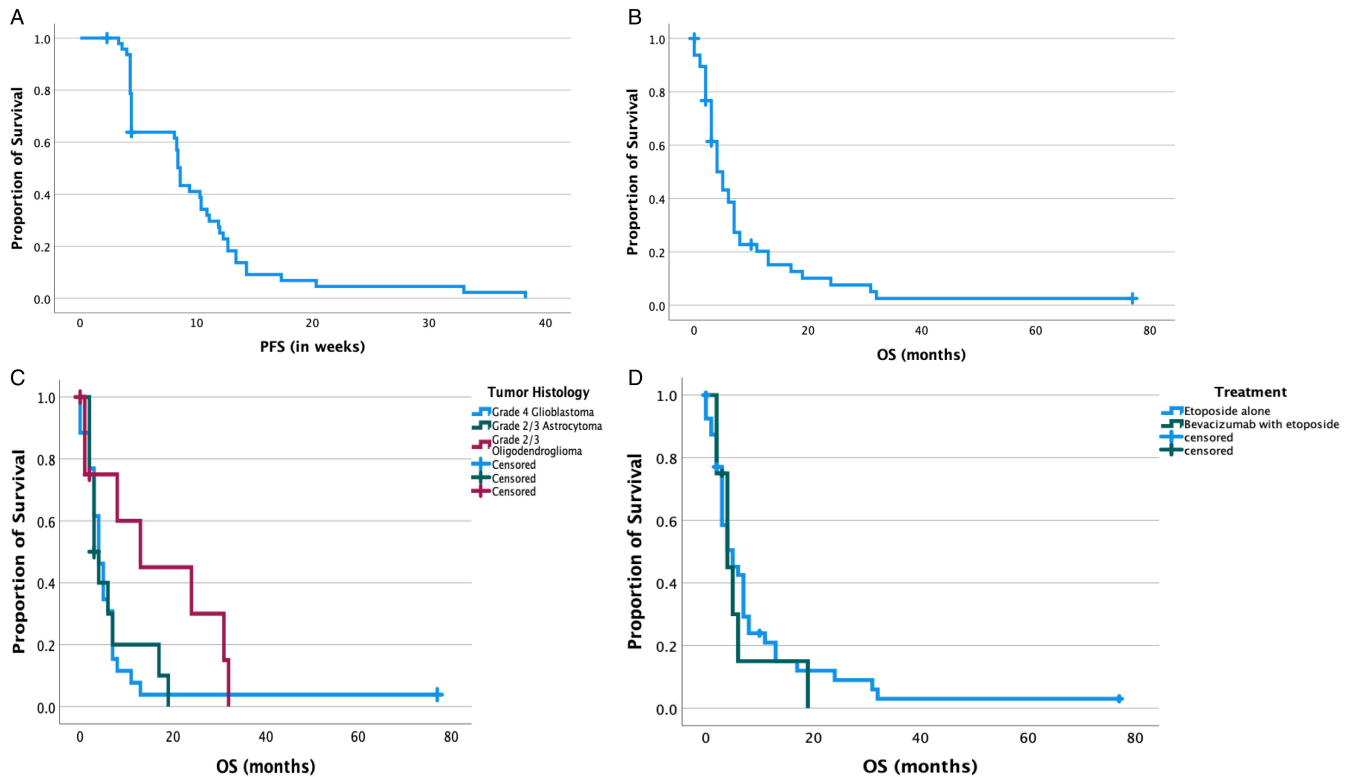
Etoposide Treatment	N	% Total
Which line was etoposide used		
2nd line	0	0.0
3rd line	18	37.5
4th line	16	33.3
5th line	14	29.2
Reason for etoposide discontinuation		
Progression	39	81.3
Toxicity	5	10.4
Loss to follow up/unknown	4	8.3
Bevacizumab used with etoposide		
Yes	8	16.7
No (bevacizumab used alone*)	19	39.6
Bevacizumab not used	21	43.8

analyzed for those who received etoposide monotherapy versus those who received bevacizumab concurrently. Survival analyses were done with the Kaplan–Meier method with a 95% confidence interval (CI). Differences between groups were calculated with a log-rank test. Toxicity (anemia, neutropenia, thrombocytopenia, kidney, and liver function) was graded according to the Common Terminology Criteria for Adverse Events v5.0 (CTCAE). The study was approved by the Institutional Research Board of the University Health Network, Toronto, Ontario, Canada.

## Results

We included 48 patients (31.3% female) with a median age of 43 years-old (range 24–78) at the time of diagnosis; only four patients were  $\geq$ 65 years old. The majority were diagnosed with grade 4 glioblastoma (27 patients, 56.3%), followed by astrocytoma grade 2 or 3 (12 patients, 25.0%), and oligodendroglioma (9 patients, 18.8%); one patient was diagnosed with pleomorphic xanthoastrocytoma (PXA). O6-methylguanine-DNA methyl-transferase (MGMT) methylation status was known for 15 patients, with 4 patients having hypermethylated MGMT (Table 1).

All patients received radiotherapy (with or without concurrent temozolomide) and adjuvant temozolomide as first-line therapy. And, all but four patients were also treated with lomustine before etoposide was given. Furthermore, depending on the pathological diagnosis, a variety of other treatments, including procarbazine, lomustine, and vincristine (PCV)-chemotherapy, and trial medication were given prior to etoposide. Etoposide was given as third-, fourth-, or fifth-line treatment in 37.5%, 33.3%, and 29.2% of the patients, respectively. The vast majority (32 patients, 66.7%) received 1–2 cycles of etoposide. All patients received 50 mg/m<sup>2</sup> for 21 days of a 28-day cycle; 16 patients received  $>$ 2 cycles (range 3–7). Only two patients received a lower dose because of minor toxicities. Etoposide was combined with bevacizumab in 8 patients. Etoposide was stopped because of progression in 39 patients (81.3%) and in 5 (10.4%) because of toxicity. Four patients were censored after being lost to follow-up. Only one patient had grade 3 toxicity (anemia), Table 2. Twenty-two patients (45.9%) received another line of treatment after etoposide was stopped, and the remaining 26 patients were transferred to palliative care. From



**Figure 1:** a) the progression free survival (PFS) in weeks and b) overall survival (OS) in months in the total cohort after initiating etoposide. c) The overall survival in months in glioblastoma, WHO grade 4 (blue line), astrocytoma, WHO grade 2 or 3 (green line), and oligodendroglioma WHO grade 2 or 3 (pink line) after initiating etoposide. d) The overall survival in months of patients treated with etoposide monotherapy and with concurrent bevacizumab.

those who received salvage therapy after etoposide, 10 received bevacizumab, 8 received procarbazine monotherapy, another 2 received lomustine, and the remaining two patients received a second radiation, one with and one without a re-challenge of temozolomide.

For the total cohort, the median PFS after initiating etoposide was 8.6 weeks (95% CI: 8.3–8.9), and OS after initiating etoposide was 4.0 months (median, 95% CI: 2.4–5.6, Fig. 1a, b). The OS after initiating etoposide in patients with oligodendroglioma was better with a median OS (95% CI) of 13 months (0.7–25.3), compared to those with an astrocytoma (3 months, 1.3–4.6) or a glioblastoma (4 months, 2.6–5.4, Fig. 1c). The difference in OS between these three groups was not statistically significant ( $p = 0.15$ ). Bevacizumab was combined with etoposide in only 8 patients, and OS was not significantly different from those who received etoposide monotherapy (median 4 vs 5 months,  $p = 0.61$ , Fig. 1d). There is no statistically significant difference in OS between those who received etoposide as 3<sup>rd</sup>, 4<sup>th</sup>, or 5<sup>th</sup> line of treatment, median OS (95% CI): 5 months (2.2–7.7), 6 months (0.0–14.6), 3 months (1.5–4.5), respectively ( $p = 0.105$ ).

## Discussion

In this single center cohort study, we demonstrated that, in heavily pretreated patients with multiply recurrent diffuse glioma who had very limited therapeutic options, oral etoposide was well tolerated. The overall survival in this heterogeneous cohort was 4 months. The PFS we observed for this cohort is similar to what has been reported in two other smaller studies.<sup>3,4</sup> The OS was slightly higher

(median 9–10 months) in other studies.<sup>3,5</sup> In all studies, the effect of etoposide in multiply recurrent glioma was analyzed retrospectively. In one study, 47 patients, mainly with a WHO grade 4 glioma, were treated with carboplatin and etoposide as third or fourth line of salvage treatment and the investigators found a PFS of 3 months and an OS of 9 months in the total population, but with better outcomes for grade 2 and 3 glioma: PFS of 4 months and an OS of 13 months. The survival in the grade 4 glioma is slightly higher than in our cohort, which might be explained by the combination of etoposide with carboplatin. The results in lower grade glioma are similar to our population.<sup>3</sup> Another smaller ( $n = 12$ ) European study analyzed the effect of bevacizumab in combination with etoposide in heavily pretreated patients with high-grade glioma and found a PFS of 2.5 months and an OS of 3.3 months, which is slightly lower than we found in our population.<sup>4</sup> Notably, these prior studies looked at etoposide in combination with other agents and not as monotherapy. The toxicity was much higher (CTCAE grade 3 or 4 in 30%–67% of the patients).<sup>4,5</sup> However, in all these studies, etoposide was combined with carboplatin in recurrent glioma patients.<sup>3–5</sup> Although just 9 patients with an oligodendroglioma were included in this study, interestingly, we observed a median OS of 13 months. This could be explained by oligodendrogliomas being more chemosensitive<sup>7,8</sup> and having a better prognosis overall.

In this study of a highly selected heterogeneous group of patients, who received a median of 1 cycle of oral etoposide, this therapy was well tolerated, and appears to have a better toxicity profile than temozolomide and lomustine. Only 1 patient in our cohort had a grade 3–4 toxicity (2.1%), compared to historical

studies showing grade 3–4 toxicities in 14% of patients treated with temozolomide and up to 25% in patients treated with lomustine.<sup>9,10</sup> This study has demonstrated that etoposide can be administered safely as 3<sup>rd</sup>, 4<sup>th</sup>, or 5<sup>th</sup> line treatment. Given that survival was not influenced by timing of etoposide treatment, our results do not suggest an optimal time to use etoposide. In addition, previous treatment with multiple lines of systemic treatments might have influenced the response to etoposide. Since treatment options are few and limited in multiply recurrent glioma patients and lack of better drugs, our results suggest that etoposide is an option following second recurrence.

Limitations of this analysis include the small cohort of selected patients and the fact that most patients received just 1 or 2 cycles of etoposide. Etoposide was only given when no other systemic or local options were available. Moreover, due to the retrospective nature of this series, the interpretation is limited by missing molecular data, including isocitrate dehydrogenase and MGMT methylation status in some patients. However, the role of MGMT status for the effect of etoposide is unclear. Conclusion about the efficacy of etoposide cannot be made, since no comparison with other treatments or best supportive care were made. However, our study is the first series that describes the effect of a relatively tolerable regimen with oral etoposide alone in adults with a recurrent diffuse glioma.

### Conclusion

Oral etoposide is a well-tolerated chemotherapy in adult patients with a recurrent diffuse glioma. The treatment should be considered in very poor prognosis patients, provided their performance status is sufficient to receive another line of chemotherapy.

**Acknowledgments.** None.

**Competing interests.** Dr Warren Mason reports consulting for Servier, Novocure, Merck, Boehringer Ingelheim, and AnHeart Therapeutics, fees paid to the institution. The other authors declare no conflicts of interest relevant for this work.

**Statement of authorship.** MvdM: collected and interpreted the data, wrote the first version of the manuscript, MC: analyzed and interpreted the data, revised the manuscript, WPM: interpreted the data and supervised this study.

### References

1. Weller M, van den Bent MJ, Preusser M, et al. EANO guidelines on the diagnosis and treatment of diffuse gliomas of adulthood. *Nat Rev Clin Oncol.* 2021;18:170–86.
2. Mohile NA, Messersmith H, Gatson NT, et al. Therapy for diffuse astrocytic and oligodendroglial tumors in adults: ASCO-SNO guideline. *J Clin Oncol.* 2022;40:403–26.
3. Chen J, Zhao Y, Hou Z, et al. Combined carboplatin and etoposide chemotherapy for patients with recurrent glioma. *Ann Palliat Med.* 2021;10:12650–6.
4. Tonder M, Weller M, Eisele G, Roth P. Carboplatin and etoposide in heavily pretreated patients with progressive high-grade glioma. *Chemotherapy.* 2014;60:375–8.
5. Franceschi E, Cavallo G, Scopece L, et al. Phase II trial of carboplatin and etoposide for patients with recurrent high-grade glioma. *Br J Cancer.* 2004;91:1038–44.
6. WHO Classification of Tumours Editorial Board. World health organization classification of tumours of the central nervous system. 5th edn. Lyon: International Agency for Research on Cancer; 2021.
7. van den Bent MJ, Carpentier AF, Brandes AA, et al. Adjuvant procarbazine, lomustine, and vincristine improves progression-free survival but not overall survival in newly diagnosed anaplastic oligodendrogliomas and oligoastrocytomas: a randomized european organisation for research and treatment of cancer phase III trial. *J Clin Oncol.* 2006;24:2715–22.
8. Cairncross G, Berkey B, Intergroup Radiation Therapy Oncology Group Trial 9402, et al. Phase III trial of chemotherapy plus radiotherapy compared with radiotherapy alone for pure and mixed anaplastic oligodendroglioma: Intergroup Radiation Therapy Oncology Group Trial 9402. *J Clin Oncol.* 2006;24:2707–14.
9. Stupp R, Mason WP, van den Bent MJ, et al. Radiotherapy plus concomitant and adjuvant temozolomide for glioblastoma. *N Engl J Med.* 2005;352:987–96.
10. Weller M, Le Rhun E. How did lomustine become standard of care in recurrent glioblastoma? *Cancer Treat Rev.* 2020;87:102029.