

Tests of Motor Function in Patients Suspected of Having Mild Unilateral Cerebral Lesions

Jeanne S. Teitelbaum, Michael Eliasziw, Michael Garner

ABSTRACT: *Objective:* Though various textbooks describe clinical manoeuvres that help detect subtle motor deficits, their sensitivity, specificity and predictive values have not been determined. We investigated the sensitivity, specificity and predictive values of various manoeuvres in order to determine the most sensitive and reliable test or combination thereof. *Methods:* Straight arm raising (Barré), pronator drift, Mingazzini's manoeuvre, finger tap, forearm roll, segmental strength and deep tendon reflexes were tested in 170 patients with (86) and without (84) a proven lesion in the motor areas confirmed by computed tomography. *Results:* Segmental motor strength had good specificity (97.5%) but poor sensitivity (38.9%) and negative predictive value (NPV) (58.7%). The forearm roll had a similar profile. Finger tap had a sensitivity of 73.3% and a specificity of 87.5%. Barré and pronator testing had a sensitivity and specificity of 92.2% and 90.0% respectively. Hyperreflexia had a sensitivity of 68.9% and a specificity of 87.5%. An abnormality of pronator, reflexes or finger tap had a sensitivity of 97%, and when these three tests were positive, specificity was 97%. When all six tests were positive, the positive predictive value was 100%, when all six tests were negative the NPV was 100%. *Conclusion:* The detailed segmental examination has very good specificity for detecting motor deficits, but the sensitivity and NPV are unacceptably low. Pronator drift with finger tap and reflexes is the most reliable and time-effective combination of tests for the detection of subtle motor lesions, and could replace the segmental motor examination as a screening for motor lesions.

RÉSUMÉ: *Épreuves de fonction motrice chez les patients chez qui on soupçonne la présence de lésions cérébrales unilatérales légères. Objectif:* Bien que différents manuels décrivent les manœuvres cliniques qui aident à détecter des déficits moteurs subtiles, leur sensibilité, leur spécificité et leur valeur prédictive n'ont pas été déterminées. Nous avons examiné la sensibilité, la spécificité et la valeur prédictive de différentes manœuvres dans le but de déterminer quel est l'épreuve ou la combinaison d'épreuves la plus sensible et fiable. *Méthodes:* Le chute lente d'un bras maintenu en extension (Barré), le pronation involontaire d'un bras maintenu en extension, la manœuvre de Mingazzini, le finger tap, le forearm roll, la force segmentaire et les réflexes ostéotendineux ont été évalués chez 170 patients avec (86) et sans (84) lésion prouvée dans les zones motrices, confirmées par CT scan. *Résultats:* La force motrice segmentaire avait une bonne spécificité (97,5%) mais une faible sensibilité (38,9%) et une valeur prédictive négative (VPN) (58,7%). Le forearm roll avait un profil semblable. Le finger tap avait une sensibilité de 73,3% et une spécificité de 87,5%. Le Barré et le pronator drift avaient une sensibilité et une spécificité de 92,2% et 90,0% respectivement. L'hyperréflexie avait une sensibilité de 68,9% et une spécificité de 87,5%. Une anomalie du pronateur, des réflexes ou du finger tap avait une sensibilité de 97% et, quand ces épreuves étaient toutes positives, une spécificité de 97%. Quand les 6 épreuves étaient positives, la valeur prédictive positive (VPP) était de 100%, alors que quand les 6 épreuves étaient négatives, la VPN était de 100%. *Conclusion:* L'examen segmentaire détaillé a une très bonne spécificité pour détecter les déficits moteurs, mais la sensibilité et la VPN sont faibles et inacceptables. La combinaison d'épreuves la plus fiable et la plus efficace pour détecter des lésions motrices subtiles est le pronator drift, le finger tap et les réflexes. Cette combinaison pourrait remplacer l'examen moteur segmentaire comme outil de dépistage de lésions motrices.

Can. J. Neurol. Sci. 2002; 29: 337-344

A major component of the neurologic evaluation is the evaluation of lateralizing signs, as the detection of even subtle hemiparesis often mandates further investigation. What is the most reliable test or combination of tests to detect subtle pyramidal weakness, or conversely, to eliminate this possibility?

Standard clinical tests to detect such dysfunction include

- 1) downward drift of the outstretched arm (Barré test or arm drift),
- 2) pronation of the outstretched limb (pronator test),
- 3) impaired dexterity of repetitive fine finger movements (FFM),
- 4) increased reflexes and up going toes and
- 5) the segmental motor examination.

More recently, forearm rolling was evaluated as a sign of unilateral cerebral dysfunction.¹

Little exists in the literature regarding sensitivity, specificity and positive and negative predictive values (PPV and NPV) of

From the Maisonneuve-Rosemont Hospital, University of Montreal, Montreal, Quebec (JST), John P Robarts Institute, London, Ontario (ME), Sacré-Coeur Hospital, University of Montreal, Montreal, Quebec (MG) Canada.

RECEIVED JANUARY 11, 2002. ACCEPTED IN FINAL FORM APRIL 24, 2002.

Reprint requests to: Jeanne Teitelbaum, Maisonneuve-Rosemont Hospital, 5415 boul. L'Assomption, Montréal, Québec, Canada H1T-2M4

different clinical manoeuvres used in evaluating upper motor neuron, or pyramidal lesions. Is detailed segmental motor examination the most sensitive, or are there other, more reliable and more sensitive manoeuvres? Some upper motor neuron lesions have only mild clinical manifestations and no significant weakness is apparent. The ideal clinical test would be perfectly sensitive and highly specific, as well as being simple and rapid to administer.

In this study, we set out to determine which test or combination of tests could be proven to be the most accurate and reliable to confirm or exclude the presence of a central motor lesion in patients with little or no weakness on segmental motor exam.

MATERIALS AND METHODS

Study population

We enrolled 170 patients referred to the neurology department of two university hospitals – Maisonneuve-Rosemont Hospital and Notre-Dame Hospital (University of Montreal) – for a suspected abnormality in the central nervous system. After clinical assessment by a neurologist, patients underwent radiological investigation if the neurologist felt that this was warranted to confirm the postulated diagnosis or rule out an underlying cerebral lesion. The patients enrolled in the study had either subtle or no weakness according to the neurologist who assessed them (4/5 or higher on segmental motor exam), and required a computed tomography (CT) scan for diagnostic purposes. The patient had to be alert enough to cooperate with the various manoeuvres and had to be seen by at least one of the study examiners. Patients in whom the final diagnosis was of a non-neurological nature, or due to nonorganic illness (somatisation or hysteria) were included as well as those with traditional illnesses of the nervous system. Patients who did not have an imaging study, or in whom the diagnosis was uncertain, were excluded. Looking at a daily sample, approximately 20% of the patients seen on any particular day could not be included according to these criteria. Once entered into the study, the patients were stratified as normal or abnormal according to the following:

Inclusion criteria for the abnormal group:

- Patients with a hemispheric lesion involving the motor pathways.
- Lesion confirmed by CT or magnetic resonance imaging (MRI) of the brain.
- Normal strength or mild weakness, according to assessment of segmental strength (motor score of 4/5 or higher for all muscle groups).

Inclusion criteria for patients in the control group:

- Patients referred to neurology, assessed and diagnosed by the neurologist.
- Normal strength or mild weakness according to assessment of segmental strength (motor score of over 4/5 for all muscle groups).
- CT or MRI scan of the brain performed as part of the diagnostic work-up (differential diagnosis) and interpreted as normal.

The diagnoses in both groups are outlined in Table 1. The majority of the lesions on CT are strokes (61), haemorrhage (10)

Table 1: Diagnoses of patient population

	CT+ 86 patients	CT- 84 patients
Age	56.87	52.4
Male : female	1.8/1	1.3/1
Mass lesion (13 patients)	13	0
CVA/lacune (61 patients)	60	1
Haemorrhage (10 patients)	10	0
TIA (28 patients)	0	28
Migraine (26 patients)	0	26
Cranial nerve palsy * (7 patients)	0	7
Vertigo (7 patients)	0	7
Miscellaneous (10 patients)	3	7
Non-neurological (8 patients)	0	8

* Causes include diabetes, hypertension, Bell's palsy, post-viral infection

CVA cerebrovascular accidents
TIA transient ischemic attack

and mass lesions (13). Most of the mass lesions were cortical whereas the strokes and hemorrhages were mainly sub-cortical.

Exclusion criteria for both groups:

- Patients with suspected or proven abnormality of the spinal cord or the peripheral nervous system. Pain or mechanical limitation of the limbs that limits the patient's ability to perform the various manoeuvres.
- Lack of co-operation (coma, altered state of consciousness, inability to follow commands etc.).
- Previous central nervous system damage that could affect the interpretation of the tests being evaluated.
- The presence of significant cerebellar or sensory abnormalities as well as the presence of abnormal movements that would make the interpretation of the various manoeuvres difficult.

Clinical manoeuvres

All tests were performed using a rigidly defined procedure as variability in technique could influence results. The examiners performing the study manoeuvres were unaware of the patient's diagnosis and CT scan result. In order to assess reproducibility, two independent physicians, both of whom were blinded to the patient's final diagnosis, examined 85 of the 170 patients. Only one of the physicians was an author. The other was a neurologist or a neurological resident whose only function in the study was to perform the assessment according to instructions. Inter-examiner reliability was calculated for the Barré, pronator, segmental motor exam and arm roll test.

The segmental motor exam

Examination of motor strength and power was a variation of that recommended in two neurology textbooks.^{2,3} The authors examined over 100 charts and recorded which muscle groups were usually tested by neurologists looking for central motor lesions. The muscles most often examined were then included for testing in our patient population. The final choice, however,

is more extensive than the usual in order to avoid any negative bias that would result from an incomplete exam. Corresponding muscles on the two sides of the body were always compared. The part of the body to be examined was placed in the position that would permit the muscle to act directly and at the same time inhibit as far as possible the action of muscles of similar function. The proximal portion of the limb was fixed when the movements of the distal portion were being tested. This was not an examination looking for lower motor neuron lesions.

The muscles and muscle groups tested were as follows:

- **Upper extremity**

Shoulder abduction (deltoid), elbow flexion (biceps), elbow extension (triceps), wrist flexion (flexor carpi radialis and ulnaris), wrist extension (extensor carpi radialis and ulnaris), finger flexion (level of the metacarpo-phalangeal joint, flexor digitorum sublimis and profundum) and finger extension (metacarpo-phalangeal joint, extensor digitorum communis).

- **Lower extremity**

Hip flexion (iliacus and psoas), flexion of the leg at the knee (hamstring muscles), extension of the leg at the knee (quadriceps), plantar flexion of the ankle (gastrocnemius, soleus and plantaris), dorsiflexion of the ankle (tibialis anterior) and toe extension and flexion.

Muscle strength was graded out of 5 using the Medical Research Council scale:

- 0 No muscular contraction occurs
- 1 A flicker or trace of contraction is palpated in the absence of apparent movement. Minimal or no motion of joints.
- 2 The muscle moves the part through a partial arc of movement with gravity eliminated.
- 3 The muscle completes the whole arc of movement against gravity but not against resistance.
- 4 The muscle completes the whole arc of movement against gravity together with variable amounts of resistance.
- 5 The muscle completes the whole arc of movement against gravity and maximum amounts of resistance several times without signs of fatigue. This is normal muscular power.

The segmental motor exam was deemed abnormal if two or more of the muscles tested in an extremity were abnormal. Only one extremity needed to be affected.

Barré test (straight arm raising) (Figure 1)

What is referred to as the Barré test was actually first described by Mingazzini and it was performed with the arm fully extended in all joints and the fingers abducted. The wrists were straight and not dorsiflexed as in our version.⁴

The patient is comfortably seated. The arms are held at a 90-degree angle with the body. Elbows are fully extended, the forearm is in pronation, wrists are dorsiflexed, and fingers are extended and abducted. This position is held for as long as the patient is able up to an ideal time of one minute. When the patient cannot sit, the test is done in the supine position and the arms are held at a 45-degree angle to the body. The test is considered positive (or abnormal) if the fingers, wrist or arm start to fall, or if the fingers are unable to maintain abduction. When the problem is due to an upper motor neuron lesion, the fingers and wrists should be affected before the arm begins to drop.

Pronator drift (Figure 2)

The patient is comfortably seated. The arms are held at a 90-degree angle with the body. Elbows are fully extended, forearms are supine, wrists are straight, and fingers are extended and adducted. This position is held for as long as the patient is able up to an ideal time of one minute. When the patient cannot sit, he or she remains supine, and the arms are held at a 45-degree angle to the body.

The test is considered positive when the hand loses its extension and appears hollowed. This may occasionally be preceded by the abduction of the fifth finger (digi quinti sign). Loss of extension of the fingers is followed, if weakness is sufficient, by progressive loss of supination. With either Barré or pronator tests, more severe weakness will cause loss of extension of the elbow, and eventually a fall of the entire arm, but these are absent in mild forms of weakness.

Fine finger movements

The patient is asked to tap his thumb with the index finger of the same hand several times in a row. The movement should have large amplitude with little variation from one repetition to the next and have a speed of approximately two (2) taps per second. A pyramidal lesion will produce slowing and decrease in amplitude of the repetitive movement, which remains regular, with apparent stickiness of the fingers. A cerebellar lesion will produce irregular, imprecise movements.

Forearm roll (Figure 3)

The patient is asked to rapidly roll each forearm around the other for 5 to 10 seconds in each direction. The response is considered to be normal when the arms rotate around one another symmetrically. When the response is abnormal, the healthy arm orbits around the abnormal one like a satellite. We used the procedure described by Sawyer and colleagues in 1993¹.

Mingazzini's manoeuvre (Figure 4)

Mingazzini's original manoeuvre was performed with the patient in the supine position with both legs raised straight in a 45-degree angle from the bed.⁴ This was modified by Barré who placed the patient in a supine position with the legs bent at a 90-degree angle at the hip and the knees.⁴ Our version is a variant of the one performed by Barré. The patient is lying on his/her back. The hips are flexed at a 75 to 80 degree angle, and the knees are held at a 100-degree angle that allows the leg to be horizontal to the bed. Ankles are dorsiflexed at 90 degrees. The position is held for as long as possible to a maximum of 30 seconds. The manoeuvre is positive (or abnormal) if the leg or hip begins to fall or if there is a loss of foot dorsiflexion.

Deep tendon reflexes

Deep tendon reflexes and plantar cutaneous responses were done in the traditional manner. Reflexes that were routinely tested included the triceps, biceps, brachioradialis patellar Achilles and plantar. Reflexes were graded out of 4 as follows:

- 0 Absent
- 1 Present but diminished
- 2 Normal
- 3 Increased but not necessarily to a pathologic degree
- 4 Markedly hyperactive, often with associated clonus.

Abnormality was defined as an abnormal increase in two or

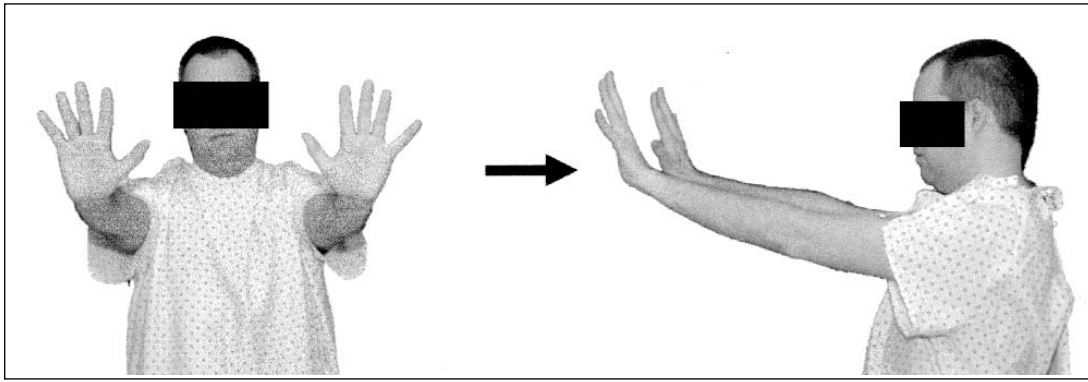


Figure 1: Barré test (straight arm raising). The arms are held at a 90-degree angle with the body. Elbows are fully extended, wrists are dorsiflexed, and fingers are extended and abducted.

Figure 2: Pronator drift. The arms are held at a 90-degree angle with the body. Elbows are fully extended, forearms are supine, wrists are straight, and fingers are extended and adducted.

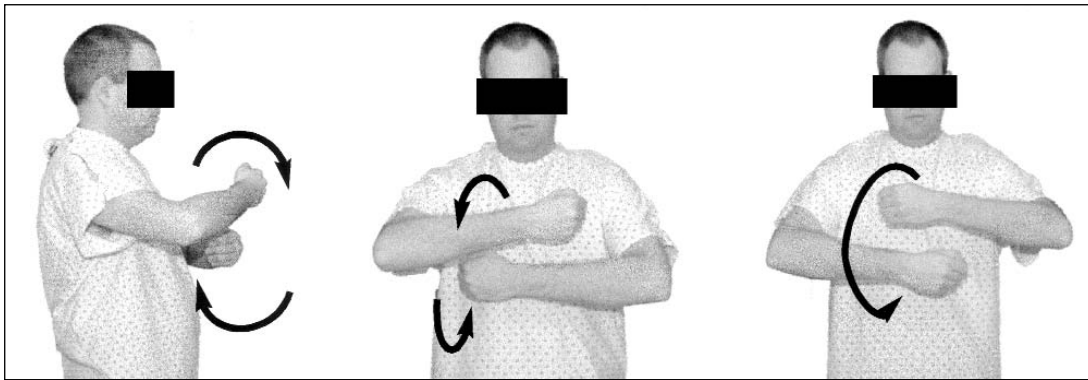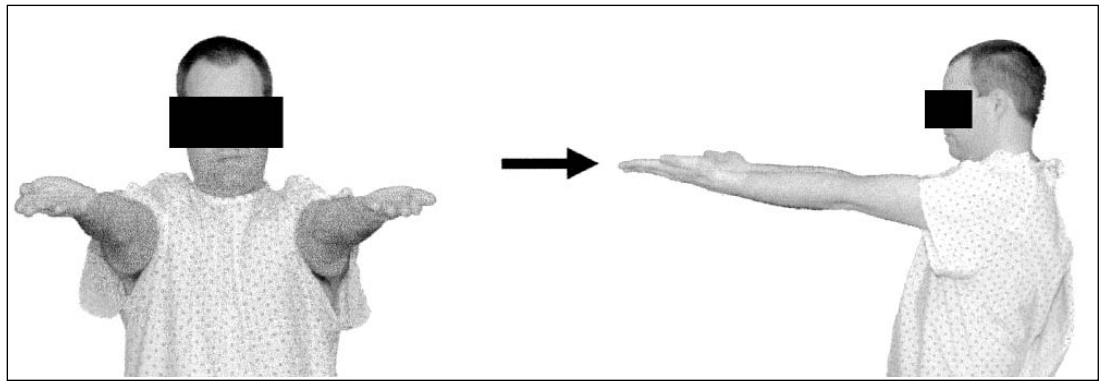
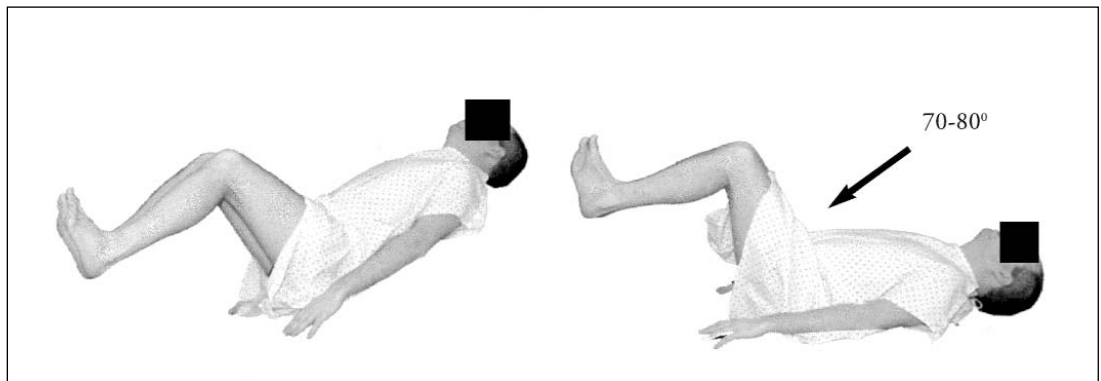


Figure 3: Forearm roll. The patient is asked to rapidly roll each forearm around the other for 5 to 10 seconds in each direction.

Figure 4: Mingazzini's manoeuvre. The patient is lying on his back. The hips are flexed at a 75 to 80 degree angle, and the knees are held at a 100-degree angle that allows the leg to be horizontal to the bed. Ankles are dorsiflexed at 90 degrees. The position is held for as long as possible to a maximum of 30 seconds.



more reflexes on the same side and / or a positive Babinski response compatible with an upper motor lesion.

Statistical analysis

I – Internal validity and test to test comparisons

The segmental exam was considered to be the standard to which other clinical tests were compared. Most neurologists as well as many textbooks considered it the most frequent method used to find and grade weakness.^{2,3}

The Barré (straight arm raising), pronator drift and Mingazzini manoeuvres were assessed at 30, 45 and 60 seconds. We calculated the sensitivity, the specificity, the PPV and NPV and the likelihood ratio (LR) of all the tests described.⁵

Combinations of several manoeuvres were evaluated as well, the aim being to find the best test or combination of tests for diagnosis of a central motor lesion.

Sensitivity was defined as the proportion of patients with a lesion in the motor pathways on CT in whom the test under evaluation is positive. The formula used is as follows:

$$\text{sensitivity} = \frac{\text{true positives (positive test and an abnormal CT)}}{\text{all patients with abnormal CT (true positives + false negatives)}} = \frac{a}{a+c}$$

a = true positives: abnormal CT and positive test

c = false negative: abnormal CT and negative test

Specificity was defined as the proportion of patients without a lesion on CT in whom the test is negative. The formula used is as follows:

$$\text{specificity} = \frac{\text{true negatives (normal CT and a negative test)}}{\text{all patients with a normal CT (true negatives + false positives)}} = \frac{b}{b+d}$$

b = false positive: normal CT and positive test

d = true negative: normal CT and negative test

Negative and positive predictive values: this value is defined as the ability of a negative test to predict the absence of disease. For complete accuracy, one must know the prevalence of the disease or abnormality in the population under assessment. This was not possible, and so these values contain inaccuracies and are being replaced by LRs.

$$\text{Negative predictive value} = \frac{a}{a+b}$$

$$\text{Positive predictive value} = \frac{d}{c+d}$$

Likelihood ratio: LRs indicate by how much a given diagnostic test result will raise or lower the probability of the target disorder. Likelihood ratios of >10 or <0.1 generate large and often conclusive changes from pre- to post-test probability. Likelihood ratios of 5 – 10 or 0.1 – 0.2 generate moderate changes from pre- to post-test probability. Likelihood ratios of 2 – 5 or 0.5 – 0.2 generate small but sometimes important changes in probability. Likelihood ratios of 1 – 2 or 0.5 – 1 generate moderate small and rarely important changes in probability.

$$\text{Likelihood Ratio for a positive test} = \text{LR+} = \frac{\text{sensitivity}}{1 - \text{specificity}} = \frac{a/(a+c)}{b/(b+d)}$$

$$\text{Likelihood Ratio for a negative test} = \text{LR-} = \frac{1 - \text{sensitivity}}{\text{specificity}} = \frac{c/(a+c)}{d/(b+d)}$$

Sequential or multilevel LRs: The presence or absence of each

test changes the probability of having the disease and so the LRs change pre and post each additional test. We have therefore calculated the multilevel ratios of all six tests and established the clinical significance according to the cumulative LRs.⁵

II- External validity

To evaluate reproducibility, two independent physicians (one of the authors and an independent neurology resident trained in the techniques) examined 85 of the 170 patients. The clinical manoeuvres were carried out in a nonspecified and hopefully random order so that fatigue would not influence results. Testing was done exactly as described so that interexaminer variation was kept to a minimum. External validity was calculated using a nonweighted kappa coefficient.⁵ When the two examinations differed, the author's examination was used for statistical analysis.

RESULTS

Patient demographics

Patient demographics are presented in Table 1. There were no statistically significant differences in the age and sex of the two groups although the control group tended to be younger with a more balanced male to female ratio. As expected, there was a preponderance of tumours, strokes and haemorrhages in the group with an abnormal CT. Those with normal CT had mostly migraine, transient ischemic attack (TIA) and non-neurological disease as their final diagnosis. The timing of the imaging studies varied with the diagnosis. For mass lesions, TIAs and cerebrovascular accidents (CVAs), the CT was performed within 48 hours of the event. The TIAs were all asymptomatic at the time of the CT. In all other cases, the CT was performed three to 10 days after the assessment and most of these CTs were normal. The CT was considered the gold standard at this time although several patients had MRI as well.

External validity

External validity was calculated in 85 cases using kappa coefficients (Table 2). There was good reproducibility for Barré (79.6%), pronator (81.6%) and FFM (80.6%). Reproducibility was somewhat less reliable in the forearm roll (77.6%).

Sensitivity, specificity and predictive values of each manoeuvre

Results for sensitivity, specificity, and PPVs and NPVs of all clinical manoeuvres are presented in Table 2. The duration of Barré and pronator drift used in this assessment is 45 seconds, as this was the time at which the best combination of sensitivity and specificity was obtained. Segmental motor strength had good specificity (97.5%) but very poor sensitivity (38.9%) and NPV (58.7%). The forearm roll had a similar profile to the segmental motor exam with a sensitivity of 45.6% and a specificity of 97.5%. Finger tap had a better sensitivity (73.3%) and an adequate specificity (87.5%). Barré testing had a high degree of sensitivity (86.7%) and specificity (90.0%). The pronator test was even more sensitive (92.2%) and just as specific (90.0%). Hyperreflexia had a sensitivity of 68.9% and a specificity of 87.5%.

The Mingazzini manoeuvre requires quite a bit of abdominal strength, and many patients were not able to perform it. The

Table 2: Sensitivity, Specificity, Predictive Values, and Likelihood Ratio of Each Test

	Sensitivity (%)	Specificity (%)	Positive Predictive Value (%)	Negative Predictive Value (%)	LR+	LR-
Forearm roll	45.6	97.5	95.4	61.4	18.2	0.56
Segmental motor exam	38.9	97.5	94.6	58.7	15.6	0.63
Pronator drift	92.2	90.0	91.2	91.1	9.2	0.09
Barré test	86.7	90.0	90.7	85.7	8.7	0.15
Mingazzini's manoeuvre	55.3	91.0	87.0	65.1	6.1	0.49
Fine finger movements	73.3	87.5	86.4	74.5	5.9	0.31
Deep tendon reflexes	68.9	87.5	86.1	71.4	5.5	0.36

Note 1. Sensitivity refers to the detection of an abnormal CT scan

Note 2. LR+ = Sensitivity / (1 – Specificity); values > 10 are desirable

Note 3. LR- = (1 – Sensitivity) / Specificity; values < 0.1 are desirable

LR: Likelihood ratio

calculations were therefore made on a smaller population. A total of 164 patients were able to perform the manoeuvre. Patients held the manoeuvre for an average of 10 seconds. Using this group of patients, sensitivity was 55.37% and specificity was 87.5%.

Barré and pronator tests had the best combination of NPV and PPV, and the pronator test seemed to be the best overall.

Combination testing

We looked for a combination of tests that would help maximize sensitivity without compromising specificity. We looked at six out of the seven tests performed. Mingazzini is not included in the LR table because all patients could not perform it. We include it in the combination testing, as upper motor neuron lesions will usually affect more than just one limb.

Table 3 shows the multilevel LR using six tests.⁵ This represents the likelihood of a patient having or not having a positive CT scan according to the number of positive tests. If all six tests are positive, the PPV is 100%, and if all six tests are negative the NPV is 100%. Therefore, you can be 100% sure of ruling-in a CT lesion in 16.7% of the patients with a positive CT and you can be 100% sure of ruling-out a CT lesion in 73.8% of the patients with a negative CT. Using information from Table 2, even with three of six tests positive, the PPV is 93%. However, the more tests that are positive, the greater the certainty. We have specifically chosen a group of patients where the weakness was subtle. Therefore, most of these patients have normal segmental motor strength. We see that even if segmental strength is normal (negative test), the presence of three or more tests will almost be certain to rule-in a lesion. To completely eliminate any possibility of a lesion one needs to have six negative exams. However, the more tests are negative, the more likely it is that a lesion is ruled out. It is important to note that there are no patients presenting with an abnormal segmental exam and a normal pronator test.

Most neurologists will want a quick, easily reproducible combination of tests that assesses strength, execution of

movement and reflexes, and to this they will likely add tone. In the emergency room, the emergency physician and the non-neurologist are likely to combine a nonstandard abbreviated type of segmental motor exam with testing of the reflexes.

Table 3: Usefulness of Six Tests

Number of positive tests	CT Lesion Present N = 90	CT Lesion Absent N = 80	Multilevel LR	Diagnostic Impact
6	15 (16.7%)	0 (0.0%)	+ ∞	Rule-in
5	22 (24.4%)	1 (1.3%)	18.8	High
4	20 (22.2%)	2 (2.5%)	8.9	Moderate
3	22 (24.4%)	3 (3.7%)	6.6	Moderate
2	8 (8.9%)	3 (3.7%)	2.4	Indeterminate
1	3 (3.3%)	12 (15.0%)	0.2	Low
0	0 (0.0%)	59 (73.8%)	0.0	Rule-out

Multilevel likelihood ratio (LR) = likelihood of a patient with a CT lesion having a specific number of positive tests compared with the likelihood that the same number of positive tests would be expected.

Rule-in: 100% likelihood that there is an underlying lesion.

High: the likelihood of having a lesion is very high but not absolute as there was one of the 23 patients in this group that had a normal CT.

Moderate: the likelihood of having a lesion is significant but not absolute, as almost 10% of this group will have a negative scan.

Indeterminate: this result is unhelpful in deciding whether there is a lesion or not.

Low: The likelihood of finding a lesion is low. In this group only 3 of 15 patients had a lesion.

Rule-out: When all tests are negative, there is no patient in whom a lesion will be found. Considered a definite negative.

Table 4: Combination of three manoeuvres

Pronator drift + Finger tap+ Deep tendon reflexes				
Test result	Sens. %	Spec. %	+ Pred. Val.	- Pred. val.
I += all 3 pos - = > 1 neg	75.52	97.5	94.2	79.59
II += > 1 pos - = all 3 neg	97.78	86.25	85.56	95.52

Looking for a small combination of tests that are quick and easy to perform, the best results were obtained using a combination of pronator drift lasting 45 seconds with FFM and deep tendon reflexes. If a Mingazzini test could be performed, the results were even better, but this test could not always be performed due to physical limitations. A positive result can be defined in different ways, with different results:

- The combination is considered positive if all manoeuvres are abnormal and negative if one or more manoeuvres are normal (combination I, Table 4)
- The combination is considered positive if one or more of the manoeuvres are abnormal and negative if none of the manoeuvres is abnormal (combination II, Table 4).

When all tests are positive (combination I), specificity is very high (97.5%) for a motor lesion and the PPV is 94.2%. If positivity implies that one or more tests are abnormal (combination II), a positive combination test has excellent sensitivity (97.8%) and NPV (95.5%).

DISCUSSION

The neurologist relies on the history and the neurological examination to decide when radiological investigation is necessary. Clinical signs should therefore have the best combination of sensitivity and specificity possible. Standard textbooks describe the techniques of examination used to detect upper motor neuron dysfunction without information on sensitivity or specificity.^{2,3} The only such information found in the literature pertains to the forearm roll¹ and the carpal tunnel syndrome.⁶

The detailed segmental motor strength examination is widely used to determine presence or absence of lateralization on motor exam.^{2,3} Even when properly performed, this study clearly demonstrates the very poor sensitivity and negative predictive value of the segmental motor examination in detecting subtle central motor lesions. Many patients with cerebral lesions involving the motor system will be missed if the segmental motor exam alone is used to rule out a subtle central motor abnormality.

Table 3 clearly shows that the six manoeuvres, used together, are a very powerful clinical tool. Fully negative or fully positive panels are 100% accurate. This would be quite time consuming, however, and not all patients would be able to co-operate. The three test combination testing, with a Mingazzini test when possible, has two major advantages. It is a very reliable way of clinically ruling out motor lesions, and it saves time.

Combination II (positive = one test is positive, negative = all tests are negative) has a sensitivity of 97.8% and a negative predictive value of 95.5% for a central motor lesion. When all the tests in this combination are negative, the possibility of a focal motor lesion is unlikely and further investigation is not warranted if the initial probability (based on history) is low. Of course, a NPV of less than 100% means there is still a chance that a lesion will be missed, and the decision to investigate further will be modulated by the degree of suspicion elicited by the history. If the history is worrisome, it is then best to proceed with a complete six element testing to be absolutely sure. Even then, if suspicion is high, a CT and MRI could be warranted.

When all three tests are positive, the specificity is 97.5% and therefore we believe that further investigation is warranted, whatever the suspicion level on history.

Of course, these statistics are calculated using CT as the gold standard. Although this is not the best way to rule out lesions, it was the test that the treating neurologists were using to help them make their diagnosis, and in most of the cases the investigation stopped there. It is possible that some patients with a normal CT actually had a lesion that was visible on MRI. Again, this illustrates the importance of the clinical impression on our subsequent evaluation.

The Mingazzini sign for leg weakness is hampered by the fact that many patients, particularly the elderly, cannot hold the position for a sufficient time owing to weak abdominal musculature. In our study, sensitivity was 55.3% and specificity 91.0%. Adding this test to the others did enhance the power of the three-test combination when it could be done.

It must be emphasized that both the Barré and pronator drift must be performed in a very rigorous fashion. Furthermore, the position should be held for 45 seconds in order to achieve maximum sensitivity. The duration of the test has an important effect on sensitivity. Although one might argue that emergency physicians and trainees could not attain such a level of proficiency, we demonstrate that both residents and non-neurologists achieved good inter-examiner reliability. A really good resistive segmental motor exam is more difficult to do than a standard Barré test and there were no cases of normal Barré or pronator drift when the resistive segmental motor exam was abnormal. Clearly, the sensitivity and specificity of these tests apply only to the detection of central motor lesions, and not to peripheral lesions such as radiculopathy or neuropathy, where a detailed peripheral neurological examination with oriented segmental examination is indicated.

The apparent difference in sensitivity of the Barré and the pronator drift may in part be due to accumulated muscle fatigue. Although the manoeuvres were to be performed in a random fashion, the pronator drift was tested right after the Barré manoeuvre in the majority of the patients. Because of the non-random order in which these two tests were done, the increased fatigue of the upper extremity at the time the pronator drift was tested may have contributed to the apparent increase in sensitivity of this test.

Our results are quite different from those obtained by Sawyer and colleagues¹ in their study of the forearm roll. In their study, forearm roll has a sensitivity of 87.1% and a specificity of 100%, upper limb drift had a sensitivity of 79% and a specificity of 100% as did finger tap. There are several differences in

methodology that could account for this. The patient base in the study by Sawyer was not limited to those with subtle motor deficits and included patients with variable hemiparesis. Patients with sensory abnormalities that could affect testing were not excluded, and, aside from the forearm roll there was no uniformity in the administration and interpretation of the clinical manoeuvres.

Although the detailed segmental motor examination has a very good specificity for detecting motor deficits, the sensitivity and negative predictive value are unacceptably low. On the other hand, the "straight arm raising" test (Barré) and the pronator drift, if performed as described, and for the required amount of time, are extremely sensitive as well as quite specific clinical manoeuvres to detect central motor weakness. With such a good specificity and PPV, the discovery of a positive pronator drift or Barré test mandates further investigation.

In the combination testing, the multi-level LR can help guide the physician by supplying objective predictive values for finding a lesion. If all six tests are positive, further evaluation and follow-up is mandatory even if initial CT is negative. If all six manoeuvres are negative, presence of a motor lesion is virtually ruled out but the decision to pursue the investigation will be modulated by the degree of clinical suspicion elicited by the history. If the clinical suspicion on history is low or moderate, the presence of six negative manoeuvres on clinical exam precludes the need to obtain CT. When clinical suspicion is high, the LRs provides the odds of finding a lesion but will not deter the physician from obtaining further imaging.

Pronator drift (or Barré test), with evaluation of finger tap,

deep tendon reflexes and Mingazzini (if possible) is the most reliable and time-effective combination of tests for the detection of subtle motor lesions. This package of motor tests has maximum sensitivity and efficiency for detecting subtle lesions and could be a very useful tool to the emergency physician when evaluating patients with possible neurological disease. We suggest that these manoeuvres be performed on a routine basis in all patients with possible central motor dysfunction.

ACKNOWLEDGEMENTS

We thank Dr John Stewart for his insightful comments and help in preparing the manuscript.

REFERENCES

1. Sawyer RN, Hanna JP, Ruff RL, Leigh RJ. Asymmetry of forearm rolling as a sign of unilateral cerebral dysfunction. *Neurology* 1993; 43:1596-1598.
2. Haerer AF. Segmental motor strength and pronator drift. In: DeJong RN, (Ed.) *The Neurologic Examination*. (5th ed). New York: JB Lippincott 1999: 333-374 and 378.
3. Bickley LS, Hoekelman RA. Segmental strength and pronator drift. In: *Bates Guide to Physical Examination and History Taking*. (7th ed). Philadelphia: Bickley LS ed. Lippincott, William and Wilkins. 1999: 577-585.
4. Koehler PJ, et al. (Eds) *Neurological Eponyms*. New York: Oxford University Press, 2000. Chapter 19.
5. Guyatt G, Rennie D (Eds.) *Users' Guide to the Medical Literature. A Manual for Evidence-based Clinical Practice*. JAMA & Archives Journals. Chigago, Illinois: AMA press. 2002.
6. Stewart JD, (Ed.) *Focal Peripheral Neuropathies*. (3rd ed). New York: Elsevier. 1987: 151-152.