

control subjects (HCs). To be enrolled in this study, patients had to show at BL reduced $\Delta\Delta$ TSH values (i.e., < 2.5 mU/L) and a score of 18 or greater on the 17-item Hamilton Rating Scale for Depression (HAMD-17). Post-DST cortisol maximum (COR_{max}) serum level in excess of 120 nmol/L defined DST non-suppression (i.e., hypercortisolemia)—6 TRDs were DST non-suppressors at BL. After 10 and 20 iTBS sessions the $\Delta\Delta$ TSH test and the DST were repeated in all inpatients. A positive clinical response was defined by a final HAMD-17 score ≤ 8 .

Results: Compared to HCs, $\Delta\Delta$ TSH values were lower in TRDs at BL ($p < 0.00001$), and remained reduced after 10 and 20 iTBS sessions ($p < 0.001$ and $p < 0.02$ respectively). Post-DST COR_{max} levels were higher in TRDs than in HCs at BL ($p < 0.01$), but were comparable to those of HCs after 10 and 20 iTBS sessions. Responders ($n = 5$) were characterized by 1) a normalization of their $\Delta\Delta$ TSH values after 20 iTBS sessions (whereas after 10 iTBS sessions $\Delta\Delta$ TSH values were still reduced compared to HCs [$p < 0.05$]), and 2) a normality of post-DST COR_{max} levels at BL—while after 10 and 20 iTBS sessions post-DST COR_{max} levels were decreased compared to HCs ($p < 0.006$ and $p < 0.03$ respectively). Non-responders ($n = 7$) showed 1) no significant change in their $\Delta\Delta$ TSH values which remained lower than those of HCs at each assessment (all $p < 0.001$), 2) while increased post-DST COR_{max} levels found at BL ($p < 0.0008$ vs. HCs) normalized from the 10th iTBS session.

Conclusions: The present pilot study suggests that successful iTBS treatment can restore the chronobiological activity of the HPT axis. Although iTBS may increase glucocorticoid receptor signaling, baseline hypercortisolemia could negatively impact subsequent response to iTBS treatment.

Disclosure of Interest: None Declared

EPP0058

Brain atrophy but not white matter lesions associate with ECT-related confusion

A. A. Politis¹, N. Kokras^{1*}, G. Velonakis² and A. M. Politis¹

¹First Department of Psychiatry and ²Research Unit of Radiology and Medical Imaging - Second Department of Radiology, National and Kapodistrian University of Athens, Medical School, Athens, Greece

*Corresponding author.

doi: 10.1192/j.eurpsy.2024.290

Introduction: Patients undergoing electroconvulsive treatment (ECT) may display an acute confusional state, often characterized by transient disorientation, inattention, memory and cognitive deficits.

Objectives: In this retrospective medical chart naturalistic study, we sought to determine whether white matter lesions and brain atrophy associate with the emergence of confusion during ECT treatment and preliminary results are presented herein

Methods: Medical charts of 24 consecutive inpatients with depression admitted to a psychogeriatric ward and subjected to bilateral frontotemporal ECT were examined retrospectively for patient and clinical characteristics. Mini-Mental State Examination (MMSE) and Geriatric Depression Scale (GDS) scores at admission and hospital discharge were retrospectively collected. Available brain

Magnetic Resonance Imaging (MRI) scans were graded for lesions (white matter hyperintensities, WMH), parietal, temporal and global brain atrophy

Results: In this pilot study of mostly elderly patients, 50% displayed signs of confusion. All patients improved substantially, as indicated by MMSE and GDS scores, irrespectively of whether they experienced transient confusion during ECT. Preliminary results indicate that WMH are unrelated to the emergence of confusion. Instead, brain atrophy, and in particular temporal lobe and mostly frontal lobe atrophy associated with confusion

Conclusions: In our sample of elderly inpatients with depression subjected to bilateral ECT, preliminary results of this pilot study indicate that brain atrophy, as evidenced by MRI scans, appears as a predictor of post-ECT confusion. Moreover, the Pasquier scale, and specifically the scale sub-scores regarding brain atrophy in the frontal and temporal sulci, could prove useful in helping the clinician estimate the probability of ECT-related confusion during ECT treatment

Disclosure of Interest: None Declared

EPP0059

Changing Tactics? Optimizing ECT in difficult-to-treat depression (ChaT): study protocol

L. Van den Eynde^{1*}, K. Vansteelandt¹, K. Hebbrecht¹, J. Obbels¹, S. Verspecht¹, L. Gistelinck², P.-J. Geerts³, D. Schrijvers⁴ and P. Sienaert¹

¹Academic Center for ECT and Neuromodulation (AcCENT), UPC KU Leuven, Kortenberg; ²Psychiatry, AZ Sint Jan Bruges, Bruges; ³Psychiatry, AZ Groeninge, Kortrijk and ⁴Collaborative Antwerp Psychiatric Research Institute (CAPRI), UAntwerpen, Antwerp, Belgium

*Corresponding author.

doi: 10.1192/j.eurpsy.2024.291

Introduction: Electroconvulsive therapy (ECT) is an evidence-based treatment for difficult-to-treat depression, in which an electrical stimulus is applied via right unilateral (RUL) (Fig 1) or bitemporal (BT) electrodes (Fig 2). Current guidelines recommend to start ECT with RUL placement, except for cases where rapid response is needed. BT ECT has the reputation of exerting a stronger and faster antidepressive effect, but is associated with more pronounced cognitive side effects, as compared to RUL ECT. Recent studies, however, suggest comparable outcomes. In patients responding to ECT, most of the improvement in depressive symptom severity is witnessed early in the treatment course. In case of non-response, it is common practice to switch from RUL to BT electrode placement, although scientific evidence is lacking. As an answer to this research gap, the ChaT-trial was designed: a randomized controlled trial (RCT) to address which treatment strategy (either continue RUL ECT or switch to BT ECT) speeds up recovery with the least impact on cognitive function, in case of early non-response after 4 ECT sessions.

Objectives:

- 1) To compare the antidepressant efficacy and cognitive effects of continuing RUL ECT vs switching to BT ECT.

- 2) To assess group and subject-specific trajectories of depressive symptom severity and neurocognitive performance during the acute ECT course and up to 3 months post-treatment.

Methods: This multi-center double-blind RCT includes adult patients with a uni- or bipolar depression. In case of non-response (<50% decrease of IDS-CR score (Inventory of Depressive Symptomatology-Clinician Rated)) after 4 sessions of brief-pulse high-dose RUL ECT, patients are randomized to either continue RUL ECT, or switch to brief-pulse moderate dose BT ECT until remission. Depressive symptoms are assessed by IDS-CR, Psychotic Depression Assessment Scale (PDAS) and CORE assessment of psychomotor change. An extensive neuropsychological test battery is used to assess different domains of cognitive functioning, e.g., autobiographical memory using the Columbia University- Autobiographical Memory Interview Short- Form (CU-AMI-SF)(Fig 3).

Results: Our hypotheses are: (1) continuing RUL ECT is non-inferior to switching to BT ECT in terms of depressive symptom severity, and (2) continuing RUL ECT is superior to switching to BT ECT in terms of cognitive side effects.

Image:

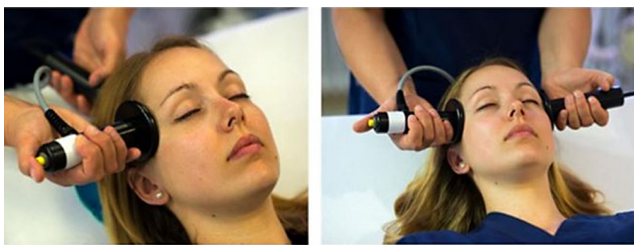

Figure 1: Right unilateral electrode placement (RUL)

Figure 2: Bitemporal electrode placement (BT)

Image 2:

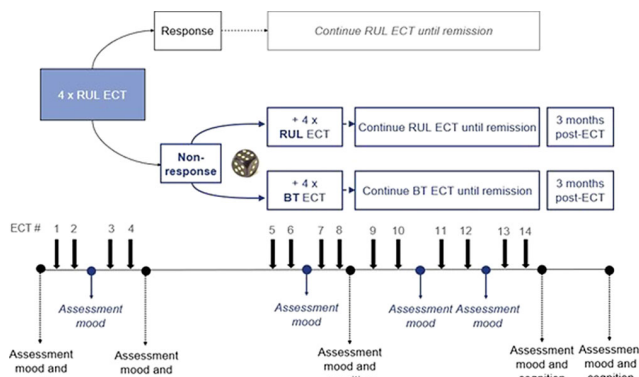


Figure 3: Study design

Conclusions: The ChaT-trial is the first RCT comparing antidepressant efficacy and cognitive effects of continuing RUL ECT with switching to BT ECT in case of early non-response during an acute ECT-course. The results may optimize clinical decision making, speeding up recovery, while minimizing cognitive side effects.

Disclosure of Interest: None Declared

EPP0060

Postictal recovery of orientation in person, place and time relates to restoration of cortical activity after electroconvulsive therapy

S. Stuiver^{1,2*}, J. Pottkämper^{2,3}, J. Verdijk^{1,2}, F. ten Doesschate¹, M. van Putten^{2,4}, J. Hofmeijer^{2,3} and J. van Waarde¹

¹Psychiatry, Rijnstate Hospital, Arnhem; ²University of Twente, Enschede; ³Neurology, Rijnstate Hospital, Arnhem and ⁴Clinical Neurophysiology, Medisch Spectrum Twente, Enschede, Netherlands

*Corresponding author.

doi: 10.1192/j.eurpsy.2024.292

Introduction: Most patients show temporary impairments in clinical orientation (i.e., orientation in person, place, and time) after electroconvulsive therapy (ECT)-induced seizures. It is unclear whether postictal reorientation is related to electroencephalography (EEG) restoration. This tentative relationship may shed light on mechanistic aspects of reorientation after ECT.

Objectives: To study whether postictal EEG restoration after an ECT-induced seizure is related to recovery of clinical orientation in the cognitive domains person, place and time.

Methods: We performed a longitudinal study in ECT patients and collected continuous postictal EEGs. Postictal EEG restoration was estimated by the evolution of the normalized alpha/delta ratio (ADR). Recovery of orientation in the cognitive domains of person, place, and time was assessed using the Reorientation Time (ROT) questionnaire. In each cognitive domain, a linear mixed model was fitted to investigate the relationship between ROT and postictal EEG restoration. In these models, other (ECT-)parameters including seizure duration, use of benzodiazepines and electrode placement were included.

Results: In total, 272 ictal and postictal EEG recordings of 32 patients were included. In all domains, longer ROT was associated with slower postictal EEG recovery. Longer seizure duration and use of benzodiazepines were related to longer ROT in all domains. Increased total charge of the ECT-stimulus was associated with increased ROT in place and age was positively associated with ROT in time.

Image:

