




A rare complication after radiofrequency catheter ablation in an adolescent case: skin burn

Emine Gulsah Torun , Nevin Özdemiroğlu and Serhat Koca

Department of Pediatric Cardiology, Ankara City Hospital, Ankara, Turkey

Brief Report

Cite this article: Torun EG, Özdemiroğlu N, and Koca S (2023) A rare complication after radiofrequency catheter ablation in an adolescent case: skin burn. *Cardiology in the Young* **33**: 2402–2404. doi: [10.1017/S1047951123001300](https://doi.org/10.1017/S1047951123001300)

Received: 20 April 2022
Revised: 1 January 2023
Accepted: 15 May 2023
First published online: 31 May 2023

Keywords:

Skin Burn; complication; radiofrequency catheter ablation

Corresponding author: E. G. Torun;
Email: drgtorun@gmail.com

Abstract

Radiofrequency catheter ablation is a preferred treatment method for cardiac arrhythmias in children due to its high success rate and low complication risk. We present an adolescent patient who underwent radiofrequency catheter ablation for Wolff–Parkinson–White syndrome and developed a skin burn at the site of the electrode patch. Skin burns can catastrophic consequences, especially in patients with life-threatening arrhythmias; therefore, clinicians should be aware of this complication.

Radiofrequency catheter ablation is a preferred treatment method for cardiac arrhythmias in children due to its high success rate and low complication risk.^{1,2} Cardiac tamponade, pericarditis, pneumothorax, phrenic nerve palsy, thromboembolism, and atrioventricular block are among the major complications reported in patients undergoing radiofrequency catheter ablation.^{3,4} Although there are studies on skin burns developing after radiofrequency ablation, which is used in the treatment of hepatic tumours, there are not sufficient data in the literature on skin burns that occur during cardiac arrhythmia treatment.⁵

In this paper, we present an adolescent patient who underwent radiofrequency catheter ablation for Wolff–Parkinson–White syndrome and developed a skin burn at the site of the electrode patch.

Case report

A 14-year-old girl with Wolff–Parkinson–White syndrome was referred to our clinic for radiofrequency catheter ablation. The patient’s body mass index was 25.8. In the procedure performed under general anaesthesia, a high-risk left posterolateral manifest accessory pathway was detected in the patient. An electrode patch (9 x 10 mm) was placed on the anterior aspect of the trunk of the patient, and radiofrequency catheter ablation was successfully performed using a sheath placed on the right femoral artery, with a retrograde aortic approach, a 7-F multi-curve radiofrequency ablation catheter (MarinR, Medtronic, Minneapolis, USA), and a radiofrequency generator (Amper, St Jude Medical, St Paul, Minnesota, USA) (Fig. 1). Radiofrequency energy was applied three times for one minute each, at a maximum power of 50 W, and a temperature of 60°C. Impedance was kept constant during the application of energy (150–155 Ω). When the electrode patch was removed at the end of the procedure, A third-degree 5x6 cm skin burn was observed on the anterior surface of the patient’s body where the electrode patch had been placed (Fig. 2). The burn area healed with topical treatment.

Discussion

We presented a rare skin burn in an adolescent patient with high-risk Wolff–Parkinson–White syndrome after a successful radiofrequency catheter ablation procedure. This complication, which we encountered for the first time in the electrophysiology laboratory of our centre, has been rarely reported in paediatric patients in the literature and is important.⁶ Although patients with life-threatening arrhythmias are successfully treated with radiofrequency catheter ablation, complications such as skin burns can result in catastrophic consequences.

Electrode patches provide an equal amount of current and heat in the electrodes and patches during radiofrequency ablation therapy, providing the intensification of the current patches passing through the patient to complete the electromagnetic circuit, acting as grounding. A large surface area and good skin contact are required to dissipate high energy charges.⁷

In the study of Ibrahim et al,⁴ the incidence of skin burns after the radiofrequency catheter ablation procedure was found to be 0.28% over the age of 18 years. Ibrahim et al⁴ reported that the median body mass index of the patients with skin burns was also higher than the control group (36.6 versus 30.6, $p = 0.044$), their total procedure time was longer than the control group,

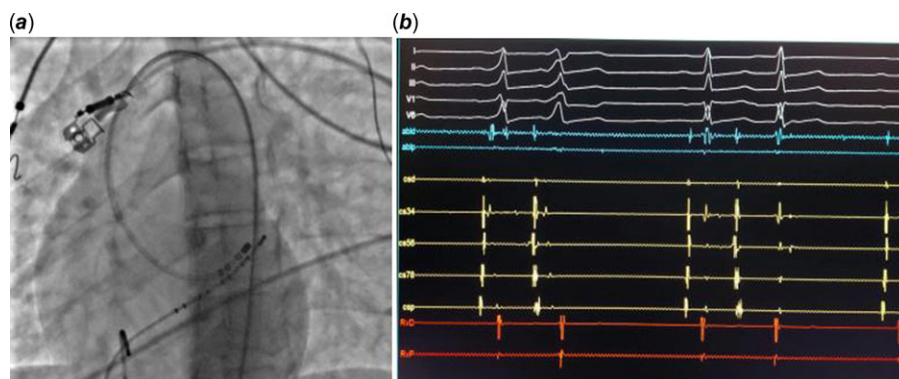


Figure 1. *a.* Radiofrequency catheter ablation with the retrograde aortic approach. *b.* Accessory pathway ablation.

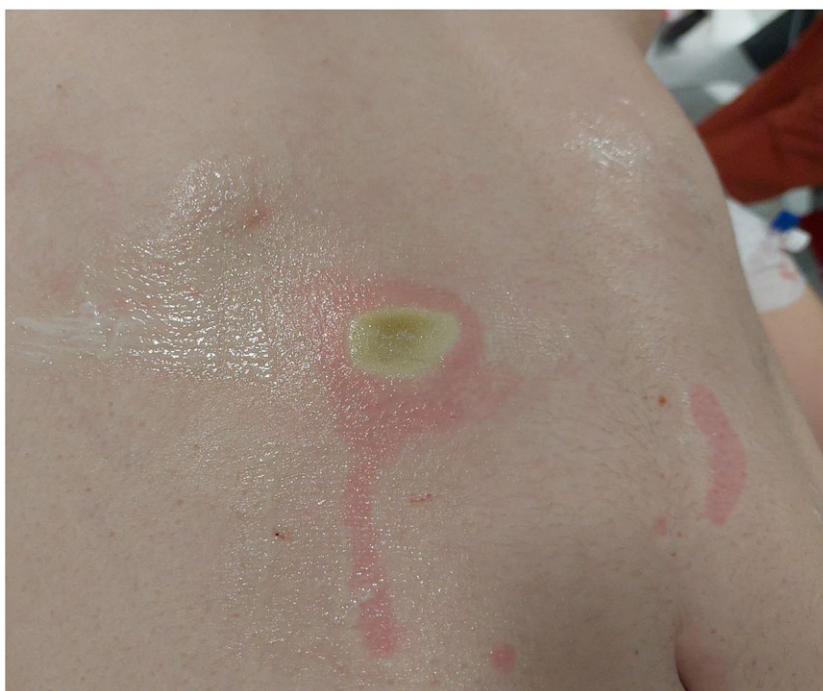

Figure 2. Third-degree skin burn at the electrode patch site.

and none of these patients had electrode patch malattachment. In the same study, the difference between the maximum current watt used and the maximum temperature reached did not statistically significantly different between the patients with skin burns and controls.⁴ In another paediatric case, the lack of contact between the pad and skin and the long duration of the procedure were considered as factors that could cause skin burns.⁶ In our case, the patient's body mass index was normal, and the total procedure time and the Watt and temperature used were not above the risk limits specified in the literature.^{4,7} We did not observe any malattachments to lack of contact after the procedure, but the skin burn being mainly in the upper right corner of the patch electrode and presence of no other risk factors during the procedure suggest that the partial loosening of the skin-to-skin contact may have caused the skin burn.

Strategies such as the use of more and/or wider patches in radiofrequency ablation therapy, good contact between the electrode patches and skin, short-term use of low-energy currents, and monitoring of the temperature in the electrode patch area have been suggested to prevent skin burns.⁵⁻⁸ In the study of Ibrahim et al,⁴ current Watt and maximum temperature used were not

found to be risk factors for skin burn development, while body mass index and procedure time were found to be risk factors.

The incidence of skin burns at the electrode patch site after radiofrequency catheter ablation is low.⁴ Since the use of high-energy applications and multiple ablation procedures in the treatment of cardiac arrhythmia are expected to increase in future, it can be predicted that the incidence of such complications will also increase. Although there are not methods to prevent the development of skin burns associated with the cardiac radiofrequency procedures, this complication can be prevented by establishing good skin contact with the electrode patches and avoiding high-energy currents. Skin burns can be prevented using a new patch in each ablation procedure, checking the patch frequently during the procedure, and ensuring that the patch and the skin are dry. Further research or case reports can provide incidence and a better understanding of the causes of such complications and develop various methods to prevent them.

Acknowledgements. None.

Financial supports. This research received no specific grant from any funding agency in commercial or not-for-profit sectors.

Competing interests. None.

References

1. Hindricks G. The multicentre european radiofrequency survey (MERFS): complications of radiofrequency catheter ablation of arrhythmias. the multicentre european radiofrequency survey (MERFS) investigators of the working group on arrhythmias of the European society of cardiology. *Eur Heart J* 1993; 14: 1644–1653.
2. Rostock T, Risius T, Ventura R, Klemm HU, Weiss C, et al. Efficacy and safety of radiofrequency catheter ablation of atrioventricular nodal reentrant tachycardia in the elderly. *J Cardiovasc Electrophysiol* 2005; 16: 608–610.
3. Kugler JD, Danford DA, Houston KA, Felix G. Pediatric radiofrequency ablation registry of the pediatric radiofrequency ablation registry of the pediatric electrophysiology society pediatric radiofrequency catheter ablation registry success, fluoroscopy time, and complication rate for supraventricular tachycardia: comparison of early and recent eras. *J Cardiovasc Electrophysiol* 2002; 13: 336–341.
4. Ibrahim H, Finta B, Jubran Rind J. Incidence and factors predicting skin burns at the site of the indifferent electrode during radiofrequency catheter ablation of cardiac arrhythmias. *Cardiol Res Pract* 2016; 2016: 5265682.
5. Mulier S, Mulier P, Ni Y, Miao Y, Dupas B, et al. Complications of radiofrequency coagulation of liver tumors. *Br J Surg* 2002; 89: 1206–1222.
6. Ertuğrul İ., Karagöz T, Aykan H. A rare complication of radiofrequency ablation: skin burn. *Cardiol Young* 2015; 25: 1385–1386.
7. Goldberg SN, Solbiati L, Halpern EF, Gazelle GS. Variables affecting proper system grounding for radiofrequency ablation in an animal model. *J Vasc Interv Radiol* 2000; 11: 1069–1075.
8. Steinke K, Gananadha S, King J, Zhao J, Morris DL. Dispersive Pad Site Burns With Modern Radiofrequency Ablation Equipment. *Surg Laparosc Endosc Percutan Techn* 2003; 13(6): 366–371.