

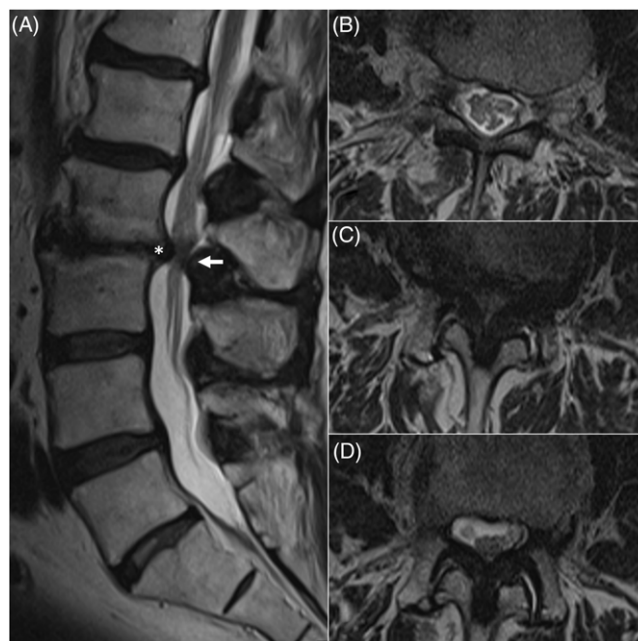
**LETTER TO THE EDITOR****TO THE EDITOR****Extensive Herpes Simplex Virus 2 Myeloradiculitis in an Immunocompetent Host**

**Keywords:** Infectious diseases, Neuroinfectious disease, Polyneuropathy, Spine

Herpes simplex virus 2 (HSV-2) infection can have a variety of neurological manifestations including myelitis and radiculitis with variable MRI findings.<sup>1</sup> HSV-2 radiculitis typically involves the lumbosacral region given the predilection of HSV-2 for the sacral sensory ganglia and has been eponymously referred to as Elsberg syndrome.<sup>2</sup> Here we describe a patient who developed extensive HSV-2 myeloradiculitis starting in the lumbosacral region progressing up to the thoracic and C8 spinal level with extensive meningeal enhancement on MRI.

An 84-year-old immunocompetent male with longstanding lumbar spinal stenosis developed 2 months of increasing bilateral leg pain and weakness. He underwent an uncomplicated L3–4 epidural steroid injection on September 28th which provided improvement in symptoms for approximately 2 weeks. Beginning October 13th, he then developed a sudden decline in his strength bilaterally resulting in a number of falls which prompted his admission to hospital on October 19th. He did not have any preceding viral illness or genital ulcers, although his partner did have a herpetic skin eruption earlier that year with no oral or genital involvement. He was born in Canada with unremarkable travel history.

On admission, he had Medical Research Council (MRC) grade 3/5 strength and minor sensory deficits in his legs. Initial MRI (Figure 1) suggested progressive spinal stenosis and no suspicion of a non-compressive etiology, so he underwent a L2–3 laminectomy. Over the next week, his deficits progressed to complete flaccid paralysis of both legs, sensory loss up to the T4 spinal level, global areflexia, and new hand weakness with MRC grade 1–2/5 strength in finger extension, abduction, flexion, and thumb abduction and MRC grade 4/5 in wrist extension bilaterally. Repeat MRI with gadolinium demonstrated thickening and clumping of the lumbosacral nerve roots and cauda equina with peripheral enhancement (Figure 2), involvement of the thoracic and C8 nerve roots (Figure 3), as well as patchy areas of T2 hyperintensity in the anterior thoracic spinal cord and conus medullaris. Lumbar puncture demonstrated markedly elevated protein (9.88 g/L; ref 0.15–0.45), low glucose (1.8 mmol/L; ref 2.3–4.1), and lymphocytic (83%) pleocytosis ( $84 \times 10^6$  cells/L; ref 0–5). Given this rapid deterioration, he was treated empirically for infectious and inflammatory causes of polyradiculitis with intravenous immunoglobulin, meningitis-dosed antibiotics, and IV valacyclovir. CSF cultures were negative, as were CT body, PET scan, and serum and urine protein electrophoresis with no evidence of malignancy or sarcoidosis. Electrodiagnostic studies confirmed widespread axonal polyradiculoneuropathy involving the lumbosacral and C8 roots without demyelinating features. Full skin examination revealed a single erosion on the buttock, although its age and whether it was previously vesicular was not known. Nucleic acid testing of the erosion and CSF

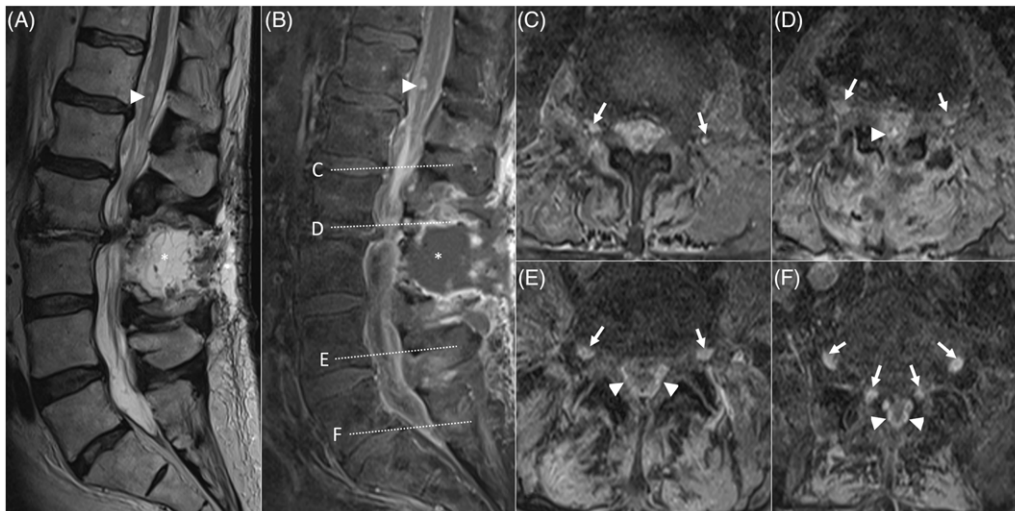


**Figure 1:** MRI lumbar spine. Sagittal T2-weighted sequence (A) demonstrating severe central canal stenosis from posterior disc bulge and thickening of ligamentum flavum at the L2–3 level (\*). Arrow corresponds to axial view (C) with additional axial views immediately above (B) and below (D).

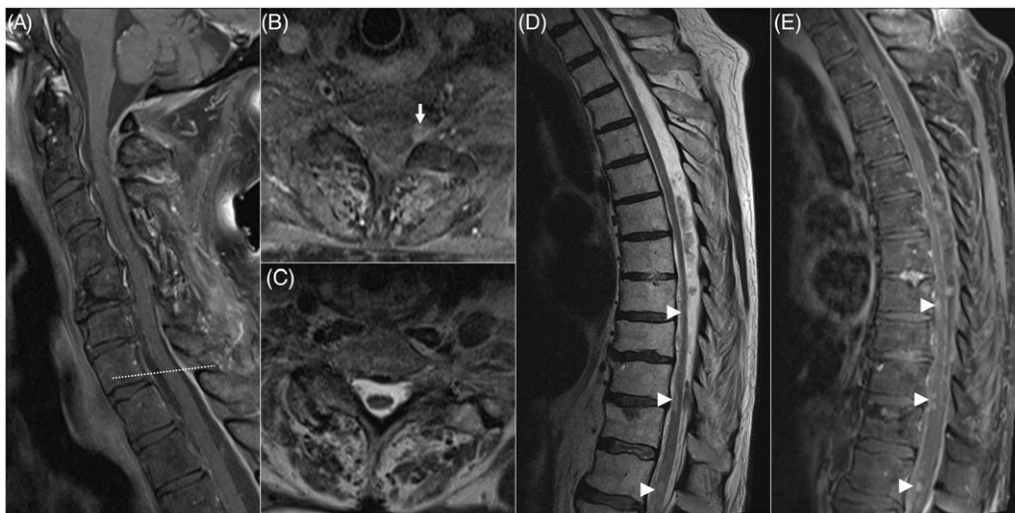
samples returned positive for HSV-2. After 12 days of intravenous therapy, he was transitioned to suppressive oral valacyclovir indefinitely under the direction of the infectious disease consultants, with improvement to T10 pinprick sensory level and distal hand strength MRC grade 4/5. He was transferred to a rehabilitation hospital with persistent paraplegia but recovered truncal and hand function.

HSV-2 infection ascending beyond the lumbosacral roots to involve cervical and thoracic roots is uncommon.<sup>1,3</sup> Previous reports of HSV-2 myelitis and radiculitis extending above the lumbar spinal levels have only been described in the context of ascending necrotizing myelitis in immunocompromised hosts that can be fatal within weeks.<sup>3,4</sup> Our patient had both distal hand weakness and evidence of C8 root involvement which improved with treatment, highlighting the potential for recovery with prompt therapy. Additionally, the magnitude of enhancement on MRI in our case is severe relative to previously published images of HSV-2 myelitis and polyradiculitis, including those in immunocompromised patients.<sup>5</sup> In fact, many cases of HSV-2 neurological infection report no MRI abnormalities.<sup>1</sup>

Symptomatic HSV-2 infection typically occurs in immunocompromised patients. Risk factors for ascending myelitis involving the cervicothoracic spine include diabetes, HIV infection, and active neoplasm,<sup>2,4</sup> all of which were not found in this case. While this patient was not clearly immunocompromised, potential stimuli for HSV-2 infection could include the steroid injection or laminectomy as there have been previous reports of HSV-2 reactivation following surgery of the cervical nerve roots.<sup>2,6</sup> The patient's initial gradual symptoms pre-dated both the



**Figure 2:** MRI lumbar spine. Sagittal T2-weighted (A) and T1-weighted fat saturated post-gadolinium (B) sequences demonstrate foci of hyperintensity and enhancement (arrowhead), respectively, with post-operative seroma (\*). Dotted lines in panel B correspond to axial views (C–F) demonstrating enhancement of multiple nerve roots (arrows), conus medullaris (D, arrowhead), and cauda equina (E–F, arrowheads).



**Figure 3:** MRI cervical and thoracic spine. Sagittal T1-weighted fat saturated post-gadolinium (A) sequence with dotted line corresponding to axial view (B) and axial T2-weighted (C) sequences of the cervical spine, demonstrating enhancement of left C8 nerve root (arrow). Sagittal T2-weighted (D) and T1-weighted fat saturated post-gadolinium (E) sequences of the thoracic spine demonstrate multiple foci of dural thickening with T2 high signal and enhancement (arrowheads), respectively.

injection and surgery so may more likely have been the result of his spinal stenosis with the more rapid subsequent deterioration due to HSV-2 reactivation causing swelling of nerve roots within the area of stenosis.

The diagnosis of HSV-2 myeloradiculitis is rare and can be further complicated by concurrent pathology and atypical features. Our patient had concurrent spinal stenosis, and HSV-2 polyradiculitis presents similarly to other causes of cauda equina syndrome.<sup>1</sup> Hypoglycorrhachia and high protein are not classically associated with viral infections but have been reported in HSV-2 myelitis<sup>7</sup> and polyradiculitis.<sup>2</sup> These CSF features are typically seen in fungal or tuberculous meningitis, neurosarcoi-dosis, primary leptomeningeal lymphoma, or leptomeningeal carcinomatosis. The markedly elevated CSF protein could be

further explained by additional spinal block, as seen in Froin's syndrome, and the recent laminectomy. Additionally, his symptoms, and presumably infection, may have misleadingly responded to the epidural steroid injection initially, as steroids and antivirals have been used as treatment for HSV-2 polyradiculitis and myelitis.<sup>1</sup> Suppressive antiviral therapy was used in this case to prevent recurrence of infection in first 6 months following initial diagnosis, in keeping with existing evidence highlighting its use in HSV-2 CNS infection.<sup>8</sup>

In conclusion, this case demonstrates that HSV-2 polyradiculitis and myelitis can present with extensive meningeal involvement throughout the spinal cord beyond the lumbosacral region and may even affect the upper limbs in an immunocompetent host. To our knowledge, extension of lumbosacral

polyradiculitis from HSV-2 involving cervical roots has not been previously reported in an immunocompetent host. This patient had a severe presentation but experienced stabilization and recovery of truncal and hand function with steroids and antiviral therapy, emphasizing the importance of early treatment. Thus, clinicians should have a low threshold to investigate for HSV-2 in patients presenting with polyradiculitis, even if immunocompetent and regardless of the degree of spinal involvement or MRI enhancement which can be extensive as in our case, or absent as in others.

#### ACKNOWLEDGEMENTS

The authors thank the patient and his partner for their consent to publication, as well as the medical and nursing staff of the Vancouver General Hospital Spine unit for their support in managing this case.

#### DISCLOSURES

The authors report no disclosures relevant to the manuscript.

#### STATEMENT OF AUTHORSHIP


CL: drafting the manuscript, revising the manuscript critically for important intellectual content, final approval. AAJ: revising the manuscript critically for important intellectual content, final approval. TC: study conception and design, acquisition and interpretation of data, revising the manuscript critically for important intellectual content, final approval.

*Cody Lo*

*Department of Ophthalmology, Faculty of Medicine, University of Ottawa, Ottawa, Ontario, Canada*

*Andrea A. Jones*

*Division of Neurology, Department of Medicine, University of British Columbia, Vancouver, British Columbia, Canada*

*Tychicus Chen* 

*Division of Neurology, Department of Medicine, University of British Columbia, Vancouver, British Columbia, Canada*

*Correspondence to:* Tychicus Chen, Division of Neurology, Department of Medicine, University of British Columbia, Room 8219, 8th Floor, Gordon and Leslie Diamond Health Care Centre, 2775 Laurel Street, Vancouver, British Columbia V5Z 1M9, Canada. Email: [tychicus@mail.ubc.ca](mailto:tychicus@mail.ubc.ca)

#### REFERENCES

1. Savoldi F, Kaufmann TJ, Flanagan EP, Toledano M, Weinschenker BG. Elsberg syndrome: a rarely recognized cause of cauda equina syndrome and lower thoracic myelitis. *Neurol Neuroimmunol Neuroinflamm.* 2017;4:e355.
2. Berger JR, Houff S. Neurological complications of herpes simplex virus type 2 infection. *Arch Neurol.* 2008;65:596–600.
3. Ellie E, Rozenberg F, Dousset V, Beylot-Barry M. Herpes simplex virus type 2 ascending myeloradiculitis: MRI findings and rapid diagnosis by the polymerase chain method. *J Neurol Neurosurg Psychiatry.* 1994;57:869–70.
4. Wiley CA, VanPatten PD, Carpenter PM, Powell HC, Thal LJ. Acute ascending necrotizing myelopathy caused by herpes simplex virus type 2. *Neurology.* 1987;37:1791.
5. Suarez-Calvet M, Rojas-Garcia R, Querol L, Sarmiento LM, Domingo P. Polyradiculoneuropathy associated to human Herpesvirus 2 in an HIV-1-infected patient (Elsberg syndrome): case report and literature review. *Sex Transm Dis.* 2010;37:123–5.
6. Grauvogel J, Vougioukas VI. Herpes radiculitis following surgery for symptomatic cervical foraminal stenosis. *Can J Neurol Sci.* 2008;35:661–3.
7. Tomkinson C, Fong C, Perera K. Myelitis with hypoglycorrhachia due to Herpes simplex virus 2 in an immunocompetent man. *Can J Neurol Sci.* 2019;46:147–8.
8. Aurelius E, Franzen-Röhl E, Glimåker M, et al. Long-term Valacyclovir suppressive treatment after Herpes simplex virus type 2 meningitis: a double-blind, randomized controlled trial. *Clin Infect Dis.* 2012;54:1304–13.