

Brugada syndrome in a young patient with palpitations

Deanne G. Watrich, MD, CCFP,* Robert A. Woods, MD;† Ivan P. Steiner, MD, MCFP(EM)‡

ABSTRACT

Brugada syndrome is a potentially lethal and eminently treatable entity that may present with palpitations or syncope. This article presents the case of a young patient with Brugada syndrome and reviews key features in the epidemiology, pathophysiology, diagnosis, treatment and prognosis of this condition.

Key words: Brugada syndrome; emergency medicine; ventricular fibrillation; sudden death

RÉSUMÉ

Le syndrome de Brugada est une entité qui peut être fatale, est très traitable et peut se manifester sous forme de palpitations ou de syncope. Dans cet article, on présente le cas d'un jeune patient atteint du syndrome de Brugada et passe en revue les caractéristiques clés de l'épidémiologie, de la pathophysiologie, du diagnostic, du traitement et du pronostic de ce problème.

Introduction

Patients frequently present to the emergency department (ED) with palpitations or syncope. Most have benign conditions and a favourable prognosis; however, those with a cardiac cause of syncope have one year mortality rates between 18% and 33%, substantially higher than the 0%–12% for non-cardiogenic syncope and 6% for unexplained syncope.¹ Cardiac syncope can be classified as being either structural or dysrhythmogenic in origin and it may be the only warning of potential sudden cardiac death (SCD).¹ The relationship between “palpitations” and SCD is tenuous. Most people with cardiac dysrhythmias do not experience palpitations,^{2,3} and only 34.7% of patients who seek care for palpitations are found to have any form of dysrhythmia

(mostly supraventricular). Only 1.6% of patients investigated for palpitations suffer SCD, although this figure rises to 18%–33% for the subgroup with presumed cardiac syncope.^{1,2} Specific stratification by age group is not available; however, it is reasonable to assume that risk in both categories is significantly lower in patients under 40 years of age. One of the causes of dysrhythmic sudden cardiac death in young adults with structurally normal hearts is a relatively recently described entity named Brugada syndrome.⁴

Case report

A 29-year-old female presented to the ED after an episode of palpitations that began 30 minutes earlier, while driving her car, and included a “racing, pounding heart,” light-head-

*Emergency Department, Royal Alexandra Hospital, Edmonton, Alta.

†3rd-year resident, Emergency Medicine Program, Division of Emergency Medicine, Faculty of Medicine and Dentistry, University of Alberta, Edmonton, Alta.

‡Professor, Director, Studies in Medical Organizations, Department of Family Medicine and Division of Emergency Medicine, Faculty of Medicine and Dentistry, University of Alberta, Edmonton, Alta.

Received: Dec. 4, 2004; final submission: July 6, 2005; accepted: July 7, 2005

This article has been peer reviewed.

Can J Emerg Med 2005;7(5):347-50

edness, nausea, diaphoresis and a feeling she was “going to die!” After she pulled over to the side of the road, the symptoms abated spontaneously and she drove herself to the hospital. Further history revealed 3 milder episodes of palpitations during the 3 previous days, for which she had not sought medical attention. She had no prior medical problems and was not on any medications. When asked about sudden cardiac death in young relatives, she reported that a maternal uncle had died at age 35 for unknown reasons.

On examination, her vitals signs were normal except for sinus tachycardia at 110 beats/min, which slowed down to 75 beats/min without any intervention. The remainder of her exam was normal. The electrocardiogram (ECG)

showed subtle downsloping ST-segment elevation in leads V₁ and V₂ suggestive but not diagnostic of Brugada syndrome (Fig. 1). Results of her laboratory investigations and chest x-ray were normal.

The diagnosis of Brugada syndrome was considered, based on her history of palpitations and sense of impending doom, suggestive ECG findings in leads V₁ and V₂, and the history of SCD in a previously healthy young relative. Consequently, an urgent cardiology consultation was requested and the patient was admitted to hospital. Brugada syndrome was confirmed in the electrophysiology lab the next day, where a procainamide challenge triggered an episode of ventricular tachycardia. Two days

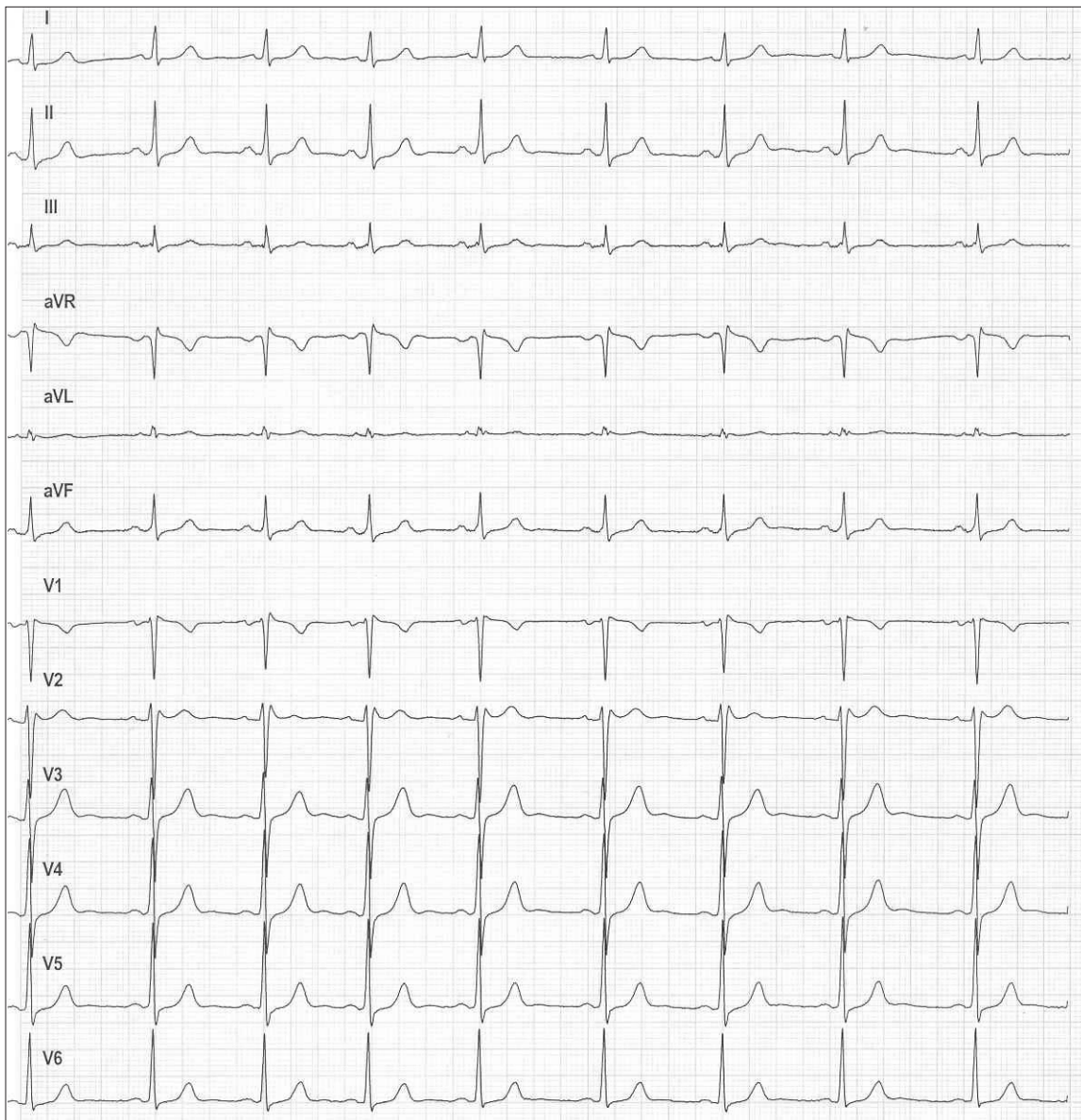


Fig. 1. Patient’s 12-lead ECG.

later an automated implantable cardioverter defibrillator (ICD) was placed, and the patient was discharged in stable condition.

Discussion

Brugada syndrome was described by Pedro and Josep Brugada in 1992 as a cause of sudden cardiac death.² It is characterized by a right bundle branch block (RBBB) pattern, often incomplete, in V_1 and V_2 , ST-segment elevation in the right precordial leads, which is often transient, a structurally normal heart and the propensity for life-threatening ventricular tachydysrhythmias. The elevated ST segments seen in Brugada syndrome are limited to leads V_1 – V_3 and they are slowly downsloping, with T-wave inversion (Fig. 2). The prominent S wave in the lateral precordial leads (typical of RBBB) is often absent in Brugada syndrome, suggesting this may not be true RBBB.

Epidemiology and inheritance

Brugada syndrome is most prevalent in young adult males of Southeast Asian descent, but it has been documented in both genders, all age groups and a variety of ethnic populations, accounting for 0.05%–0.6% of cases of SCD, depending on the population studied.^{5–7} It follows an autosomal dominant inheritance pattern with variable penetrance and expression. In approximately 25% of families, Bru-

gada syndrome is the result of a defect in the *SCN5A* gene on chromosome three, which encodes for the alpha-subunit of the sodium channel. In another 25% of cases the inheritance pattern is not clear but is felt to be an allelic disorder of the sodium-channel gene. The remaining 50% of cases have no family history and are postulated to be the result of sporadic mutation.^{8,9}

Pathophysiology

It appears that sodium channels of the right ventricular epicardium are affected and those in the endocardium are not. This alteration of action potential in the epicardium but not in the endocardium causes differential repolarization and refractoriness across the myocardium, leading to a vulnerable period during which a premature impulse or extra-systole can trigger a re-entrant dysrhythmia.^{5,9,10} Sodium-channel dysfunction may be intermittent and consequently so can the ECG abnormalities, resulting in concealed forms of Brugada syndrome. Certain physiological and external factors can unmask or exacerbate the channel dysfunction. These include febrile episodes, autonomic imbalance, electrolyte disturbances, and drugs that affect the sodium channels — particularly class IA and IC anti-dysrhythmics, tricyclic antidepressants, lithium, benadryl and cocaine. There also appears to be a circadian pattern with more events occurring during sleep or rest when there is less sympathetic activity.⁷

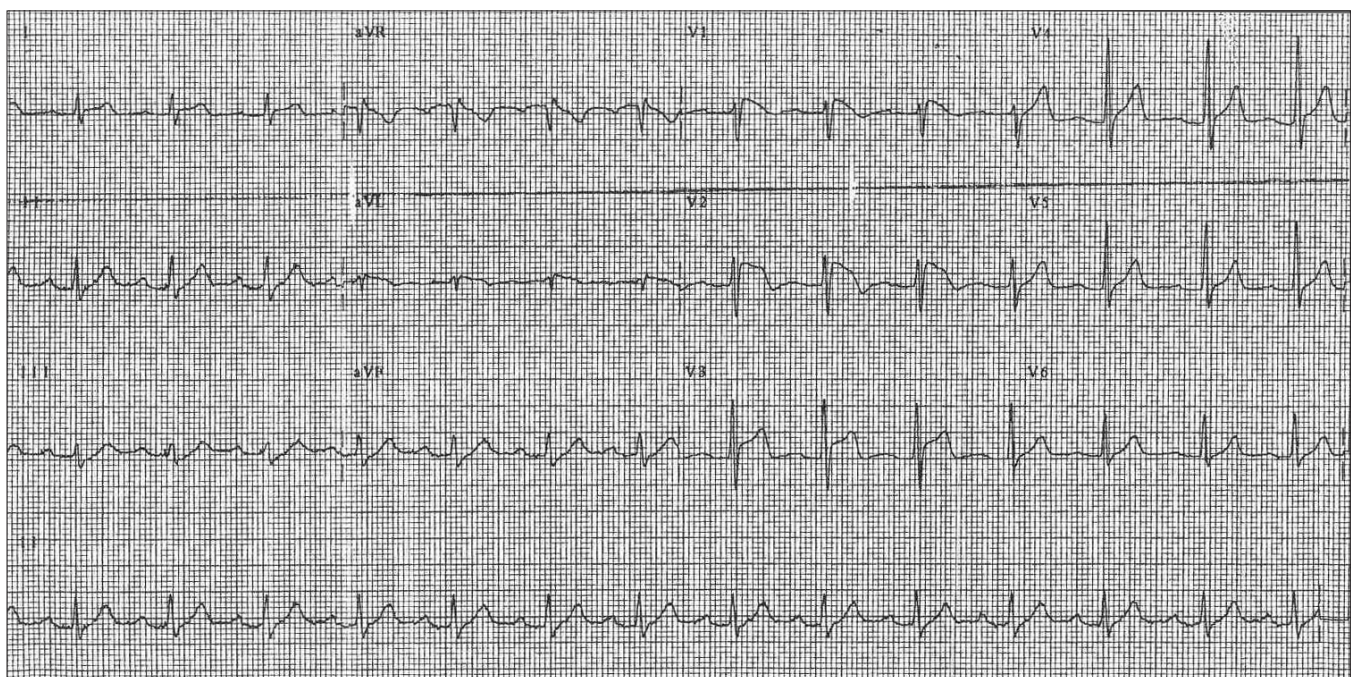


Fig. 2. The typical 12-lead ECG of a patient with Brugada syndrome. In leads V_1 and V_2 one can see an RSR complex with elevation of the ST segment.

Clinical presentation

Potentially lethal cardiac dysrhythmias, notably polymorphic ventricular tachycardia, may occur. If such dysrhythmias terminate spontaneously, patients may present with palpitations or syncope; if these dysrhythmias persist, they eventually degenerate into ventricular fibrillation. Classic findings on the resting ECG are right precordial lead ST-segment elevations that cannot be explained by ischemia, pericarditis, electrolyte or metabolic disorders, central or autonomic nervous system disorders, or early repolarization syndrome. Unfortunately, not all patients will have a characteristic ECG and positive family history; therefore cardiology consultation for procainamide electrophysiological provocative testing is recommended in appropriate patients with suspected cardiac syncope. Patients who present with non-cardiac symptoms but have typical Brugada ECG abnormalities on an incidental ECG should also have urgent cardiology consultation for consideration of provocative testing. This is imperative in light of the fact asymptomatic and symptomatic patients have a similar prognosis.

The mortality rate for untreated Brugada syndrome may be as high as 10% per year, even in asymptomatic patients with typical findings on the resting ECG.⁸ Brugada syndrome may be responsible for 4%–12% of all sudden cardiac deaths and up to 20% of SCD in individuals with structurally normal hearts. Long QT syndrome, dysrhythmogenic right ventricular cardiomyopathy, pre-excitation syndromes and idiopathic ventricular fibrillation make up the rest.⁵

Treatment

To date, no pharmacological agents have improved survival,⁵ however implantable cardiac defibrillators reduce 10-year mortality to approximately 0%.⁷ Although the incidence of ventricular dysrhythmic events is similar in patients receiving an ICD, beta-blocker or amiodarone, only the ICD prevents SCD.¹¹

Conclusions

Brugada syndrome is a significant cause for SCD in young patients and is imminently treatable. Given the high risk of SCD and the effectiveness of implantable defibrillators, it is essential that this uncommon diagnosis be considered in the differential diagnosis of apparently healthy patients who present with syncope or palpitations, particularly those with a positive family history of unexplained SCD.

The diagnosis should also be considered in asymptomatic patients with typical ECG abnormalities. Both groups deserve urgent investigation with procainamide electrophysiological provocative testing and treatment.

Acknowledgements: We acknowledge the departments of Family Medicine and Emergency Medicine, University of Alberta, Edmonton, Alta. Fig. 1 was provided courtesy of Dr. Robert Kruhlak, Department of Emergency Medicine, University of Alberta.

Competing interests: None declared.

References

1. Kapoor WN. Approach to the patient with syncope: Goldman L, Braunwald E, editors. Primary cardiology. Philadelphia (PA): WB Saunders; 1998. p. 144-54.
2. Weber BE, Kapoor WN. Evaluations and outcome of patients with palpitations. *Am J Med* 1996;100:138-48.
3. Barsky AJ. Palpitations, arrhythmias and awareness of cardiac activity. *Ann Intern Med* 2001;134:832-7.
4. Brugada P, Brugada J. Right bundle branch block, persistent ST segment elevation and sudden cardiac death: a distinct clinical and electrodiagnostic syndrome. *J Am Coll Cardiol* 1992;20:1391-6.
5. Antzelevitch P, Brugada P, Brugada J, Brugada R, Shimizu W, Gusak I, et al. Brugada syndrome: a decade of progress. *Circ Res* 2002;92:1114-8.
6. Jones R, Gage A. Brugada Syndrome as the cause of syncope in a 49-year-old man. *Ann Emerg Med* 2000;36:156-9.
7. Mattu A, Rogers RL, Kim H, Perron AD, Brady WJ. The Brugada syndrome. *Am J Emerg Med* 2003;21:146-51.
8. Naccarelli G, Antzelevitch C. The Brugada Syndrome: clinical, genetic, cellular, and molecular abnormalities. *Am J Med* 2001;110:573-81.
9. Corrado D, Buja G, Basso C, Nava A, Thieme G. What is the Brugada syndrome? *Cardiol Rev* 1999;7:191-5.
10. Brugada J, Brugada P, Brugada R. The syndrome of right bundle branch block, ST segment elevation in V1 to V3 and sudden death. *Cardiovasc Drug Ther* 2002;16:25-7.
11. Brugada J, Brugada R, Brugada P. Right bundle branch block and ST segment elevation in leads V1 through V3. *Circulation* 1998;97:457-60.

Correspondence to: Dr. Ivan Steiner, 10240 Kingsway Ave., C.S.C. Rm. 565, Edmonton AB T5H 3V9