

Editorial

Paranasal aspergillosis – a spectrum of disease

Nasal and paranasal sinus aspergillosis has classically been described as having four types: allergic, non-invasive, invasive and fulminant (Sarti and Lucente, 1988). The allergic form is akin to allergic bronchopulmonary aspergillosis and is thought to be a combination of type I and type III immune responses to *Aspergillus* antigens (Katzenstein *et al.*, 1983; Waxman *et al.*, 1987). Non-invasive disease results from the formation of an aspergilloma or fungus ball and behaves as a chronic sinusitis. Both these forms are considered saprophytic, extramucosal disease, benign in nature (Hartwick and Batsakis, 1991). The invasive form as described by Hora (1965) behaves like a malignant neoplasm presenting with a facial mass and proptosis. It is slowly progressive and locally destructive. Fulminant disease (McGill *et al.*, 1980) is angio invasive, rapidly destructive and often fatal. The histopathological changes associated with these clinical forms have been well described by Milroy *et al.* (1989). However analysis of previously reported cases does not demonstrate clear distinctions of type or such closely associated patterns of clinical behaviour.

Paranasal aspergillosis should be considered a spectrum of disease as has already been described for pulmonary aspergillosis (Jahrsdoerfer *et al.*, 1979; Gefter *et al.*, 1981) have previously suggested that the differences between invasive and non-invasive are not clear cut and Sarti and Lucente (1988) have proposed that the former type may develop from the latter. Hartwick and Batsakis (1991) described a chronic, indolent form of sinusitis associated with aspergilloma that was considered to have a potential for invasion, proportional to its duration. Several authors (Warder *et al.*, 1975; Weinstein *et al.*, 1976; Miglets *et al.*, 1978; Romett and Newman, 1982; Von Haacke, 1984) and the experience of three cases in our department, have demonstrated that *Aspergillus* infection may produce marked destruction and erosion of the sinuses without fungal tissue invasion. Robb (1986) reported a further case of aspergilloma with a characteristic large mass of fungal mycelia filling the antrum. However the medial wall of the sinus was partially destroyed and tissue invasion was present at the margins of the specimen. These cases, whilst destructive, are less advanced than those reported by Hora (1965) and others (Veress *et al.*, 1973; Jahrsdoerfer *et al.*, 1979; Stevens, 1981; Lowe and Bradley, 1986) which demonstrate frank tissue invasion. They should therefore be considered as clinically semi-invasive, a term already applied to pulmonary aspergillosis (Gefter *et al.*, 1981) and illustrate how the disease may progress from a long-standing non-invasive form to the semi-invasive and slowly progressive, invasive forms.

A range of disease activity may also be detected between the invasive form, developing over many months and the typically rapid, angio invasive fulminant form

developing over days. Fatal cases have been reported with proptosis developing over months and subsequent autopsies demonstrating later vascular invasion (Stevens, 1981; Milroy *et al.*, 1989). The case described by Milroy *et al.* (1989) also had histological features of aspergilloma. Fulminant disease can be seen to have arisen from slowly progressive, invasive lesions. In the immunocompromised patient however fulminant disease usually arises *de novo*.

Allergic *Aspergillus* sinusitis (AAS) is considered essentially a saprophytic condition with a benign course. Interestingly however Hartwick and Batsakis (1991) revealed 28 per cent of patients reported with AAS to have bone expansion or erosion of the involved sinuses. Dunlop and Bilson (1988) also described a case that resulted in visual failure due to orbital involvement. Thus a spectrum of disease severity beginning with benign AAS can also be demonstrated. Despite such a capacity for destruction, tissue invasion by *Aspergillus* has not yet been described in this condition (Waxman *et al.*, 1987). However once a cavity has been created an aspergilloma may develop within it by continued saprophytic growth. This may explain why AAS may progress or recur despite treatment.

Paranasal and nasal aspergillosis should be considered as a potentially progressive spectrum of disease. It may be classified as:

- (1) Non-invasive, either aspergilloma or allergic in type.
- (2) Semi-invasive, being locally destructive without tissue invasion.
- (3) Invasive, representing true fungal tissue invasion either non-fulminant or fulminant in course (see Figure 1).

Middle meatal obstruction (which may have been caused by AAS) decreases sinus ventilation, lowers the pH and favours growth of hyphae as a fungus ball (Stammberger, 1985). This situation is paralleled by growth of *Aspergillus* in a lung cavity. The aspergilloma will cause further obstruction, act as a foreign body stimulus for chronic granulomatous inflammation and perpetuate a vicious circle that may produce semi-invasive disease. Subsequent bacterial and viral superinfection will further obstruct the natural sinus ostia and damage mucosa, so allowing fungal invasion. Disruption of local anatomy and defences has previously been considered a cause for saprophytic disease becoming invasive in the lungs (Spiteri, 1986). Local destruction will increase the cavity size and allow further proliferation of hyphae. Long-standing disease may result in vascular invasion and the development of fulminant disease. Aspergilloma may secondarily grow in the local tissue defect (Milroy *et al.*, 1989) and so complicate any of the other forms. Thus any type of paranasal aspergillosis may progress to or be associated with more aggressive disease, illustrating the

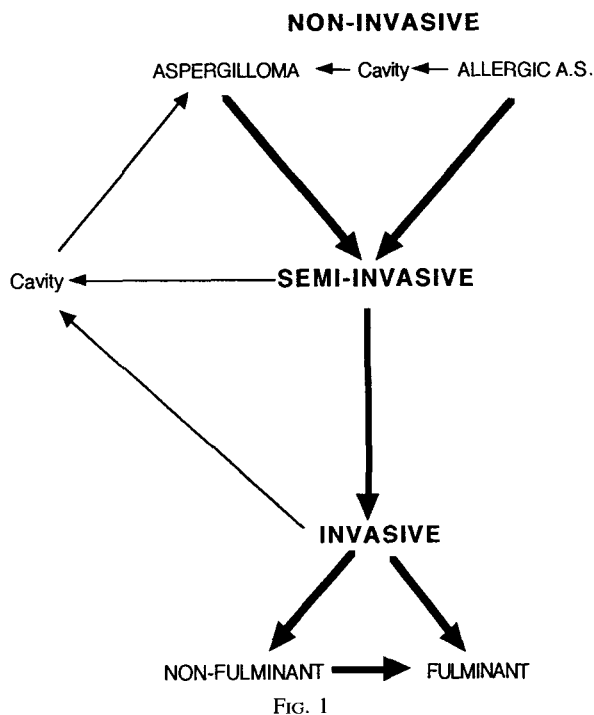


FIG. 1

Flow chart to illustrate the potential progressive spectrum of disease of paranasal sinus aspergillosis. Aspergilloma may complicate cavities formed by other forms of the disease. (Allergic A.S. = Allergic *Aspergillus* Sinusitis).

importance of early recognition of this increasingly encountered disease (Stammberger, 1985).

Non-invasive disease requires surgical debridement and sinus ventilation. Semi-invasive disease should be treated with adjuvant itraconazole (400 mg once daily or less; Hay *et al.*, 1987) as disease may not be eradicated and so may progress after surgery alone (Weinstein *et al.*, 1976; Romett and Newman, 1982). This new triazole agent is well tolerated, unlike amphotericin B, and has good activity against *Aspergillus* species. The drug also has good bioavailability after oral administration and penetrates body fluids and tissues well. Invasive disease whether slowly progressive or fulminant requires, in addition to surgery, intravenous amphotericin B with or without flucytosine. This should be followed by long-term oral itraconazole. AAS in addition to surgical removal and aeration may also be treated with steroids (Hartwick and Batsakis, 1991). Antifungal agents have not yet been advocated in this condition despite patient groups with persistent or recurring disease.

JULIAN ROWE-JONES,
Royal Surrey County Hospital,
Guildford.

References

- Dunlop, I. S., Billson, F. A. (1988) Visual failure in allergic *Aspergillus* sinusitis: case report. *British Journal of Ophthalmology* **72**: 127–130.
- Gefter, W. B., Weingrad, T. R., Epstein, D. M., Ochs, R. H., Miller, W. T. (1981) 'Semi-invasive' pulmonary aspergillosis. *Radiology* **140**: 313–321.
- Hartwick, R. W., Batsakis, J. G. (1991) Sinus aspergillosis and allergic fungal sinusitis. *Annals of Otolaryngology and Rhinology* **100**: 427–430.
- Hay, R. J., Dupont, B., Graylick, J. R. (1987) First international symposium on itraconazole. *Review of Infectious Diseases* **9** (suppl): 1–3.
- Hora, J. F. (1965) Primary aspergillosis of the paranasal sinuses and associated areas. *Laryngoscope* **75**: 768–773.
- Jahrsdoerfer, R. A., Ejercito, V. S., Johns, M. M. E., Cantrell, R. W., Sydnor, J. B. (1979) Aspergillosis of the nose and paranasal sinuses. *American Journal of Otolaryngology* **1**: 6–14.
- Katzenstein, A. A., Sale, S. R., Greenberger, P. A. (1983) Allergic *Aspergillus* sinusitis: a newly recognized form of sinusitis. *Journal of Allergy and Clinical Immunology* **72**: 89–93.
- Lowe, J., Bradley, J. (1986) Cerebral and orbital *Aspergillus* infection due to invasive aspergillosis of ethmoid sinus. *Journal of Clinical Pathology* **39**: 774–778.
- McGill, T. J., Simpson, G., Healy, G. B. (1980) Fulminant aspergillosis of the nose and paranasal sinuses: a new clinical entity. *Laryngoscope* **90**: 748–754.
- Miglets, A. W., Saunders, W. H., Ayers, L. (1978) Aspergillosis of the sphenoid sinus. *Archives of Otolaryngology* **104**: 47–50.
- Milroy, C. M., Blanshard, J. D., Lucas, S., Michaels, L. (1989) Aspergillosis of the nose and paranasal sinuses. *Journal of Clinical Pathology* **42**: 123–127.
- Robb, P. J. (1986) Aspergillosis of the paranasal sinuses: a case report and historical perspective. *Journal of Laryngology and Otolaryngology* **100**: 1071–1077.
- Romett, J. L., Newman, R. K. (1982) Aspergillosis of the nose and paranasal sinuses. *Laryngoscope* **92**: 764–766.
- Sarti, J. E., Lucente, F. E. (1988) Aspergillosis of the paranasal sinuses. *Ear, Nose and Throat Journal* **67**: 824–831.
- Spiteri, M. A., McCall, J., Clarke, W. (1986) Successful management of primary invasive pulmonary aspergillosis. *British Journal of Diseases of the Chest* **80**: 297–301.
- Stammberger, H. (1985) Endoscopic surgery for mycotic and chronic recurring sinusitis. *Annals of Otolaryngology* **94** (suppl. **119**): 1–11.
- Stevens, M. H. (1981) Primary fungal infections of the paranasal sinuses. *American Journal of Otolaryngology* **2**: 348–357.
- Veress, B., Malik, O. A., El Tayeb, A. A., El Daoud, S., Mahgoub, E. S., El Hassan, A. M. (1973) Further observations on the primary paranasal *Aspergillus* granuloma in the Sudan. *American Journal of Tropical Medicine and Hygiene* **22**: 765–772.
- Von Haacke, N. (1984) Aspergillosis of the paranasal sinuses. *Journal of Laryngology and Otolaryngology* **98**: 193–197.
- Warder, F. R., Chikes, P. G., Hudson, W. R. (1975) Aspergillosis of the paranasal sinuses. *Archives of Otolaryngology* **101**: 683–685.
- Waxman, J. E., Spector, J. G., Sale, S. R., Katzenstein, A. A. (1987) Allergic *Aspergillus* sinusitis: concepts in diagnosis and treatment of a new clinical entity. *Laryngoscope* **97**: 261–266.
- Weinstein, M., Theron, J., Newton, T. H. (1976) Aspergillosis involving the sphenoid sinus. *Neuroradiology* **11**: 137–139.