

Inflammatory response of young rabbits to calicivirus infection

R. M. Marques^{*}, A. P. Águas^{*}, A. Costa-e-Silva^{*} and
P. G. Ferreira^{*}

^{*} Department of Anatomy, ICBAS (Abel Salazar Institute for Biomedical Science) and UMIB (Unit for Multidisciplinary for Biomedical Research), University of Porto, Largo Professor Abel Salazar, 2, 4099-003 Porto, Portugal
ramachado.marques@gmail.com

Caliciviruses cause rabbit haemorrhagic disease (RHD) that kills more than 90% of the infected adult animals within 1 a 3 days of infection. The virus replicates in the liver and causes a fulminant hepatitis in adult rabbits leading to RHD [1]. A mystery of the calicivirus infection is that young rabbits (less than 8-weeks old) are resistant to the infection, in spite of undergoing viral replication in the liver and of expressing transient hepatitis [2,3]. Heterophils were the predominant inflammatory cells seen in hepatic tissue of infected adult rabbits, whereas mononuclear cells dominated the inflammatory infiltrates of the infected young rabbits (4-weeks-old) [4]. In order to define the role of inflammation in the pathogenesis of the calicivirus infection, we have studied the cellular inflammatory response in young rabbits experimentally infected by calicivirus. For this, we have used transmission electron microscopy (TEM) and flow cytometry to identify the inflammatory cells that infiltrate the hepatic tissue of young rabbits at 48 hours of calicivirus infection. In same infected rabbits, lymphoid organs (spleen and thymus) were used to quantify by flow cytometry the total number of leukocytes seen inside these organs. TEM showed that the majority of hepatocytes of infected young rabbits did not present ultrastructural changes and the infiltrates were made up mostly of lymphocytes that depicted membrane contacts with the cell surface of undamaged hepatocytes (fig.1). These lymphocytes could correspond to B-lymphocytes, the major populations of leukocytes that were increased at 48 hours of infection, as we have founded by flow cytometry, in hepatic and splenic tissues. Macrophages and T-lymphocytes were also significantly increased in liver of infected young animals ($p < 0.001$ and $p < 0.05$, respectively) (fig. 2 and 3). We did not observe differences in the number of T-lymphocytes population of the thymus between the infected and control rabbits (fig. 4). We conclude that lymphocytes prevailed in mononuclear infiltrates seen in liver tissue of young rabbits at 48 hours of infection. This liver lymphocytic infiltration of young rabbits suggests the expression of viral antigens on the surface of liver cells of the RHD-resistant animals. In fact, we have recently documented a rise in the tittle of specific antibodies measured by ELISA in sera of infected young rabbits.

References

- [1] P.G. Ferreira, A. Costa-e-Silva, M.J.R. Oliveira, E. Monteiro, E.M. Cunha, A.P. Águas, *Res Vet Sci*, 80 (2006) 218.
- [2] P.G. Ferreira, A. Costa-e-Silva, E. Monteiro, M.J.R. Oliveira, A.P. Águas, *Res Vet Sci*, 76 (2004) 83.
- [3] P.G. Ferreira, A. Costa-e-Silva, A.P. Águas, *Res Vet Sci*, 81 (2006) 362.
- [4] P.G. Ferreira, A. Costa-e-Silva, M.J.R. Oliveira, E. Monteiro, A.P. Águas, *Vet Immun Immunopath*, 10 (2005) 217.

This investigation was supported by a research grant from FCT/Portugal (PPCDT/CVT/59943/2004).

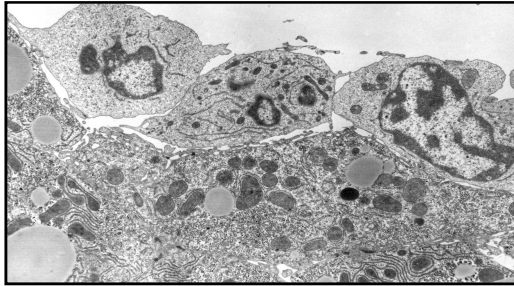


Fig.1. Electron micrograph of a thin section of liver of a young rabbit infected with caliciviruses. Three lymphocytes (top in the figure) are seen attached to the cell surface of the hepatocytes that show no significant ultrastructural changes. (Original magnification x4800).

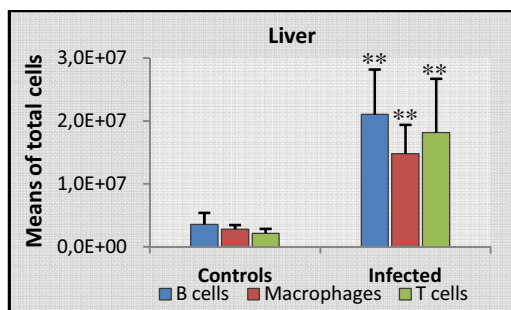


Fig.2. Means of total leukocytes (B cells, T cells and macrophages) present in the liver of control rabbits (n=6) and infected young rabbits (n=8). ANOVA (**p<0,001).

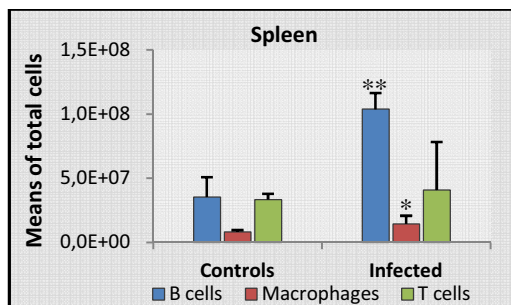


Fig.3. Means of total leukocytes (B cells, T cells and macrophages) present in the spleen of control rabbits (n=6) and infected young rabbits (n=8). ANOVA (* p<0,05) (** p<0,001)

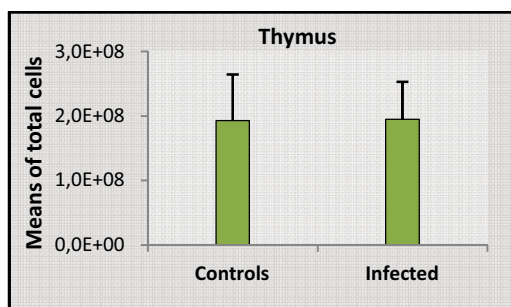


Fig.4. Means of total T lymphocytes present in the thymus of control rabbits (n=6) and infected young rabbits (n=8). Statistically significant differences was not observed.