

## Clinical Records

Joshua M Sorrentino takes responsibility for the integrity of the content of the paper

**Cite this article:** Sorrentino JM, Al Afif A, Magner WJ, Sigurdson SL, Davies JM, Fenstermaker RA, Ghannam M, McSpadden RP. Adipofascial anterolateral thigh free flap in head and neck reconstruction: a case series. *J Laryngol Otol* 2025;1–5. <https://doi.org/10.1017/S0022215124001385>

Received: 31 March 2024

Revised: 9 June 2024

Accepted: 27 June 2024

### Keywords:


cancer; head and neck surgery; naso-pharynx; skull base reconstruction

### Corresponding author:

Joshua M Sorrentino;

Email: [jmsorren@buffalo.edu](mailto:jmsorren@buffalo.edu);

# Adipofascial anterolateral thigh free flap in head and neck reconstruction: a case series

Joshua M Sorrentino , Ayham Al Afif, William J Magner, S Lynn Sigurdson, Jason M Davies, Robert A Fenstermaker, Moleca Ghannam and Ryan P McSpadden

Head and Neck Reconstructive Surgery Department, Roswell Park Comprehensive Cancer Center and Jacobs School of Medicine and Biomedical Sciences, University of Buffalo, New York, USA

## Abstract

**Background.** The adipofascial anterolateral thigh (AF-ALT) free flap represents a versatile technique in head and neck reconstructions, with its applications increasingly broadening. The objective was to detail the novel utilization of the AF-ALT flap in orbital and skull base reconstruction, along with salvage laryngectomy onlay in our case series.

**Method.** We conducted a retrospective analysis at Roswell Park Comprehensive Cancer Center, spanning from July 2019 to June 2023, focusing on patient demographics and reconstructive parameters data.

**Results.** The AF-ALT flap was successfully employed in eight patients (average age 59, body mass index [BMI] 32.0) to repair various defects. Noteworthy outcomes were observed in skull base reconstructions, with no flap failures or major complications over an average 12-month follow-up. Donor sites typically healed well with minimal interventions.

**Conclusion.** Our series is the first to report the AF-ALT flap's efficacy in anterior skull base and orbital reconstructions, demonstrating an additional innovation in complex head and neck surgeries.

## Introduction

Head and neck reconstruction is pivotal in treating patients with various oncologic, traumatic, and congenital defects. The advent of free flaps has revolutionized this domain, providing superior outcomes with more versatility.<sup>1</sup> Despite their advantages, challenges such as donor site morbidity, extended operative times, and the need for specialized microsurgical skills persist. Various free flaps are utilized in head and neck reconstruction, each with their unique advantages and disadvantages.<sup>2</sup>

The anterolateral thigh (ALT) free flap has emerged as a workhorse, with the adipofascial ALT (AF-ALT) free flap variation presenting specific benefits.<sup>3</sup> Comprising solely adipose tissue and fascia, the AF-ALT can be more readily used in overweight patients as it eliminates the need to trace perforators to the skin surface. The donor site allows for tension-free closure. First described in 2008, AF-ALT flaps have addressed various defects in the head and neck including the oral cavity, pharynx, and those related to osteoradionecrosis, with a robust vascular supply, adaptable tissue and minimal donor site morbidity.<sup>4–7</sup> However, studies on their use in salvage laryngectomy, parotidectomy, or skull base reconstructions are limited.

Herein, we present our case series utilizing AF-ALT flap in eight patients with a variety of head and neck complex defects, including maxillectomy, salvage total laryngectomy and parotidectomy with facial skin defects. We also report on the novel application of this flap in anterior skull base with orbital exenteration.

## Case Series

### Ethical Considerations

Under institutional review board (IRB) approval for retrospective studies, a single-center review of adults who underwent head and neck reconstruction using the AF-ALT free flap from July 2019 to June 2023 was performed. Data collected include demographic information, patient outcomes, complications, procedural details, and follow up. All patients were presented and managed as per a multidisciplinary tumor board.

### Participants

Our retrospective review comprised eight patients, with a mean age of 59 years (range 26–80 years) and a mean body mass index (BMI) of 32.0 (range 20.4–58.4). Most patients (63 per cent) were male, and 50 per cent received pre-operative radiation therapy.

The defects that an AF-ALT flap was used for include maxillectomy defects in three patients (cases 1–3), salvage total laryngectomy defects in two patients (cases 4 and 5), anterior skull base defects with orbital exenteration in two patients (cases 6 and 7), and a parotidectomy with facial skin defect (case 8). The most common diagnosis was squamous cell carcinoma. Seventy-five percent of patients reported a smoking history, and 38 per cent were current smokers. Detailed descriptions of demographic and pathologic information are shown in Table 1.

### Surgical Methods

The AF-ALT flap was harvested using the ABC perforator method and utilising intra-operative Doppler.<sup>8</sup> Figure 1 provides further detail on surgical technique and depictions of anatomical landmarks, including the anterior superior iliac spine, superolateral patellar border, rectus fascia, perforators and a vascular pedicle from the lateral circumflex femoral artery. All procedures were performed through a two-team approach, and in cases of skull base reconstruction, a neurosurgical team was also involved. All reconstructions were performed by one of two head and neck surgeons (A.A. and R.P.M.) employing a very similar surgical technique for flap harvest and microvascular anastomosis. Patients underwent regular follow-up during recovery and following discharge, monitoring for recurrence, donor site morbidity and flap failure.

### Outcomes and Follow-Up

The average operative time was 11 hours 45 minutes (range: 07h:54m to 20h:33m), which includes the resection and reconstruction. A detailed description of surgical details, along with complications, donor site morbidity and functional outcomes, can be seen in Table 2. All microvascular anastomoses were performed to vessels in the ipsilateral neck, with the most common arteries being facial and superior thyroid, and most common veins being the facial and external jugular. Split thickness skin graft (STSG) reconstruction to the recipient site was used in both cases of skull base reconstruction and parotidectomy with facial skin.

There were no flap failures or partial flap necrosis, and no flap take-back procedures were required. No cerebrospinal

fluid leaks were observed in patients who underwent skull base reconstruction, and no salivary leaks in the cases of salvage laryngectomy onlay reconstruction. The average inpatient time was 13 days (range: 4–22 days). The average follow-up period was 12 months (range: 2–36 months). Figures 2 and 3 provide images for two representative cases.

### Complications and Adverse Events

One patient experienced partial skin graft loss. Three patients developed post-operative infections unrelated to the flap; one required operating room washout to manage neck wound infection. As for donor site morbidity, one patient experienced partial skin loss at the donor site, managed conservatively with local wound care and dressings. No other donor site morbidity, such as hematoma, seroma, or wound dehiscence, was observed in the remaining patients.

### Discussion

In this retrospective study, we have highlighted the versatility of the AF-ALT free flap in head and neck reconstruction. This is the first report utilizing this flap in anterior skull base reconstruction with orbital exenteration and adds to the literature on its use in salvage laryngectomy, parotidectomy, and maxillectomy.<sup>9–11</sup>

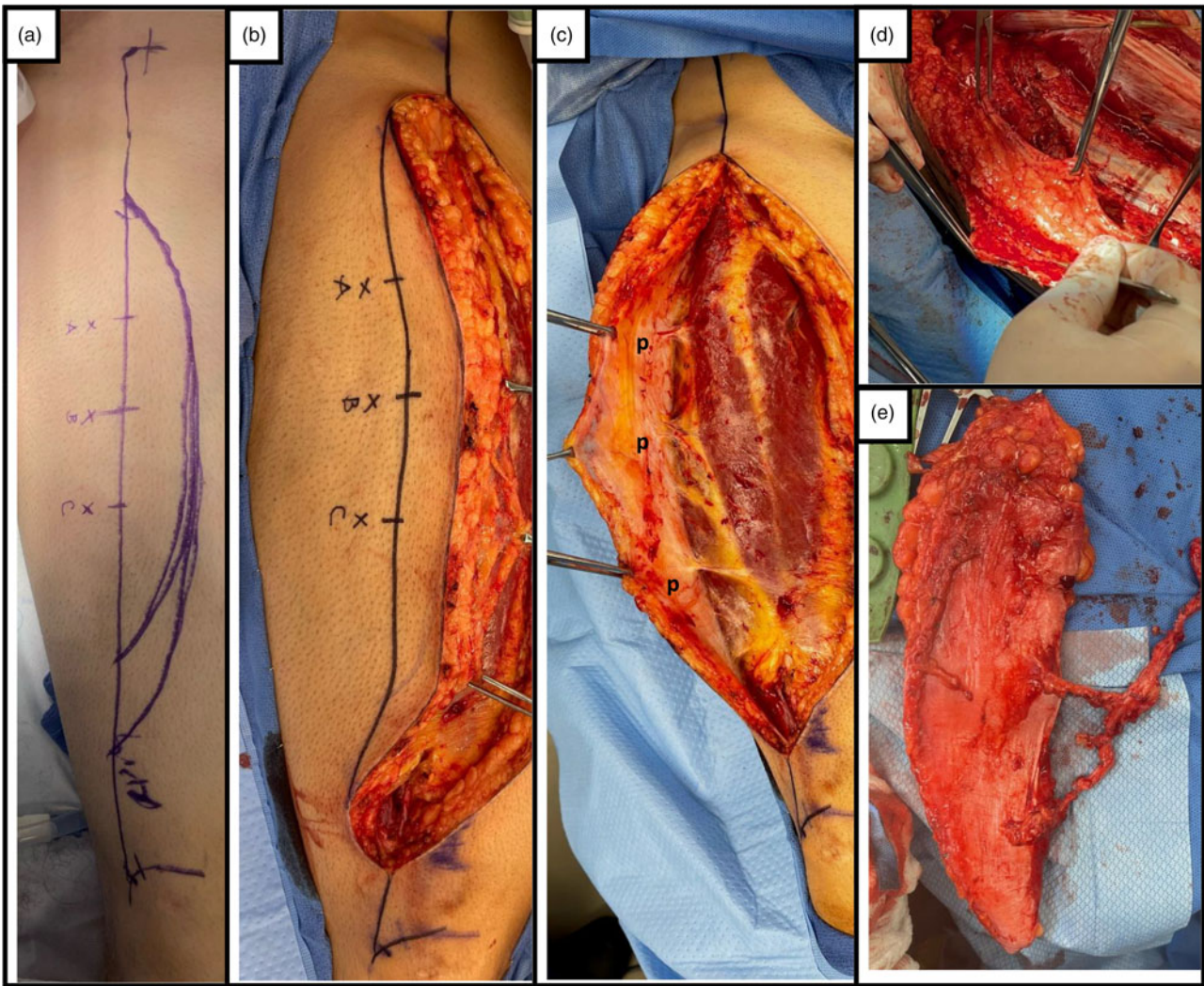
In agreement with previous studies,<sup>4–7</sup> the functional and cosmetic outcomes yielded were satisfactory, highlighting the potential role of the AF-ALT free flap in reconstructing complex defects. The relatively low donor site morbidity in our case series is encouraging. We did not encounter any seromas, as we routinely use negative suction drains. One patient in our study complained of pain at the donor site, especially with leg flexion, which is a common complication with ALT free flaps. In one patient, we did encounter partial skin loss at the donor site, which we believe is due to the proximity of the adipofascial tissue to the epidermis, evident by the patient's low BMI of 20 kg/m<sup>2</sup>. In such cases, harvesting a skin paddle, or choosing an alternative flap is feasible.

While the AF-ALT free flap has been extensively described in head and neck reconstructions, our study uniquely applies it to reconstruct orbital and anterior skull base defects—a significant departure from the traditional use of muscle flaps like the rectus abdominus or vastus lateralis.<sup>12–14</sup> This innovation is

**Table 1.** Demographic and pathologic descriptions of AF-ALT cases 1–8

Case no.	Age	Sex	Smoking history	Pathology	Defect
1	61	M	Non-smoker	SCC (T3N1M0)	Right maxillary alveolar ridge
2	79	F	Former smoker (unspecified)	SCC (T4bN0M0)	Right maxillary alveolar ridge
3	80	F	Non-smoker	SCC (T4aN1M0)	Right maxillary alveolar ridge
4	54	F	30 pack years	SCC (T3N0M0)	Salvage laryngectomy onlay
5	60	M	32 pack years	SCC (T3N0M0)	Salvage laryngectomy onlay
6	43	M	Former smoker (unspecified)	SCC (T4bN0M0)	Right orbital sinonasal and skull base
7	26	M	8 pack years	Esthesioneuroblastoma (Kadish D, Hyams Grade IV)	Left orbital sinonasal and skull base
8	71	M	Former smoker (unspecified)	SCC (T3N1M0)	Right salvage total temple and cheek

Abbreviations: AF-ALT = adipofascial anterolateral thigh; M = male; F = female; SCC = squamous cell carcinoma.



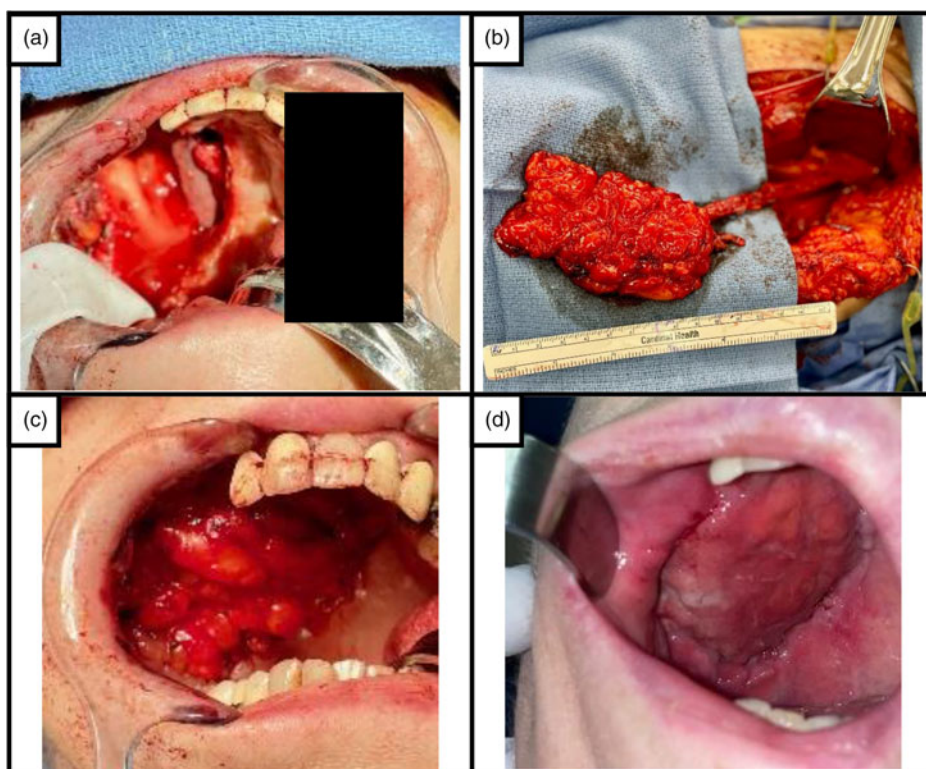
**Figure 1.** Harvesting of the adipofascial anterolateral thigh (AF-ALT) free flap with use of the ABC Perforator method.<sup>8</sup> (A) A line is drawn from anterior superior iliac spine (ASIS) to superolateral border of patella. At the midpoint, perforator B is marked; perforator A and C are marked 5 cm on both sides along the same line. The incision is planned 3 cm medially to include the three perforators. (B) The medial flap border incision is made first, down to the rectus fascia. (C) Dissection is performed in the subfascial plane from medial to lateral to identify perforators; in this case, 3 were identified and labeled as (p). Perforator dissection is then performed. (D) The adipofascial flap is sharply separated from the skin, leaving a small cup of fat under the dermis with careful attention around the perforators. (E) The AF-ALT free flap and its pedicle are ready for inset and microvascular anastomoses.

**Table 2.** Free flap characteristics and reconstructive outcomes

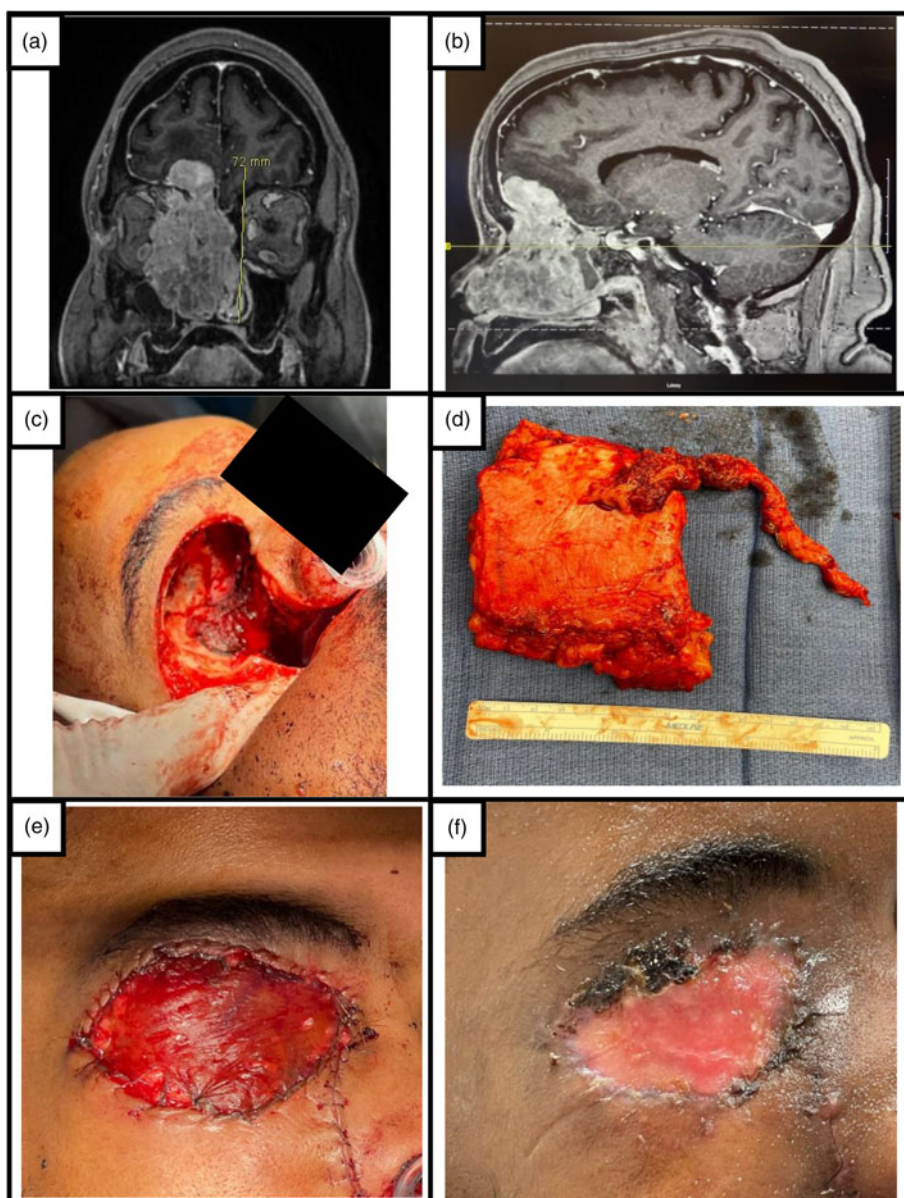
Case no.	Flap size (cm)	Perforator (no.- type)	Arterial anastomoses	Complications	Donor site morbidity	Functional outcome (POD)
1	10 x 6	2- SC	Facial	Flap dehiscence, fistula	Pain with ambulation	Oral feeding (14)
2	4 x 4	1- MC	Lingual	-	-	Oral feeding (44)
3	10 x 7	1- MC	Facial	-	-	Oral feeding (11)
4	Not reported	1- MC	Superior thyroid	Fistula, pharyngo-cutaneous leak, esophageal diverticulum	-	Limited due to recurrence
5	8 x 6	1- SC	Superior thyroid	Neck wound infection	Mild skin desquamation	Oral feeding (60), Voice prosthesis (150)
6	6 x 6	1- MC	Facial	Partial skin graft loss	-	No CSF leaks observed
7	10 x 20	2- SC	Facial	-	-	No CSF leaks observed
8	12 x 9	3- SC	Superior thyroid	Partial skin graft loss	-	-

Abbreviations: CSF = cerebrospinal fluid; MC = musculocutaneous; POD = post-operative day; SC = septocutaneous.





**Figure 2.** Adipofascial anterolateral thigh (AF-ALT) reconstruction of maxillectomy defect (case 1). (A) A 61-year-old female with squamous cell carcinoma of the right upper alveolar ridge, post-resection. (B) Flap at time of harvest, (C) inset, and (D) at 2 months post-operatively.



**Figure 3.** Adipofascial anterolateral thigh (AF-ALT) reconstruction of anterior skull base with orbital exenteration defect (case 6). (A) Coronal and (B) sagittal MRI images depicting the tumor. (C) Defect site post-resection and duraplasty. (D) Harvested AF-ALT free flap. (E) Defect site post-flap placement with overlying split thickness skin graft. (F) Defect site at follow-up 40 days post-operatively.

crucial as the pliability and versatility of the ALT flap allow for precise contouring to complex defects, enhancing functional and aesthetic outcomes. With the AF-ALT, the absence of a skin paddle facilitated ease of flap inset in a three-dimensional manner to fit the defect, while the absence of muscle limited long-term donor site consequences.

In both cases, a duraplasty was performed to repair an intracranial component with no evidence of post-operative cerebrospinal fluid (CSF) leak, highlighting the ability of this flap to bolster the anterior skull base reconstruction. We also optimized flap viability with extended pedicle lengths achieved by meticulous perforator dissection, enabling reliable reach to the ipsilateral neck—a critical adaptation for these complex reconstructions.<sup>15</sup> Lastly, any cutaneous defect can be covered with a split thickness skin graft. In our center, we rely on implantable arterial Dopplers, hand-held Dopplers over the pedicle and serial hourly flap examination. With the absence of a skin paddle, flap examination of the fibrofatty tissue can be challenging. However, in the experience of the authors, bleeding can be easily elicited through a prick with a fine needle up to 72 hours after surgery.

Lastly, and very importantly, we demonstrated the flap's effectiveness in patients with high BMI, challenging the prevailing view of BMI as a relative contraindication for ALT flap use due to its thickness when a skin paddle is desired. We have found that eliminating the skin paddle allows for harvest of a pliable adipofascial flap, which can be easily molded to fit the defect outside the confines of a skin paddle.

The operative times highlighted in our study include total surgical time. In all cases, the ablative and reconstructive surgeons worked simultaneously. Although we observed post-operative complications like infections, the rates were comparable to those published in the literature.<sup>16</sup>

While the results are promising, they are not without limitations. Our study was limited by a relatively short follow-up period. The use of this flap may be limited in patients with a low BMI. It also represents a small case series, and larger studies are required to draw more meaningful conclusions. Additionally, especially in the setting of the orbital defects, the suitability of this flap for prosthetic use remains to be evaluated.

For future research, larger sample sizes, multicenter studies, and comparisons with other free flaps would be beneficial. Further studies with long-term follow-ups will help better understand AF-ALT outcomes and durability.

In conclusion, our study adds to the accumulating evidence supporting the use of the AF-ALT free flap in complex head and neck reconstructions. This study is the first to report on its application in anterior skull base reconstruction with orbital exenteration with utilisation of an extended pedicle to optimize viability. The favourable outcomes, versatility, and low donor site morbidity make it an invaluable tool in the surgeon's armamentarium.

**Financial support.** This study is partially supported by funding from the National Cancer Institute of the National Institutes of Health under Award number: R25CA181003. This grant solely provides a stipend for medical student summer research. The information, content and/or conclusions are those of the authors and should not be construed as the official position or policy of, nor should any endorsements be inferred by National Cancer Institute of the National Institutes of Health or Roswell Park Comprehensive Care Center.

**Competing interests.** The authors declare none

**Ethical standards.** The authors assert that all procedures contributing to this work comply with the ethical standards of the relevant national and institutional guidelines on human experimentation (HRSPP), and with the Helsinki Declaration of 1975, as revised in 2008.

## References

- 1 Blackwell KE. Unsurpassed reliability of free flaps for head and neck reconstruction. *Arch Otolaryngol Head Neck Surg* 1999;**125**:295-9
- 2 Wong CH, Wei FC. Microsurgical free flap in head and neck reconstruction. *Head Neck* 2010;**32**:1236-45
- 3 Park CW, Miles BA. The expanding role of the anterolateral thigh free flap in head and neck reconstruction. *Curr Opin Otolaryngol Head Neck Surg* 2011;**19**:263-8
- 4 Agostini T, Agostini V. Further experience with adipofascial ALT flap for oral cavity reconstruction. *J Plast Reconstr Aesthet Surg* 2008;**61**:1164-9
- 5 Kim D-Y, Alfadil LO, Ahn K-M, Lee J-H. Reconstruction of thin and pliable oral mucosa after wide excision of oral cancer using a trimmed anterolateral thigh free flap as an adipofascial flap. *J Craniofac Surg* 2018;**29**:e394-6
- 6 Xu F, Deng D, Li B, Li L, Liu J, Li B, *et al.* Adipofascial anterolateral thigh free flap in hypopharyngeal and oropharyngeal reconstruction. *Microsurgery* 2022;**42**:586-92
- 7 Agostini T, Russo GL, Zhang YX, Spinelli G, Lazzeri D. Adipofascial anterolateral thigh flap safety: applications and complications. *Arch Plast Surg* 2013;**40**:91-6
- 8 Lin SJ, Rabie A, Yu P. Designing the anterolateral thigh flap without pre-operative Doppler or imaging. *J Reconstr Microsurg* 2010;**26**:67-72
- 9 Elson NC, Martinez DC, Cervenka BP. Current opinions in otolaryngology and head and neck surgery: functional considerations in reconstruction after laryngectomy. *Curr Opin Otolaryngol Head Neck Surg* 2020;**28**:355-64
- 10 Cai Y-C, Shui C-Y, Li C, Sun R-H, Zhou Y-Q, Liu W, *et al.* Primary repair and reconstruction of tumor defects in parotid masseter region: a report of 58 cases. *Gland Surg* 2019;**8**:354-61
- 11 Lin XA, Shi YY, Liu C. The anterolateral thigh flap for reconstruction of the defect after maxillectomy. *J Craniofac Surg* 2020;**31**:e89-92
- 12 Kim SH, Lee WJ, Chang JH, Moon JH, Kang SG, Kim CH, *et al.* Anterior skull base reconstruction using an anterolateral thigh free flap. *Arch Craniofac Surg* 2021;**22**:232-8
- 13 Dang RP, Etttyreddy AR, Rizvi Z, Doering M, Mazul AL, Zenga J, *et al.* Free flap reconstruction of the anterior skull base: A systematic review. *J Neurol Surg B Skull Base* 2021;**83**:125-32
- 14 Bell EB, Cohen ER, Sargi Z, Leibowitz J. Free tissue reconstruction of the anterior skull base: A review. *World J Otorhinolaryngol Head Neck Surg* 2020;**6**:132-6
- 15 Plonowska-Hirschfeld KA, House A, Park AM, Seth R, Heaton CM, Fridirici Z, *et al.* Increasing pedicle reach with musculocutaneous perforator dissection in anterolateral thigh free flaps. *Laryngoscope* 2024;**134**:666-70
- 16 Farquhar DR, Masood MM, Pappa AK, Patel SN, Hackman TG. Predictors of adverse outcomes in free flap reconstruction: a single-institution experience. *Otolaryngol Head Neck Surg* 2018;**159**:973-80