



Radiculomegaly as a key clinical feature in oculo-facio-cardio-dental (OFCD) syndrome: a case report with a novel truncating variant in *BCOR* gene

Original Article

Cite this article: Sauvestre C, Boileau M-J, Caule C, Griffiths D, Schrub F, Chassaing N, and Rooryck C (2024) Radiculomegaly as a key clinical feature in oculo-facio-cardio-dental (OFCD) syndrome: a case report with a novel truncating variant in *BCOR* gene. *Cardiology in the Young* **34**: 2606–2609. doi: [10.1017/S104795112402660X](https://doi.org/10.1017/S104795112402660X)

Received: 17 May 2024
Revised: 3 September 2024
Accepted: 6 September 2024
First published online: 11 October 2024


Keywords:

radiculomegaly; *BCOR* gene; oculo-facio-cardio-dental syndrome; microphthalmia syndromic type 2

Corresponding author:

Clément Sauvestre;
Email: clement.sauvestre@chu-bordeaux.fr

Presented as a poster at EuroDysmorpho 2023 – 33rd European Meeting on Dysmorphology, ERN ITHACA

Clément Sauvestre¹ , Marie-José Boileau², Camille Caule², Didier Griffiths¹, Florian Schrub³, Nicolas Chassaing^{4,6} and Caroline Rooryck^{1,5}

¹Service de Génétique Médicale, CHU Bordeaux, Bordeaux, France; ²Centre de Compétences des Maladies Rares Orales et Dentaires, CCMR O-Rares, CHU de Bordeaux, Bordeaux, France; ³Polyclinique Bordeaux Nord Aquitaine, Bordeaux, France; ⁴Service de Génétique Médicale, Hôpital Purpan CHU Toulouse, Toulouse, France; ⁵Maladies Rares: Génétique et Métabolisme (MRGM), Univ Bordeaux, Bordeaux, France and ⁶Centre de Référence des Affections Rares en Génétique Ophtalmologique CARGO, CHU de Toulouse, Toulouse, France

Abstract

Radiculomegaly is a rare dental anomaly characterised by the enlargement of the root canals of teeth. It is usually associated with oculo-facio-cardio-dental (OFCD) syndrome due to truncating variants in BCL-6 transcriptional corepressor (*BCOR*) (MIM*300485). We present the case of a 21-year-old female patient who was referred to genetics for a polymalformative syndrome including bilateral glaucoma and dental anomalies, especially radiculomegaly. Some others dysmorphic features were right superior lip notch, ogival palate, long philtrum, difficulty in pronation, café-au-lait spots, II-III toe bilateral syndactyly, and macrocephaly. Cone-beam CT confirmed radiculomegaly. The genetic analysis identified a heterozygous pathogenic variant NM_001123385.1:c.2093del (p.Pro698Glnfs*17) in the *BCOR* gene. After genetic diagnosis of OFCD syndrome, cardiac CT-scan revealed a large asymptomatic atrial septal defect that was subsequently surgically closed. Reviews of the literature have previously highlighted the prevalence of radiculomegaly in OFCD syndrome with a positive predictive value of 88.23% and a sensitivity of 75.94%. This case report highlights the importance of radiculomegaly as a clinical sign of OFCD syndrome, emphasising the rarity of non-syndromic radiculomegaly and the benefits of its diagnosis in clinical management, especially in cardiac screening.

Introduction

Radiculomegaly or root gigantism is a rare condition characterised by enlargement of the roots of teeth. It can lead to delayed eruption, malformation of the teeth, and malocclusion. This anomaly may be present as part of a syndromic condition. Most syndromic radiculomegaly has been linked to oculo-facio-cardio-dental syndrome (ORPHA:2712), an X-linked dominant disorder with truncating variants in BCL-6 transcriptional corepressor (*BCOR*). In the literature review by Housley Smith et al.,¹ radiculomegaly has been identified in 60/92 (65%) patients with oculo-facio-cardio-dental (OFCD) syndrome.

OFCD syndrome is a clinical entity with four main clinical features: ocular, dental, cardiac, and facial dysmorphism. The most common ocular abnormalities are microphthalmia and congenital glaucoma. Bilateral glaucoma, such as observed in our patient, has been described in only three patients.² The typical dental abnormalities are radiculomegaly, oligodontia, retained primary teeth, and malocclusion. The main cardiac anomalies are atrial septal defect, ventricular septal defect, and/or persistent ductus arteriosus.³ Facial dysmorphic features are non-specific, including broad nasal bridge or cleft palate.⁴ These four clinical features are present in 41% of cases.⁵ It is also common to find other defects such as skeletal abnormalities including scoliosis, syndactyly, camptodactyly, and radio-ulnar synostosis. Only one patient has been described with macrocephaly.²

On the other hand, non-syndromic radiculomegaly can occur in a sporadic or familial manner, and the inheritance pattern is not fully understood. To date, only 11 cases of non-syndromic, isolated, or unexplored radiculomegaly have been described.^{1,2,6–12} Unfortunately, most of these cases were described in old publications^{2,6,11,12} and were untested for *BCOR* variants. Specifically, some of these cases could be undiagnosed OFCD syndrome such as a young girl with a bilateral congenital cataract,⁹ and a 20-year-old girl with congenital cataract and her brother also presenting with radiculomegaly.² In these cases, a new diagnosis of OFCD

syndrome could have led to cardiac exploration and potential cardiac therapeutics if needed, such as in our case.

The BCOR is implicated as tumour-suppressor gene in acute myeloid leukaemia and myelodysplastic syndrome.¹³ BCOR internal tandem duplication and fusion with cAMP response element-binding protein have been described in central nervous tumours.¹⁴

Here we report a case of a young woman with syndromic radiculomegaly and implication of this finding in her diagnosis strategy.

Case presentation

A 21-year-old female was referred to the Genetics Department because of several physical abnormalities. She is the eldest of five children, born from a non-consanguineous healthy couple. Her siblings are healthy too. She was born with a left glaucoma, which was complicated by cataract on the left eye for which she underwent surgery at the age of 2. Then she had glaucoma in her right eye. She is currently blind in both eyes. Despite this, she had a normal education.

She had enophthalmos of the right eye and exophthalmos of the left eye (a in Figure 1). Other dysmorphic features included a notch in her upper right lip, a high-arched palate, and long philtrum (b in Figure 1). She had II-III toe bilateral syndactyly (c and d in Figure 1). She also had limited pronating of both hands and scoliosis (e in Figure 1). In addition, the patient had multiple café-au-lait spots on her skin. She was 1.73 cm (+1.5 SD) and weighed 57 kg (Median). Her head circumference was measured at 58 cm (+3.3 SD), indicating macrocephaly. At first evaluation, oligodontia, taurodontism, and dental agenesis were noted as dental features (ac in Figure 2), then cone-beam computed tomography identified radiculomegaly affecting several tooth roots (d in Figure 2). X-ray of the forearm revealed radio-ulnar synostosis.

The patient had a normal karyotype result: 46,XX. Given the combination of ophthalmic anomalies and typical dental features (especially radiculomegaly) recognised by a dentist expert in genetic dental diseases, we suspected OFCD syndrome. To confirm this clinical suspicion, we performed Next-Generation sequencing (NGS) sequencing of a panel of 119 genes involved in ocular abnormalities, which specifically include *BCOR*. Genetic analysis identified an undescribed *BCOR* frameshift variant NM_001123385.1:c.2093del (p.Pro698Glnfs*17). Her mother did not carry the *BCOR* variant, which was then assumed to be *de novo* (lethal in males). This variant was absent from databases (GnomAD and ClinVar). This variant was classified as pathogenic, class 5 in American College of Medical Genetics and Genomics (ACMG) classification.

Considering cardiac involvement in OFCD syndrome, an electrocardiogram was performed and revealed a left axis estimate to -49° , an intermediate QRS duration of 110 ms, and an RR' QRS morphology with an S wave >20 ms in lead D1. This pattern may be suggesting incomplete right bundle branch block (RBBB) associated with left anterior hemiblock. Subsequently, an echocardiogram was performed that identified normal left ventricular function with a left ventricular ejection fraction of 55%. The right ventricle/left ventricle ratio is >1 with a right ventricular end-systolic area of 17 cm^2 , a right ventricular end-diastolic area of 32 cm^2 and a right ventricular outflow tract of 39 mm. Right ventricular function appeared to be preserved (S' wave peak at 18 cm/s , fractional shortening of 48%, non-dilated and compliant inferior vena cava) without pulmonary arterial

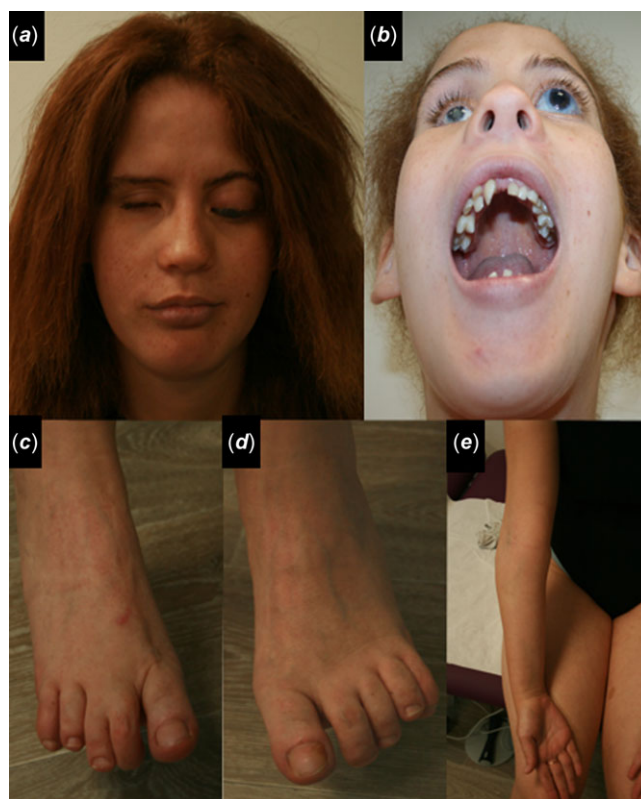

Figure 1. Photographs of dysmorphic features: enophthalmos and long philtrum (a), high-arched palate, dental agenesis (b), 2-3 toe syndactyly (c, d), radio-ulnar synostosis (e).

hypertension. The interatrial septum was visualised as thin and mobile without any aneurysm (ASIA). Cardiac MRI confirmed normal left ventricular function with an estimated left ventricular ejection fraction at 65%. The right ventricular ejection fraction was measured at 48% with a right ventricular end-diastolic volume of 174 ml (110 ml/m^2) and right ventricular end-systolic volume of 91 ml (57 ml/m^2). Finally, a cardiac CT scan confirmed a large atrial septal defect (Figure 2e-f) who has been treated surgically.

Discussion

This case report highlights a rare case of syndromic radiculomegaly in a 21-year-old female patient presenting with severe ocular and dental defects, cardiac abnormalities, and facial dysmorphism. OFCD syndrome diagnosis was the only one considered in the first instance in this case, but other genetic ocular diseases were ruled out at the same time by an NGS panel of 119 genes.

Our case had abnormalities in all four major groups of clinical features but it was the radiculomegaly that most oriented our diagnosis. Initially, in our case, the radiculomegaly was mistaken for taurodontism before the cone-beam computed tomography made the diagnosis. It is important to distinguish taurodontism as the elongation of the pulp chamber with apical displacement of the pulpal floor. Although these two anomalies may appear similar and can both be found in OFCD syndrome patients, they are distinct entities with different implications. Indeed, radiculomegaly has been mainly described in OFCD syndrome, whereas taurodontism is frequent and has been associated with certain ethnic groups.¹⁵

In this case, given the signs of right ventricular dilatation in correlation with RBBB and an estimated Qp/Qs ratio of 1.3, we

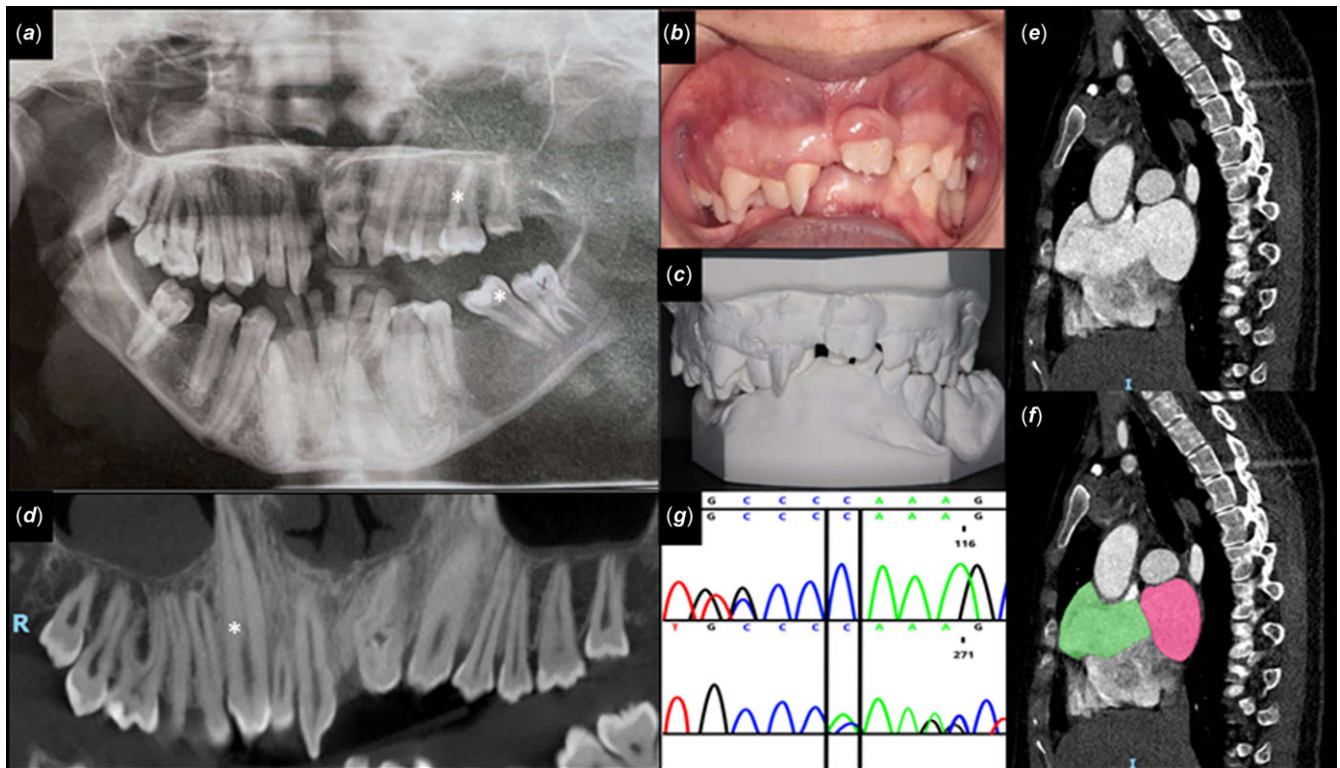


Figure 2. Radiological (a), clinical (b), 3D scanner reconstruction (c), and cone-beam computed tomography (d) dental findings: radiculomegaly are marked (white *). Cardiac scan sagittal view showing the large atrial septal defect (e) with dilated right atrium in green and left atrium in red (f). Electropherogram of GrCh37: NM_001123385.1(BCOR): c.2093delC; p.(Pro698Glnfs*17) (g).

suspected a left-to-right shunt that was not visualised on the echocardiography. Indeed, 67% of patients with OFCD syndrome presented with at least one cardiovascular abnormality.³ Therefore, we proceeded to perform cardiac MRI and cardiac CT scan to better assess cardiac morphology. Cardiac MRI is suitable for measuring volumes and calculating the right ventricular ejection fraction, which can be challenging to obtain through routine echocardiography due to right ventricle location just beneath the sternum. Additionally, it can better estimate the presence and characterise an atrial septal defect than echocardiography. Cardiac MRI is not operator dependent and can therefore be reproducible over time for follow-up. However, echocardiography by a trained physician remains the gold standard in congenital heart defects (CHD) assessment.¹⁶ In these situations, it would be interesting to evaluate the benefits of cardiac MRI.

Originally described as a separate syndrome, OFCD syndrome is now part of a clinical spectrum with BCOR diseases. OFCD syndrome has X-linked dominant transmission (presumed lethal in males). It is due to heterozygous truncating variants in BCOR (BCL6 corepressor gene), occurring mostly *de novo* in female patients⁵. Skewed X-inactivation is in favour of wild-type allele in informative cases, and severity of defects appears to be related to it.¹⁷ To date, OFCD syndrome has been described in 92 females (from 63 families) worldwide. In our case, the BCOR truncating variant presumably occurred *de novo* as it was not present in the mother and unlikely to be carried by the asymptomatic father (lethal forms in males). On the other hand, analyses in men with syndromic microphthalmia type 2 (MIM #300166) showed BCOR missense variants.¹⁷ Interestingly, to complete the spectrum, one male patient with OFCD syndrome has been described with

terminal nonsense variant¹⁸ and another with hemizygous variant within the donor splice site of intron 12, predicted to result in aberrant splicing in frame.⁵ These two last variants may not have a loss-of-function effect as the variants in the lethal forms in males. These findings suggest genotype–phenotype correlation with BCOR truncating variants linked to OFCD syndrome and missense variants linked to microphthalmia syndromic type 2.

BCOR located in Xp11.4 is well known to be involved in cancer either through a loss-of-function mechanism¹⁹ or as a partner fusion gene.²⁰ BCOR is also thought to play a key role in the Isl1-expressing lineage for cardiac outflow tract septation, which may explain the cardiac septal defects.²¹ However, the mechanism appears to be different in radiculomegaly. BCOR is expressed in both the dental epithelium and the mesenchyme during the early tooth development and thought to be involved in the inhibition of zinc finger protein multitype 2, which regulates alkaline phosphatase, leading to hyperactive root formation.²² These mechanisms may link BCOR mutations to the observed phenotypes.

Despite cases of non-syndromic or isolated radiculomegaly described, radiculomegaly seems to be a pathognomonic feature of OFCD syndrome. Indeed, among 92 cases with OFCD syndrome, at least 65.2% (60/92) have radiculomegaly. Moreover some cases of unexplored radiculomegaly might be unsolved OFCD syndrome.^{9,23} To our knowledge, radiculomegaly is not associated with any other genetic syndrome. Radiculomegaly could not be detected in 13 of the 92 patients with OFCD syndrome because of their young age.¹ These data indicate that the positive predictive value for radiculomegaly in OFCD syndrome is 88.23% (60/[60 + 8]), with a sensitivity of 75.94% (60/[60 + 19]). This is based

on the assumption that cases of radiculomegaly strongly suspected of having OFCD syndrome and patients with OFCD syndrome who could not be assessed for radiculomegaly have been excluded.

It may be interesting to analyse *BCOR* and perform cardiac screening in patients with non-syndromic radiculomegaly to better understand *BCOR* spectrum diseases and allow detection of asymptomatic CHDs.

Author contributions. All authors made substantial contributions to the study. C.S. participated in the conception and design of the study, acquisition of data, analysis and interpretation of data, drafting the article; C.R. participated in the conception and design of the study, acquisition of data, analysis and interpretation of data, drafting the article, critical revision for important intellectual content, and final approval of the version to be submitted. C.C., M.J.B., G.D., C.C., F.S., and N.C., participated in the critical revision of the article for important intellectual content and final approval of the version to be submitted.

Competing interests. There is no known conflict of interest associated with this publication, and there has been no significant financial support for this work that could have influenced its outcome.

Ethical standards. This study has been performed in accordance with the ethical standards laid down in the 1964 Declaration of Helsinki and its later amendments. All patients included in the study gave their informed consent prior to their inclusion in the study. All details that might disclose the identity of the subjects have been omitted.

References

- Smith MH, Cohen DM, Bhattacharyya I, Islam NM, Kashtwari D. Radiculomegaly: a case report of this rare dental finding with review of the associated oculo-facio-cardio-dental syndrome. *Oral Surg Oral Med Oral Pathol Oral Radiol* 2018; 126: e220–e227.
- Marashi AH, Gorlin RJ. Radiculomegaly of canines and congenital cataracts—A syndrome? *Oral Surg Oral Med Oral Pathol* 1990; 70: 802–803.
- Hu Q, Mai J, Xiang Q, Zhou B, Liu S, Wang J. A novel deletion mutation in the *BCOR* gene is associated with oculo-facio-cardio-dental syndrome: a case report. *BMC Pediatr* 2022; 22: 82.
- Davoody A, Chen IP, Nanda R, Uribe F, Reichenberger EJ. Oculofaciocardiodental syndrome: a rare case and review of the literature. *Cleft Palate Craniofac J Off Publ Am Cleft Palate-Craniofacial Assoc* 2012; 49: e55–60.
- Ragge N, Isidor B, Bitoun P et al. Expanding the phenotype of the X-linked *BCOR* microphthalmia syndromes. *Hum Genet* 2019; 138: 1051–1069.
- Al-Obaida M. A rare case of nonsyndromic generalized radiculomegaly with a literature review. *Case Rep Dent* 2020; 2020: 1–7.
- Wilkie GJ, Chambers IG. A very large maxillary cuspid. *Oral Surg Oral Med Oral Pathol* 1990; 70: 159–160.
- Fujimura A, Suetsugu H, Onodera M, Nozaka K, Nozaka Y. Long root of deciduous anterior teeth. *Odontology* 2008; 96: 61–64.
- Hayward JR. Cuspid gigantism. *Oral surg oral med oral pathol.* 1980; 49: 500–501.
- Kemoli A, Munyao T. Bilateral second premolars agenesis together with a unilateral canine radiculomegaly. *Contemp Clin Dent* 2017; 8: 151.
- Alhussain M, Almosa N, Alnofaie H. Nonsyndromic Generalized Radiculomegaly of Permanent Dentition: A Rare Case Report. In: Mergoni G (eds). *Case Rep Dent*, 2022: 1–6.
- Weine FS. A very long cuspid!. *J Endod* 1986; 12: 80–81.
- Baranwal A, Gurney M, Basmaci R et al. Genetic landscape and clinical outcomes of patients with *BCOR* mutated myeloid neoplasms. *Haematologica* [Internet] 2020; 109: 1779–1791. [cited 2024 Mar 2]; Available from: <https://haematologica.org/article/view/haematol.2023.284185>
- Barresi V, Cardoni A, Miele E et al. CNS tumor with CREBBP: *BCORL1* fusion and pathogenic mutations in *BCOR* and CREBBP: expanding the spectrum of *BCOR*-altered tumors. *Acta Neuropathol Commun* 2024; 12: 8.
- Lavelle CLB. Maxillary and mandibular tooth size in different racial groups and in different occlusal categories. *Am J Orthod* 1972; 61: 29–37.
- Wasserman MA, Shea E, Cassidy C et al. Recommendations for the adult cardiac sonographer performing echocardiography to screen for critical congenital heart disease in the newborn: from the American Society of echocardiography. *J Am Soc Echocardiogr Off Publ Am Soc Echocardiogr* 2021; 34: 207–222.
- Ng D, Thakker N, Corcoran CM et al. Oculofaciocardiodental and Lenz microphthalmia syndromes result from distinct classes of mutations in *BCOR*. *Nat Genet* 2004; 36: 411–416.
- Schwaibold EMC, Brugger M, Wagner M. A C-terminal *BCOR* nonsense variant in a male patient expands the phenotypic spectrum of *BCOR*-associated syndromic microphthalmia. *Clin Genet* 2021; 100: 489–490.
- Astolfi A, Fiore M, Melchionda F, Indio V, Bertuccio SN, Pession A. *BCOR* involvement in cancer. *Epigenomics* 2018; 11: 835–855.
- Pisapia DJ, Ohara K, Bareja R et al. Fusions involving *BCOR* and CREBBP are rare events in infiltrating glioma. *Acta Neuropathol Commun* 2020; 8: 80.
- Hamline MY, Corcoran CM, Wamstad JA et al. OFCD syndrome and extraembryonic defects are revealed by conditional mutation of the polycomb-group repressive complex 1.1 (*PRC1.1*) gene *BCOR*. *Dev Biol* 2020; 468: 110–132.
- Min Soe K, Ogawa T, Moriyama K. Molecular mechanism of hyperactive tooth root formation in oculo-facio-cardio-dental syndrome. *Front Physiol* 2022; 13: 946282.
- Marashi AH, Gorlin RJ. Radiculomegaly of canine teeth and congenital cataracts: confirmation of a syndrome. *Am J Med Genet.* 1992; 42: 143–143.