

talkative; calumniators are not silent; and yet we still go back to Mackenzie's "Diseases of the Throat and Nose" for our statistics, and we use his laryngeal forceps.

Of the vexed question of Mackenzie's treatment of the Crown Prince's laryngeal disease, and of Mackenzie's outspoken criticisms of his German colleagues in that case, this is not the place to speak. Suffice it to say that it would be a little difficult nowadays to compel the resignation of any man from a British Medical College for plain speaking with regard to the practices of German surgeons!

That by the way. What we wish to observe now is that the storms that have been raging around this great man's head are at last being dissipated, and he is once more emerging into view, still worthy of our respect—still worthy, indeed, of our admiration—for, as the years roll on, Time is proving his work to have been both durable and sound.

D. M.

### SCIENTIFIC RELICS OF MORELL MACKENZIE.<sup>1</sup>

EXHIBITED AT THE FIRST SUMMER CONGRESS OF THE SECTION OF  
LARYNGOLOGY AT THE ROYAL SOCIETY OF MEDICINE ON  
MAY 2 AND 3, 1919.

PRESENTED BY MR. MAYER (MESSRS. MAYER AND PHELPS)

TO THE ROYAL SOCIETY OF MEDICINE.

MANUSCRIPTS COMPILED BY DR. IRWIN MOORE.

Diagrams prepared by Dr. James Donelan to illustrate a lecture given by Morell Mackenzie before the Philosophical Institute of Edinburgh in December, 1888, on "Speech and Song." One of these diagrams comprises the history of "Pitch," as illustrated by the variations and vibrations of the note A from the time of Mozart.

A comparative scale of different classes of voices, with notes by Morell Mackenzie. This chart was kept in his drawer to refresh his memory when he saw singers. Inscribed in Morell Mackenzie's handwriting (blue pencil): "Not to be taken from the drawer."

Reprints of articles, by Solis-Cohen, from the *American Journal of Medical Sciences*, 1883, pp. 84-93, on "Laryngoscopy as a Means of Diagnosis." Presented to Morell Mackenzie, with the compliments of the author. Marked "Important" in Morell Mackenzie's handwriting.

Twelve water-colour drawings by Lennox Browne, signed and dated (see below).

Morell Mackenzie's interest in the pathology of his speciality is shown by the large number of cases he exhibited at the meetings of the Pathological Society of London between 1862 and 1874 (*vide Transactions*, vols. xiii to xxv).

These cases were invariably worked out with great thoroughness both as regards history and symptoms, and constitute a valuable addition to literature.

The beautiful water-colour drawings by Lennox Browne, presented to the Royal Society by Mr. Mayer, represent the most interesting and important cases which Morell Mackenzie contributed to the Pathological Society of London during this period.

<sup>1</sup> These relics have been placed in a case, and are exhibited in the Library of the Royal Society of Medicine, 1, Wimpole Street, London, W.

1. *Cancerous Ulceration of the Epiglottis, with large Cystic Tumour of the Neck* (shown January 21, 1868). *Trans. Path. Soc. Lond.*, 1868, vol. xix, p. 61.

2. *Cancerous Ulceration of the Larynx* (shown May 5, 1868). *Trans. Path. Soc. Lond.*, 1868, vol. xix, p. 71.

3. *Ulcer of the Œsophagus perforating the Trachea and believed to be Non-cancerous* (shown February 18, 1868). *Trans. Path. Soc. Lond.*, 1868, vol. xix, p. 213.

4. *Cancerous (?) Ulceration of the Larynx, with Partial Obliteration of the Œsophagus* (shown May 5, 1868). *Trans. Path. Soc. Lond.*, 1868, vol. xix, p. 83.

5. *Tracheal Growths Pressing upon the Left Recurrent Laryngeal Nerve, and causing Paralysis and Atrophy of the Abductor of the Left Vocal Cord* (shown May 19, 1868). *Trans. Path. Soc. Lond.*, 1868, vol. xix, p. 84.—[In the title (*Trans. Path. Soc.*), the growths were described as laryngeal. This is evidently a printer's error, since in the letterpress the trachea is referred to as the seat of the growths].

This drawing appears in the present number of the JOURNAL, and the following is the report of the case:<sup>1</sup>

The specimen was taken from a female, aged fifty-six, first seen on March 29, 1868, and was exhibited at a Meeting of the Pathological Society of London on May 19, 1868.

Patient complained of extensive dyspnoea and stridulous breathing on the slightest exertion, which had followed a violent croupy cough three years previously. The dyspnoea and stridor ceased when the patient assumed the recumbent posture, and also on going downstairs. During sleep there was not the slightest stridor.

*Laryngoscopic examination* showed that the left vocal cord was not properly abducted on inspiration, but remained near the median line, presenting a curved free border (*vide fig.* in centre of plate).

No aneurysmal tumour, which might have pressed on the recurrent laryngeal nerve of the side effected, could be discovered.

Since the dyspnoea was very considerable, tracheotomy was performed on April 17, but the patient did not appear to be much relieved by it. Four days later a sudden and most severe paroxysm of dyspnoea came on, patient becoming perfectly livid and slightly convulsed. The paroxysm lasted several hours and was followed by another after an interval of three hours. The attack was considered to be due to asthma.

A week later patient had a recurrence of the asthma, and died the following day at the termination of a severe paroxysm.

*Post-mortem examination* revealed a number of small tumours, growing outside, and projecting into the cavity of the wind-pipe, midway between the larynx and the bifurcation of the trachea. In one of these, three-quarters of an inch long by a quarter of an inch in breadth, the left recurrent nerve was completely embedded, and as it emerged it was seen to be red and inflamed. The left abductor (crico-arytænoideus posticus) was found to be pale and atrophied. On microscopical examination its fibres were seen to have undergone complete fatty degeneration. No other muscle was unhealthy. The walls of the heart were exceedingly soft and thin, the right auricle so much so that it was accidentally ruptured in removal.

There were altogether four distinct tumours.

Microscopical report of the one in which the nerve was embedded:

"The hard tumour seems to consist of a striped muscular tissue, enveloped in connective-tissue and cells. The muscular fibres are disposed irregularly and vary greatly in size and shape; some at the edge of the preparation are well marked, those placed internally are much more narrow, and so indistinct that it is difficult to recognize their real nature." On the right side, external to the trachea, was a small cystic tumour, made up of epithelial cells, enclosed in enlarged gland-

<sup>1</sup> The notes of this case have been summarised by Dr. Irwin Moore from Morell Mackenzie's original description published in the *Transactions of the Pathological Society of London*, 1868, vol. xix, p. 84.

tubes of various shapes and sizes, the cells presenting no appearance of malignant disease, and the basement membrane being distinct, and in many parts thickened. The tumour did not in any way involve the right recurrent nerve. The fluid contained in it was of a sebaceous character. In addition to these there were two small round growths projecting into the tracheal canal, of a similar nature to the last, but probably older, the glands being less distinctly marked, and more fused together.

Report on specimen of laryngeal growths pressing upon the left recurrent laryngeal nerve, by the Committee on Morbid Growths: "We have examined the tracheal tumour, and beg to report that we agree generally in the description of its microscopical structure; that we found striped muscular fibre in the outer portion of its left lateral division; but that we found none in the interior of the tumour or on the inner surface of any part of it. We believe that the muscular fibres were derived from the muscle in contact with, and partly involved in the outer surface of the growth."

6. *Primary Caries of the Cricoid Cartilage, with Secondary Abscess* (shown March 1, 1870). *Trans. Path. Soc. Lond.*, 1870, vol. xxi, p. 46.

7. *Large Tumour removed from the Posterior Surface of the Cricoid Cartilage* (shown April 5, 1870). *Trans. Path. Soc. Lond.*, 1870, vol. xxi, p. 53.

8. *Aneurysm of the Arch of the Aorta causing Pressure on the Left Recurrent Laryngeal Nerve, with Paralysis and Atrophy of the Muscles of the Left Side of the Larynx* (shown April 19, 1870). *Trans. Path. Soc. Lond.*, 1870, vol. xxi, p. 129.

9. *Constriction of the Trachea, Syphilitic Deposits in the Liver* (shown February 21, 1871). *Trans. Path. Soc. Lond.*, vol. xxii, p. 38.

10. *Varicose Larynx* (John Riley, aged twenty-five), pl. viii, p. 188.—The appearance of the larynx is typical of early tuberculosis, *e.g.* the pallor or anæmia of the epiglottis and arytaenoid, loss of lustre, and passive congestion of the left cord.

11. *Tubercular Ulceration of the Right Vocal Cord*.—Case of Benjamin White (No. 1, pl. v).

12. *Tubercular Ulceration of the Posterior Half of the Left Vocal Cord with Papillary Infiltration of the Interarytaenoid Region*.—Case of George Tomkins (No. 2, pl. v).

The cases from which these three views of the larynx were taken have not been recorded in the *Transactions of the Pathological Society* or any other publication, and are presumably cases from Morell Mackenzie's private practice.

13. *Syphilitic Leucoplakia*.—From a male patient, pl. vi, p. 139. P.Bk. (evidently stands for private book), is presumably another case from Morell Mackenzie's private practice.

It is hoped to reproduce these drawings in this JOURNAL at a later date, along with reports of the cases.

One of the tracheotomy tubes made by Messrs. Mayer and Meltzer for the Crown Prince of Germany in February, 1888.

Original telegram mounted between glass from Morell Mackenzie to Messrs. Mayer and Meltzer, ordering a very large-sized Durham's tracheotomy tube for the Crown Prince of Germany. Dated San Remo, February 8, 1888.

Manuscript.—The case of the German Crown Prince, and its treatment by Sir Morell Mackenzie. By Dr. Wilhelm Meyer and Dr. Holger Meigend. Dated November 20, 1887. This was written in reply to the attacks in the German Press on Morell Mackenzie.

Manuscript of portion of "Manual of Diseases of the Throat and Nose." Index of "The Trachea," pp. 581-601 of vol. ii. Page 55 missing. In Morell Mackenzie's own handwriting.

Manuscripts dictated by Morell Mackenzie and in the handwriting of his

secretary, Mr. Nainby, probably intended for the second edition of the "Manual":—

1. Nasal Catarrh.
2. Purulent Nasal Catarrh.
3. Chronic Rhinitis and Ozæna.
4. Syphilitic Affections of the Nasal Cavities.
5. Lupus of the Pituitary Membrane.
6. Glanders.
7. Foreign Bodies in the Nasal Cavity.
8. Nasal Calculi (Rhinoliths).
9. Nasal Neuroses (Anæmia, etc.).
10. Glandular Diseases of the Naso-Pharyngeal Mucous Membrane.
11. Fractures of the Larynx.

It is hoped to publish these articles at a later date in this JOURNAL.

A portion of the manuscript of a lecture on "Goitre" (two pages missing), delivered at the London Hospital. No date.

Galley proof of chapters on "Goitre," with pencil notes by Dr. James Donelan. Pages 7 to 35 (pages 1 to 6 missing, dealing with the history of goitre). These were to have been published as part of the section of "Diseases of the Neck," vol. iii. Referred to by Dr. James Donelan<sup>1</sup> in his Presidential Address to the Section of Laryngology, Royal Society of Medicine, Session 1918-19. Also in his article on "Morell Mackenzie, the Father of British Laryngology," in the JOURNAL OF LARYNGOLOGY, RHINOLOGY AND OTOTOLOGY.<sup>2</sup>

Manuscript book, McClland on "Goitre." These are notes from the *British and Foreign Medical Review*, 1839, vol. viii, pp. 103 *et seq.*

Manuscript book containing 26 letters from various medical men, written in reply to inquiries sent by Morell Mackenzie as to the question of the endemiology of goitre.

Manuscripts (various) relating to the trachea and œsophagus, in loose brown paper cover, inscribed "Holmes" in brackets. These were dictated by Morell Mackenzie to his assistant, Dr. Gordon Holmes.

Manuscripts, "Malformation of the Œsophagus," inscribed "50 pounder." These are written notes on congenital malformations of the œsophagus, trachea and larynx, arranged in chronological order from 1813 to 1880.

"Clinical History of a Case of Labio-glosso-laryngeal Paralysis," in Mackenzie's own handwriting. These notes are remarkable for the minute details of the symptoms observed.

Book of "Form Letters" for use of Secretary.

Rough notes of cases. Dr. Donelan says Mackenzie made these when called to visit patients.

"Description of Triangular Bandage," by Acting Surgeon R. R. Sleeman, 20th Middlesex (Artists'), R.V. Dated November 6, 1890, and addressed, "Surgeon Sir M. Mackenzie." Morell Mackenzie was at this time in the Volunteers. This was the date of the original introduction of the triangular bandage.

Six photographs of Larynx, inscribed, "To Sir Morell Mackenzie with compliments of T. R. French, M.D., Brooklyn, Jan. 11th, 1890."

Three photographs of Goitre cases, with notes attached.

Book of photographs of cases in which tracheotomy had been performed for croup and papilloma of the larynx and one case of extirpation of the larynx. Presented to Sir Morell Mackenzie by E. S. Cassanello de Montevideo.

A bound volume of pamphlets entitled "Rhinoscopy," by various authors, some with notes affixed in Morell Mackenzie's handwriting. Also one inscribed with his signature.

"The Use of the Laryngoscope in the Diseases of the Throat," with the appendix on "Rhinoscopy," by Morell Mackenzie. Second edition, 1866, inscribed, "Mr. Mayer, with the Author's compliments," in Morell Mackenzie's handwriting.

Two empty drawing or manuscript portfolios.

Ten original electrodes which were used to illustrate various instruments in the "Manual of Diseases of the Throat and Nose."

<sup>1</sup> "British Laryngology and Rhinology," *Proc. Roy. Soc. Med.*, 1918, vol. xii (Sect. Laryngol.), p. 4.

<sup>2</sup> *JOURN. OF LARYNGOL., RHINOL., AND OTOL.*, 1919, vol. xxxiv, p. 183.

LARYNGEAL AND NASAL INSTRUMENTS FORMERLY IN THE POSSESSION OF,  
OR DESIGNED BY MORELL MACKENZIE.

Amongst these instruments<sup>1</sup> the following deserve special notice :

*Œsophagoscope* (fig. 3, vol. ii, p. 16).—Morell Mackenzie was one of the earliest pioneers of œsophagoscopy, and was the first to actually look into the œsophagus by the direct method.

Following *the first attempts* to examine the œsophagus by Semeleder and Stoeck in 1866 and Waldenburg in 1868, Mackenzie made his first attempt in November, 1880, by means of an instrument which he himself invented.

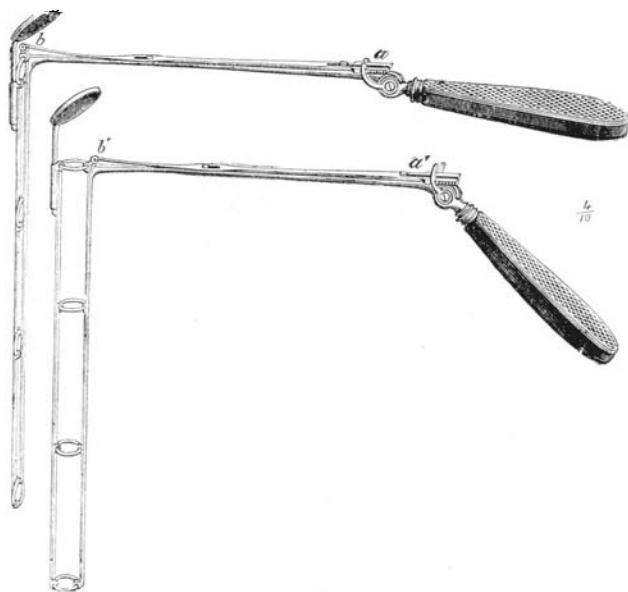


FIG. 1.—Morell Mackenzie's œsophagoscope.

This instrument was altogether different from any previously employed, and consisted of a skeleton tube or speculum made up of rings which could be closed for easy insertion into the œsophagus and opened when in position. In the upper portion of this tube a laryngeal mirror was attached. There are three different length stems, consisting of four, three and two rings respectively, which can be attached to the handle. Mackenzie<sup>2</sup> tells us that during the ten months following his first trial he used this œsophagoscope on fifty patients, and succeeded in thirty-seven cases in inspecting the upper part of the œsophagus. Subsequently he employed it whenever a suitable case presented itself.

During later years the advent of electric light gave fresh impetus to other workers in this field, resulting in the natural evolution of the present-day endoscopic tube from the urethroscope of Desormeaux and Cruise.

<sup>1</sup> The figures (in brackets) after each instrument refers to the "Manual of Diseases of the Throat and Nose."

<sup>2</sup> "Manual of Diseases of Throat and Nose," 1884, vol. ii, p. 16.

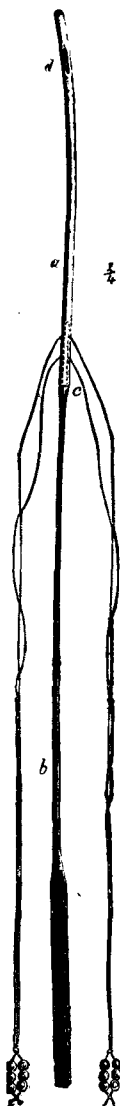


FIG. 2.—  
Mackenzie's  
permanent  
oesophageal  
feeding-  
tube.

*Oesophageal Electrode.*—This instrument is similar to the laryngeal electrode designed by Mackenzie, but is 26 cm. in length below the handle.

*Mackenzie's Permanent Oesophageal Tube.*—This consisted of a fine gum-elastic tube about 6 in. in length to which two strings were attached. It was inserted by means of a vulcanite or whalebone stem.

Mackenzie used this feeding-tube with great success in many cases of oesophageal stricture. It seems, indeed, to have been the first oesophageal feeding-tube ever devised.

*Mackenzie's Double Guillotine or Tonsillotome* (fig. 6, vol. i, p. 12).—This instrument was designed by Mackenzie, and consisted of a pair of his tonsil guillotines attached together for the simultaneous excision of both tonsils, but he only occasionally used the instrument and it soon became obsolete.

*Mackenzie's Nasal Ecraseur* (fig. 59, vol. ii, p. 272).—This was designed for the removal of the more fibrous varieties of polypi, and is still employed by some operators. The wire is wound round a cogwheeled reel worked by a lever. It is cleverly designed and a very useful instrument.

*Mackenzie's Nasal Polypus Snare* (fig. 57, vol. ii, p. 270).

*Mackenzie's Nasal Bone Forceps* (fig. 55, vol. ii, p. 268).—This instrument combined the grasping power of ordinary forceps with a cutting blade, and was used for the removal of portions of the turbinal bones and nasal exostoses. When the instrument was in position, a sliding chisel fixed to the forceps was projected forward. The instrument is now obsolete.

*Nasal Punch Forceps for Polypi* (fig. 51, vol. ii, p. 266).—These were used for seizing and evulsion or cutting through a growth.

*Nasal Ring Knife for Bony Spurs.*

*Four Nasal Bougies* (vol. ii, p. 254).—These were made of gum-elastic, from 3 to 4 in. in length.

*Laryngeal Reflector Mounted on Spectacle Frame* (fig. 13, vol. i, p. 218).

*Mackenzie's Laryngeal Electrode* (fig. 40, vol. i, p. 252).

—For the direct application of electricity to the vocal cord. Mackenzie occasionally employed this.

*Mackenzie's Guarded Wheel Ecraseur* (fig. 49, vol. i, p. 260).—This was employed for the removal of very large growths of the larynx, and consisted of a solid metal loop in which was concealed a snare wire worked by a cog-wheel attached to the handle. It was a serviceable instrument, for the wire could easily be made to surround the growth. (See Fig 3.)

*Mackenzie's Laryngeal Tube Forceps* (fig. 46, vol. i, p. 257).—These forceps were made with various shaped blades, both perpendicular and horizontal. The blades are the original patterns of those now in use in the direct forceps, *i. e.* the bean forceps, the needle forceps, and the punch forceps of Killian, Brunings, etc.

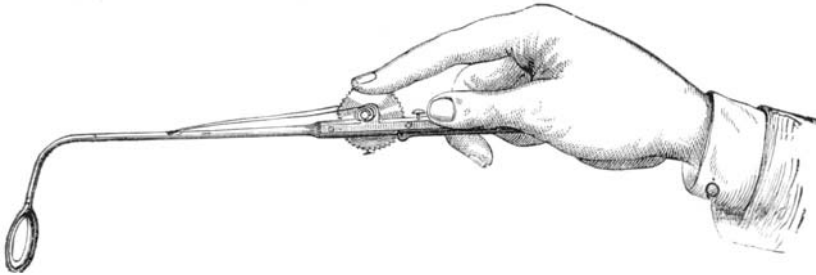


FIG. 3.—Mackenzie's guarded wheel ecraseur.

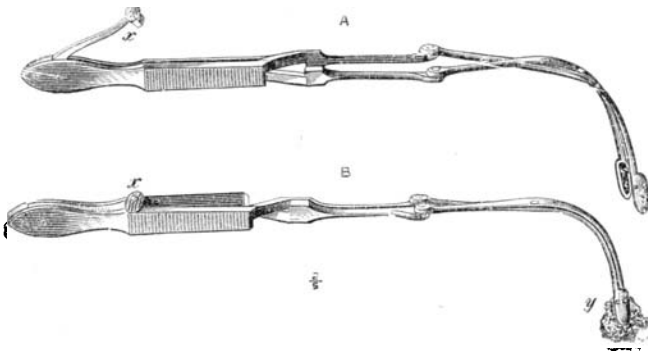


FIG. 4.—Mackenzie's laryngeal sponge holder with safety catch.

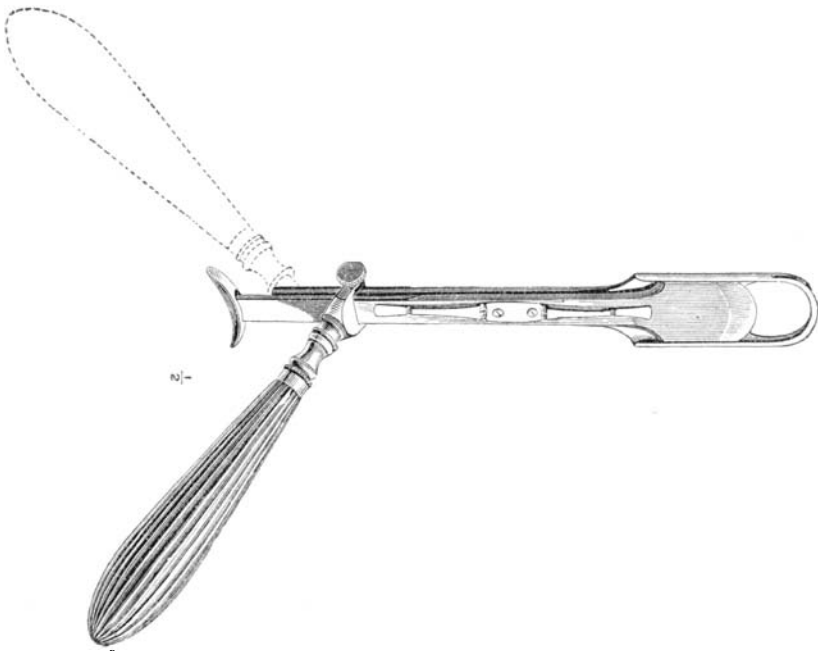


FIG. 5.—Mackenzie's reversible tonsil guillotine.

*Mackenzie's Laryngeal Sponge Holder with Safety Catch* (fig. 29, vol. i, p. 245).—For applying solutions to the larynx, with a safety arrangement for fixing the blades immovably together.

*Mackenzie's Laryngeal Cutting Forceps* (fig. 43, vol. i, p. 254).—This is an early pattern of the laryngeal forceps designed by Mackenzie, which is universally used throughout the world at the present day for the removal of benign growths from the larynx by the indirect method. He designed a later pattern, larger and heavier, so as to obtain a better balance.

*Croup Brush or Sponge Holder*.—Morell Mackenzie used to tie a small sponge or squirrel's tail on to this holder in order to remove the membrane in croup.

The following instruments, formerly in the possession of Morell Mackenzie, have been presented to the Royal Society of Medicine by Dr. Dan McKenzie to be included amongst the "Mackenzie relics." These instruments after Mackenzie's death came into the possession of the late Mr. Cresswell Baber, and were presented by Mrs. Baber to Dr. Dan McKenzie.

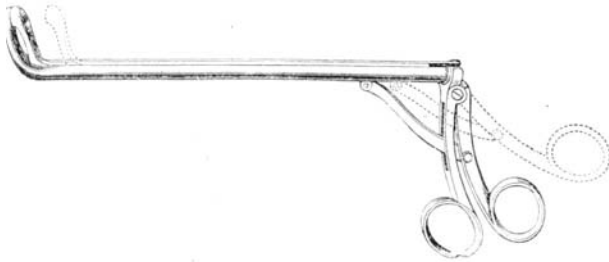


FIG 6.—Mackenzie's sliding post-nasal forceps.

*Mackenzie's Sliding Post-nasal Forceps* (fig. 63, vol. ii, p. 275).

*Mackenzie's Reversible Tonsil Guillotine*, engraved with Mackenzie's name (fig. 4, vol. i, p. 11).

*Uvula Forceps*.

*Frankel's Palate Hook* (fig. 32, vol. ii, p. 248).

*Elsberg's Uvulotome* (reference to this instrument in vol. i, p. 14).

*Mackenzie's Guarded Wheel Ecraseur*, similar to that previously referred to (Fig. 3) and designed by Morell Mackenzie. It was made for large naso-pharyngeal growths.

---

## SPASM AT THE ENTRANCE TO THE OESOPHAGUS.<sup>1</sup>

BY A. BROWN KELLY, M.D.

THERE is a variety of dysphagia, not uncommon in middle-aged women, which in all cases presents almost identical signs and symptoms and which reacts uniformly to treatment, but as to the pathology of which we are ignorant. In order to obtain information as to the local condition

<sup>1</sup> Paper read at the Summer Congress of the Laryngological Section of the Royal Society of Medicine, May 2, 1919.