

# Intravenous iron infusion ameliorates anaemia and protein-losing enteropathy in patients after Fontan surgery: case series

## Brief Report

**Cite this article:** Kairiku M and Aoki H (2024) Intravenous iron infusion ameliorates anaemia and protein-losing enteropathy in patients after Fontan surgery: case series. *Cardiology in the Young* **34**: 1355–1358. doi: [10.1017/S1047951124000672](https://doi.org/10.1017/S1047951124000672)

Received: 18 November 2023  
Revised: 13 January 2024  
Accepted: 12 February 2024  
First published online: 12 April 2024

### Keywords:

intravenous iron infusion; Fontan; protein-losing enteropathy; anaemia; iron deficiency

### Corresponding author:

H. Aoki; Email: [aokihisaaki@hotmail.com](mailto:aokihisaaki@hotmail.com)

Mio Kairiku  and Hisaaki Aoki 

Department of Pediatric Cardiology, Osaka Women's and Children's Hospital, Izumi, Osaka, Japan

### Abstract

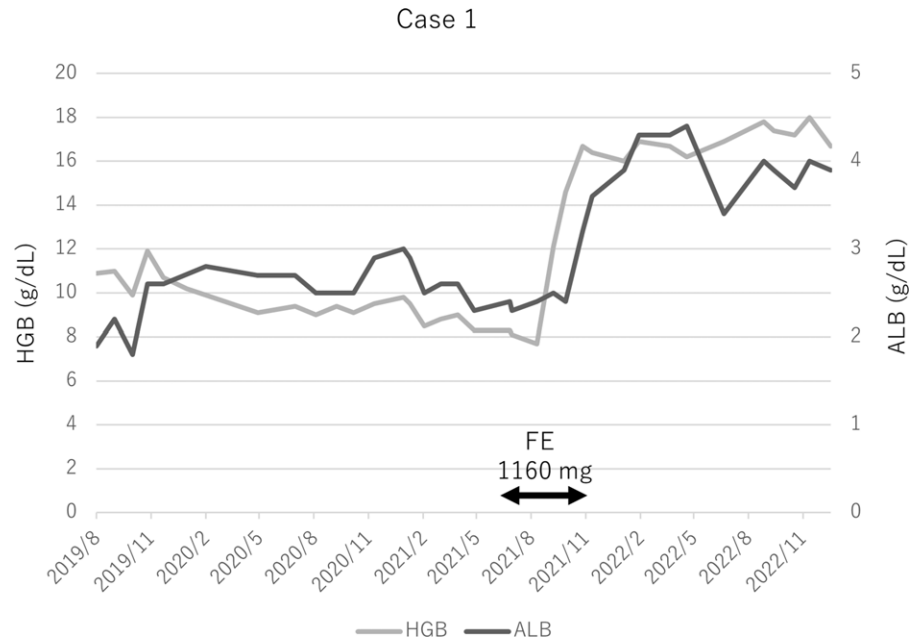
Protein-losing enteropathy is a severe complication of Fontan surgery and is associated with anaemia. Few studies have reported on the efficacy of an intravenous iron infusion for treating protein-losing enteropathy and low albuminemia after Fontan surgery. Herein, we present two cases of female patients who suffered from protein-losing enteropathy and low albuminemia following Fontan surgery, both of whom improved after an intravenous iron infusion.

Iron is crucial to biological functions, including respiration, energy production, DNA synthesis, and cell proliferation.<sup>1</sup> Anaemia and iron deficiency worsen therapeutic outcomes<sup>2</sup> and intravenous infusion of iron improves clinical outcomes, including functional capacity, risk of hospitalisation, and quality of life in adult patients with heart failure with reduced ejection fraction.<sup>3</sup> Protein-losing enteropathy is one of the most severe pathological manifestations of the Fontan circulation. Fontan-associated protein-losing enteropathy results from excessive leakage of protein from the gastrointestinal system. The causes are not well understood but likely include a combination of lymphatic insufficiency, high central venous pressure, loss of heparan sulphate from intestinal epithelial cells, abnormal mesenteric circulation, and intestinal inflammation.<sup>4</sup> Typically, patients are treated with diuretics or steroids. Iron deficiency anaemia is sometimes present in patients with protein-losing enteropathy due to malabsorption or haemorrhage. Yetman reported that intravenous iron leads to a significant improvement in the albumin and protein levels and is associated with the resolution of heart failure and gastrointestinal symptoms in patients with chronic protein-losing enteropathy after a Fontan operation.<sup>5</sup> Although iron supplementation is recommended in the presence of iron deficiency in cyanotic patients,<sup>6</sup> there have been no other papers on the efficacy of an intravenous iron infusion for treating protein-losing enteropathy after Fontan surgery. Herein, we present two cases of protein-losing enteropathy and a low albuminemia that improved after an intravenous iron infusion following a Fontan surgery.

## Case presentation

### Case 1

Case 1 was a 28-year-old woman with iron deficiency anaemia, Ebstein's anomaly with a Starnes operation and Fontan surgery, sinus node dysfunction, atrioventricular block with a pacemaker implantation, and protein-losing enteropathy. She had undergone Fontan surgery at the age of 5 years and experienced protein-losing enteropathy at the age of 10 years. The albumin level was 1.5–2.0 g/dL and the haemoglobin level was around 9.0 g/dL. She had suffered repeated episodes of diarrhoea, ascites, and leg oedema, and was treated with various protein-losing enteropathy therapies. She had been on hormone replacement therapy for amenorrhoea, but that was stopped when she developed a venous thrombosis at the age of 22 years, at which point warfarin was started. Aspirin, roxatidine, warfarin, furosemide (80 mg/day), spironolactone (50 mg/day), trichlormethiazide (1 mg/day), tolvaptan (7.5 mg/day), Ca (2400 mg/day), and alfacalcidol (0.25 µg/day) were prescribed. She had protein-losing enteropathy, a low nutritional status, and iron-deficiency anaemia. She had amenorrhoea but no urinary occult blood or gastrointestinal bleeding. However, she did not tolerate oral iron preparations. She had a body weight of 31.5 kg, blood pressure of 88/47 mmHg, pulse rate of 89 bpm, saturated oxygenation of 95%, and body mass index of 14.7. The patient's laboratory results are shown in Supplemental Table 1. Catheterisation revealed a normal left ventricular end-diastolic volume of 71% of normal, left ventricular ejection fraction of 56%, left ventricular 114/end-diastolic pressure of 15 mmHg, right pulmonary artery of 17 mmHg, left pulmonary artery of 11 mmHg, inferior vena cava pressure of 13 mmHg, and cardiac index of 3.4 L/min/m<sup>2</sup> using the Fick method. The pacemaker settings were the DDD mode, 70 ppm, and both atrial and ventricular pacing. The chest X-ray showed a cardio-thoracic ratio of 51%.



**Figure 1.** Progress in case 1. The figure shows the progression of the haemoglobin (HGB) and albumin (ALB). The ALB level increased following an increase in the HGB 4 months after the iron injection. The ALB and HGB levels were maintained 1.5 years after the iron injection.

#### Progress (Fig. 1 and Supplemental Table 1)

The patient received intravenous iron infusion (160 mg/week). The intravenous iron infusion was administered for 4 months (total dose: 1160 mg). The albumin level increased following an increase in the haemoglobin level 4 months after the iron injection. She sometimes has mild watery diarrhoea but no leg oedema or ascites. The albumin and haemoglobin levels were still maintained 1.5 years after the iron infusion.

#### Case 2

Case 2 was a 20-year-old woman with iron deficiency anaemia, double outlet right ventricle with a non-committed ventricular septal defect with a Fontan operation, sick sinus syndrome with a pacemaker implantation, and hypothyroidism. She underwent Fontan surgery with a fenestration at the age of 4 years, followed by a Damus–Kaya–Stansel anastomosis surgery at the age of 6 years, and had protein-losing enteropathy at the age of 7 years. She occasionally experienced atrial tachycardias. She had repeated episodes of diarrhoea, ascites, and leg oedema and had been treated with various protein-losing enteropathy therapies, including steroids, from 14 years of age. The albumin level was 1.5–2.5 g/dL and haemoglobin around 7–10 g/dL. When she had severe oedema or fluid retention, albumin and a red cell transfusion were administered. Although she had iron deficiency anaemia, oral iron preparations were not tolerated owing to nausea. The patient did not experience excessive menstruation, occult urinary blood, or gastrointestinal bleeding. The patient received aspirin (100 mg/day), esomeprazole magnesium hydrate (20 mg/day), warfarin (2.0 mg/day), furosemide (40 mg/day), spironolactone (50 mg/day), sotalol hydrochloride (160 mg/day), ambrisentan (5 mg/day), prednisolone (7.5 mg/day), levothyroxine sodium (50 µg/day), and chlormadinone acetate (4 mg/day). She had a weight of 46.9 kg, blood pressure of 96/47 mmHg, pulse rate of 71 bpm, saturated oxygenation of 89 %, and body mass index of 20.3. The patient's laboratory results are shown in Supplemental Table 2. Catheterisation revealed an left ventricular ejection fraction of 46%, left ventricular of 88/end-diastolic pressure of 10, saturated oxygenation of the aorta of 79.5%, left pulmonary artery of 18 mmHg, and cardiac index of

3.5 L/min/m<sup>2</sup> using the Fick method. The pacemaker settings were the AAIR mode and 70 ppm. The chest X-ray revealed a cardio-thoracic ratio of 42%.

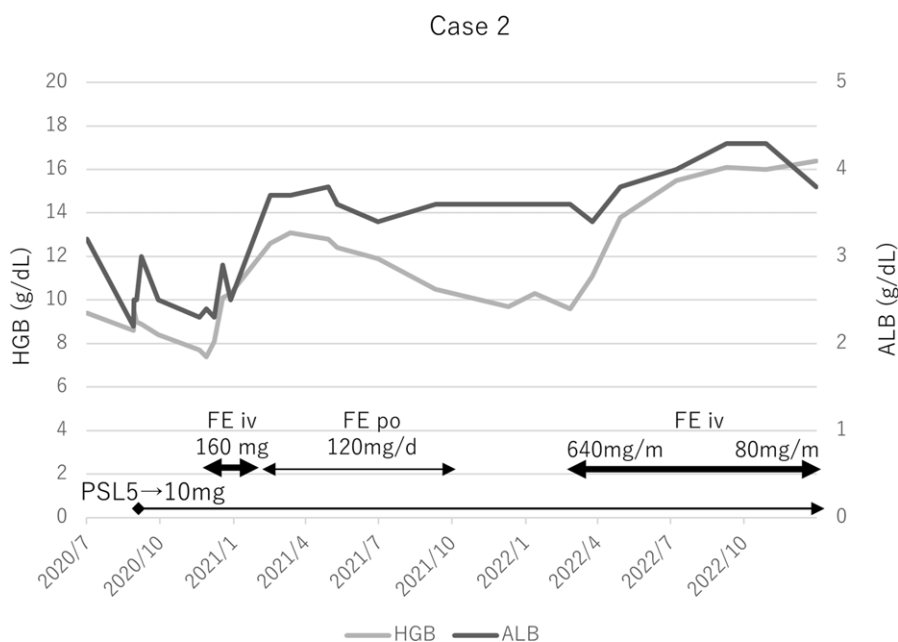
#### Progress (Fig. 2 and Supplemental Table 2)

The protein-losing enteropathy recurred 5 months after the discontinuation of prednisolone. The protein-losing enteropathy was not in remission 3 months after the prednisolone administration at a dose of 5 mg/day. The prednisolone was increased to a dose of 10 mg/day and 160 mg/week after the intravenous iron infusion was started. Approximately 1 month later, her haemoglobin and albumin levels, as well as protein-losing enteropathy symptoms, ameliorated. However, the haemoglobin level decreased and the albumin value remained low 15 months after the administration of prednisolone (10 mg/day) and intravenous iron infusion. Oral iron preparations were not tolerated; consequently, the intravenous iron infusion was reinitiated. The haemoglobin and albumin levels improved approximately 4 months later. The intravenous iron infusion was continued once a month, the haemoglobin and albumin levels were maintained, and she had no leg oedema or ascites.

#### Discussion

Intravenous iron infusion ameliorated the anaemia and chronic protein-losing enteropathy in both patients with documented iron deficiency following Fontan surgery. Both patients had chronic failure of Fontan circulation with an elevated pulmonary artery pressure, left ventricular end-diastolic pressure, and recurrent protein-losing enteropathy symptoms, such as oedema, diarrhoea, and ascites, despite the administration of multiple diuretics.

Anaemia is defined as a haemoglobin concentration of < 13.0 g/dL in men and < 12.0 g/dL in women, and iron deficiency as a ferritin concentration of < 100 mg/L or a combination of ferritin concentrations ranging from 100–299 mg/L together with a transferrin saturation level of < 20%.<sup>7</sup> However, diagnosing iron deficiency in patients with cyanotic CHD can be challenging because conventional parameters of the iron status, such as the haemoglobin,



**Figure 2.** Progress in case 2. Oral prednisolone (5 mg/day) was discontinued in April 2020 because the protein-losing enteropathy (PLE) was stable and osteoporosis was observed. However, PLE recurred 5 months after the discontinuation. Although prednisolone was restarted at a dose of 5 mg/day, the PLE was not in remission 3 months after the administration of prednisolone. The prednisolone was increased to a dose of 10 mg/day and 160 mg/week from when the intravenous saccharated ferric oxide was started. Approximately 1 month later, the HGB and ALB levels and PLE symptoms ameliorated. However, the HGB level decreased and ALB value remained low 15 months after the prednisolone (10 mg/day) and iron infusion. An oral iron preparation was not tolerated; therefore, the intravenous saccharated iron oxide was restarted. Approximately 4 months later, the HGB and ALB levels improved. Monthly infusion of saccharated iron oxide continued and HGB and ALB maintained.

haematocrit, and red blood cell count, may be elevated due to secondary erythrocytosis.<sup>8</sup> Broberg et al. sought to define the relationship between haemoglobin and the oxygen saturation as the predicted haemoglobin = 61 - (oxygen saturation/2).<sup>9</sup> However, some of those parameters may also be affected by inflammation, infection, or liver dysfunction, all of which are common in patients with cyanotic CHD.<sup>10</sup>

Half of the patients after a Fontan operation have iron deficiency anaemia<sup>11</sup> and it is associated with protein-losing enteropathy-induced malnutrition, malabsorption of iron, and chronic inflammation. Taking aspirin, warfarin, and direct oral anticoagulants should be considered as a potential bleeding cause in the gastrointestinal tract, genito urinary tract, and elsewhere. Patients with cyanosis occasionally experience hyperviscosity and thromboembolic events. Therefore, iron supplementation should be administered slowly, especially when oral anticoagulants are not being taken. The iron dosage and administration method were decided based on the body weight and haemoglobin level in reference to the drug information. In the chronic phase, the dose and its interval are adjusted by monitoring the haematocrit, ferritin level, and transferrin saturation.<sup>1</sup>

Protein-losing enteropathy is a rare but serious complication of a Fontan circulation, the treatment of which is challenging and often requires a multidisciplinary approach. Its process is thought to be multifactorial and physiologic alterations including an elevated pressure on the basal aspect of the intestinal epithelial cells, loss of heparan sulphate from intestinal epithelial cells, and increase in the pro-inflammatory cytokines tumour necrosis factor alpha and interferon-gamma. Yetman reported that intravenous iron led to a significance improvement in the albumin and protein levels and an associated resolution of heart failure and gastrointestinal symptoms in patients with chronic protein-losing enteropathy after a Fontan operation.<sup>5</sup> Although the precise mechanism by which iron supplementation improves protein-losing enteropathy is not yet fully understood, it has been suggested that iron infusion could promote protein synthesis, improve various organ functions by increasing iron levels and oxygen supply, and improve the impaired epithelial tight junction of the gastrointestinal mucosa caused by severe anaemia.<sup>12</sup> Additionally,

iron therapy has been reported to have profound effects on immune function by inhibiting the production of tumour necrosis factor-alpha, leading to an improvement in protein-losing enteropathy.<sup>13</sup>

These cases suggested that iron deficiency anaemia may play a role in the pathogenesis of protein-losing enteropathy, with intravenous iron infusion suggested as a treatment option for some patients with protein-losing enteropathy. Iron supplementation during protein-losing enteropathy should be administered intravenously, with ferritin and transferrin saturation monitored due to the risk of iron overload and polycythaemia vera. Accumulation of cases and multicenter studies are needed to confirm the efficacy and safety of intravenous iron infusion for protein-losing enteropathy and to elucidate the underlying mechanisms of the action.

**Supplementary material.** The supplementary material for this article can be found at <https://doi.org/10.1017/S1047951124000672>.

**Author contribution.** M.K. and H.A. wrote the main manuscript text. M.K. and H.A. prepared the figures. All the authors critically reviewed the manuscript.

**Financial support.** None.

**Competing interests.** None.

**Consent.** The authors have obtained informed consent forms from the patients.

## References

1. Camaschella C. Iron-deficiency anemia. *N Engl J Med* 2015; 372: 1832–1843.
2. Anand IS, Gupta P. Anemia and iron deficiency in heart failure: current concepts and emerging therapies. *Circulation* 2018; 138: 80–98.
3. Sindone A, Doehner W, Comin-Colet J. Systematic review and meta-analysis of intravenous iron-carbohydrate complexes in HFrEF patients with iron deficiency. *ESC Heart Fail* 2023; 10: 44–56.
4. Alsaied T, Lubert AM, Goldberg DJ, et al. Protein losing enteropathy after the Fontan operation. *Int J Cardiol Congenit Heart Dis* 2022; 7: 100338.
5. Yetman AT, Everitt MD. The role of iron deficiency in protein-losing enteropathy following the Fontan procedure. *Congenit Heart Dis* 2011; 6: 370–373.

6. Baumgartner H, De Backer J, Babu-Narayan SV, Budts W, Chessa M, Diller GP, Group ESCSD. 2020 ESC guidelines for the management of adult congenital heart disease. *Eur Heart J* 2021; 42: 563–645.
7. Ponikowski P, Voors AA, Anker SD, et al. 2016 ESC guidelines for the diagnosis and treatment of acute and chronic heart failure: the task force for the diagnosis and treatment of acute and chronic heart failure of the European society of cardiology (ESC). Developed with the special contribution of the heart failure association (HFA) of the ESC. *Eur J Heart Fail* 2016; 18: 891–975.
8. Onur CB, Sipahi T, Tavitl Bül, Karademir S, Yoney A. Diagnosing iron deficiency in cyanotic heart disease. *Indian J Pediatr* 2003; 70: 29–31.
9. Broberg CS, Jayaweera AR, Diller GP, et al. Seeking optimal relation between oxygen saturation and hemoglobin concentration in adults with cyanosis from congenital heart disease. *Am J Cardiol* 2011; 107: 595–599.
10. Griesman JD, Karahalios DS, Prendergast CJ. Hematologic changes in cyanotic congenital heart disease: a review. *Prog Pediatr Cardiol* 2020; 56: 101193.
11. Collins N, Piran S, Harrison J, Azevedo E, Oechslin E, Silversides CK. Prevalence and determinants of anemia in adults with complex congenital heart disease and ventricular dysfunction (subaortic right ventricle and single ventricle physiology). *Am J Cardiol* 2008; 102: 625–628.
12. MohanKumar K, Namachivayam K, Sivakumar N, et al. Severe neonatal anemia increases intestinal permeability by disrupting epithelial adherens junctions. *Am J Physiol Gastrointest Liver Physiol* 2020; 318: G705–G716.
13. Weiss G, Meusburger E, Radacher G, Garimorth K, Neyer U, Mayer G. Effect of iron treatment on circulating cytokine levels in ESRD patients receiving recombinant human erythropoietin. *Kidney Int* 2003; 64: 572–578.