

# KNOWLEDGE APPLIED TO PRACTICE

## APPLICATION DES CONNAISSANCES À LA PRATIQUE

### DIAGNOSTIC CHALLENGE

## Answer

Jason Mitchell, BSc;\* Gerald Lazarenko, MD†

The most correct answer is “a”. However, answer “c” would also be acceptable.

### Discussion

From an emergency medicine point of view, it is prudent to divide wide complex tachycardias (WCTs) into 4 groups: 1) ventricular tachycardia (VT); 2) supraventricular tachycardia (SVT) with aberrancy, accessory pathway conduction or bundle branch block (BBB); 3) electrolyte imbalances, particularly hyperkalemia or hypokalemia; and 4) toxicological causes, including overdoses of tricyclic antidepressants, certain cardiac medications, such as calcium channel blockers, and other drugs.<sup>1,2</sup>

The next step is to determine if the QRS complex is regular or irregular. Regular WCTs suggest a diagnosis of VT; SVT with accessory pathway conduction, aberrancy or BBB; hyperkalemia; or the toxicological causes mentioned above. Irregular WCTs indicate a diagnosis of atrial fibrillation with BBB or accessory pathway conduction, atrial flutter with aberrancy and variable atrioventricular (AV) conduction, or polymorphic VT. The electrocardiogram (ECG) shown in Figure 1 depicts a regular WCT.

The patient denied any drug use other than sotalol prescribed by his cardiologist and celecoxib, both of which he took at their regularly prescribed doses. Sotalol, like other antiarrhythmic agents, can be arrhythmogenic and can initiate VT and ventricular fibrillation. It is also known to cause torsades de pointes by prolonging ventricular repolarization. The use of this drug increases the possibility

that the patient is in VT, but it alone cannot exclude other causes of a regular WCT. The patient’s electrolyte panel disclosed a normal potassium level and his toxicology screen was also normal. The ECG in Figure 1 does not have a morphology that is representative of torsades de pointes. This leaves VT or SVT with aberrancy, accessory pathway conduction or BBB on the differential.

The importance of distinguishing between VT and SVT lies with the expected response to therapy. Therapies typically recommended for SVTs, particularly verapamil, are usually ineffective if the rhythm is actually VT, and may precipitate hemodynamic instability.<sup>3-6</sup> However, therapies usually recommended for VT can be effective if the rhythm is actually SVT and they are no more likely to worsen the hemodynamic stability of a patient with SVT than that of a patient with VT. Accordingly, if the type of WCT is unclear, it is best to treat the tachydysrhythmia as VT.<sup>7</sup>

The only diagnostic observation that distinguishes SVT from VT is to produce AV block. Findings of AV dissociation are diagnostic for VT. AV block may be produced by vagal manoeuvres, which may also terminate SVTs that are dependent on AV conduction. SVTs that are not dependent on AV conduction will persist, but the longer periods between QRS complexes may reveal P waves or atrial flutter waves allowing the mechanism of the SVT to be determined. ECG evidence of AV dissociation includes P waves that are dissociated from the QRS complexes and the presence of fusion or capture beats. Signs of AV dissociation on physical examination include intermittent cannon a

\*Medical Student, University of Calgary, Faculty of Medicine, Calgary, Alta., †Clinical Assistant Professor, University of Calgary, Faculty of Medicine, Calgary, Alta.

Submitted May 17, 2008; Revised May 19, 2008; Accepted May 19, 2008

*This article has not been peer reviewed.*

CJEM 2008;10(6):581-4

waves, variability of the first heart sound and variability in beat-to-beat systolic blood pressure.<sup>8</sup>

Other observations may be helpful but are nondiagnostic. Age greater than 35 years has been reported to have a 92% sensitivity and an 85% positive predictive value for VT, and age 35 years and younger was found to have a sensitivity of 54% and a 70% positive predictive value in support of SVT.<sup>9</sup> A previous history of myocardial infarction, recent angina pectoris or congestive heart failure has also been shown to be strongly predictive of VT.<sup>9,10</sup> The hemodynamic stability of the patient cannot be used to differentiate VT from SVT. In fact, researchers have proposed that physicians often misdiagnose VT as SVT when the patient appears to be hemodynamically stable based on the incorrect assumption that such stability is incompatible with VT.<sup>11,12</sup>

Certain QRS complex criteria can also help to distinguish SVT from VT. The Brugada criteria assess in a stepwise manner 4 qualities of the QRS complex that support a diagnosis of VT. These include the absence of RS complexes in all precordial leads, an interval greater than 100 msec from R wave onset to the nadir of the S wave in any precordial lead, the presence of AV dissociation and QRS morphologic criteria for VT.<sup>13,14</sup> In terms of QRS morphology, with a right bundle branch block (RBBB) morphology, VT is favoured over SVT by the presence of a monophasic or biphasic QRS in V1 and a V6 R/S ratio of less than 1. With left bundle branch block (LBBB) morphology, VT is more likely than SVT when the initial R wave in lead V1 is

longer than 30 msec or when the initial R wave in lead V1 is followed with a broadly down-sloping, notched S wave with a width of more than 60 msec. The presence of any Q wave in lead V6 also supports VT (Fig. 2).

The above patient was hemodynamically stable and had no pre-existing coronary artery disease or congestive heart failure. History and laboratories were not compatible with an electrolyte or toxicological emergency. The ECG showed a regular WCT with an RS complex present in V1–V6. The interval from the onset of the R wave to the nadir of the S wave was not greater than 100 msec. There was no AV dissociation. The LBBB pattern in V6 showed no Q wave and the R/S ratio was greater than 1.

## Conclusion

The ECG is supportive of an SVT with aberrancy using Brugada and other criteria. On further questioning, the patient stated that he had seen an electrophysiologist who diagnosed him with an SVT with aberrancy and the patient was waiting for ablation. The patient was subsequently treated with 12 mg of adenosine that terminated the WCT. A follow-up ECG disclosed that the arrhythmia had resolved (Fig. 3).

It is important to reinforce the fact that if the underlying cause of a WCT is uncertain, it is safest to conclude that the rhythm is VT. Electrical cardioversion is the treatment of choice in any patient with WCT of uncertain etiology or

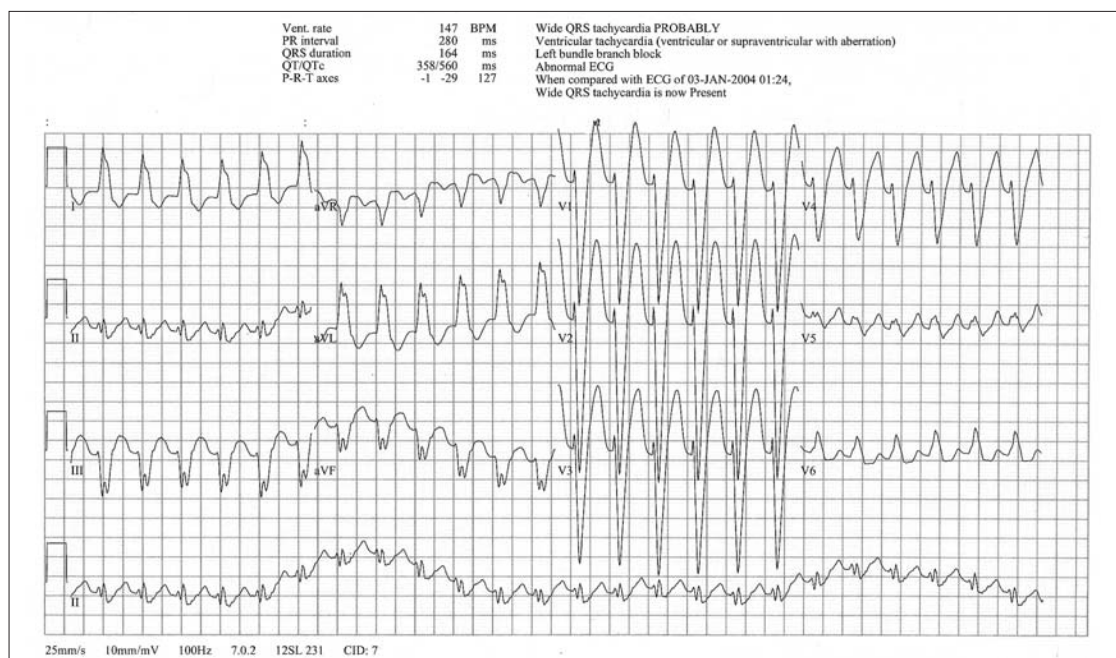
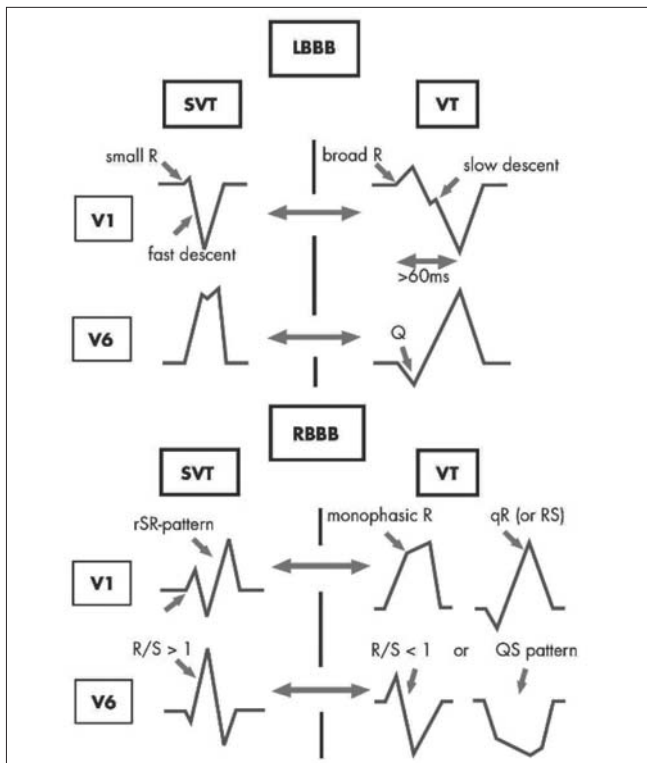


Fig. 1. Initial 12-lead electrocardiogram (ECG) of a 45-year-old man experiencing palpitations. BPM = beats per minute.



**Fig. 2. Morphological wide QRS complex criteria differentiating ventricular tachycardia (VT) from supraventricular tachycardia (SVT) with left bundle branch block (LBBB) or SVT with right bundle branch block (RBBB). Reproduced with permission from Eckardt L, Breithardt G, Kirchhof P. Approach to wide complex tachycardias in patients without structural heart disease. *Heart* 2006;92:704-11.<sup>14</sup>**

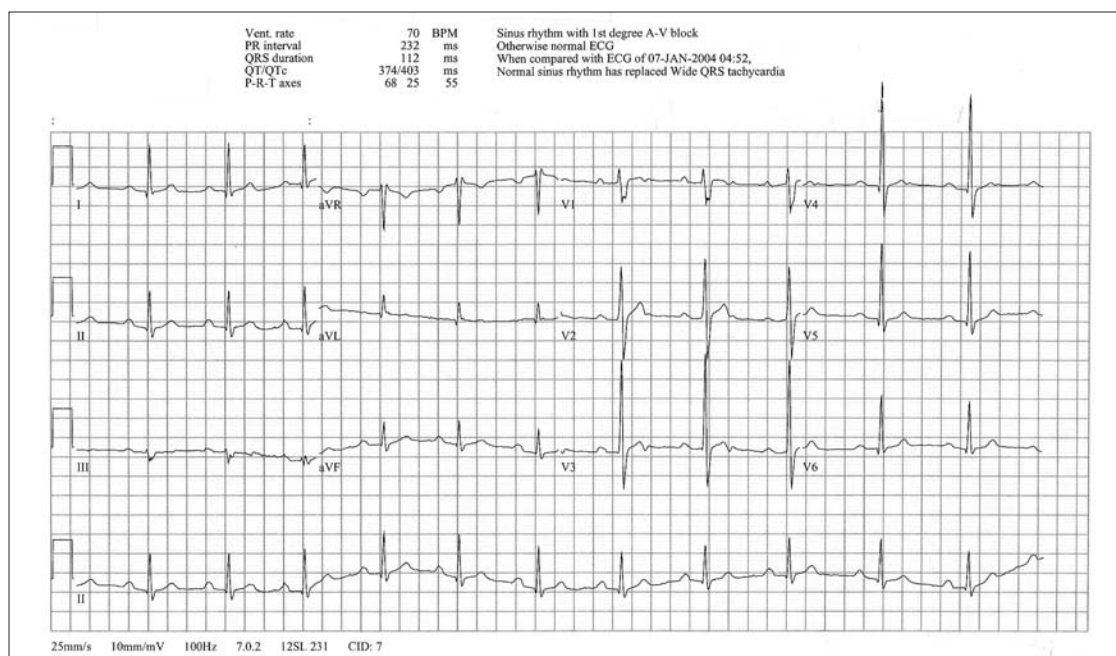
with hemodynamic instability. However, a detailed history, thorough physical examination, and accurate analysis of the ECG in stable patients, such as the patient in this scenario, may help the clinician to determine the correct etiology for the arrhythmia and to select the most appropriate therapy.

**Competing interests:** None declared.

**Keywords:** wide complex tachycardia, ventricular tachycardia, supraventricular tachycardia, Brugada criteria

## References

1. Holstege CP, Eldridge DL, Rowden AK. ECG manifestations: the poisoned patient. *Emerg Med Clin North Am* 2006;24:159-77.
2. Wald DA. ECG manifestations of selected metabolic and endocrine disorders. *Emerg Med Clin North Am* 2006;24:145-57.
3. Stewart RB, Bardy GH, Greene HL. Wide complex tachycardia: misdiagnosis and outcome after emergent therapy. *Ann Intern Med* 1986;104:766-71.
4. Dancy M, Camm AJ, Ward D. Misdiagnosis of chronic recurrent ventricular tachycardia. *Lancet* 1985;2:320-3.
5. Buxton AE, Marchliski FE, Doherty JU, et al. Hazards of intravenous verapamil for sustained ventricular tachycardia. *Am J Cardiol* 1987;59:1107-10.
6. Garratt C, Antoniou A, Ward D, et al. Misuse of verapamil in pre-excited atrial fibrillation. *Lancet* 1989;8:367-9.



**Fig. 3. Follow-up electrocardiogram (ECG) in a patient treated with 12 mg adenosine showing normal sinus rhythm with first degree atrioventricular (AV) block. BPM = beats per minute.**

7. Zipes DP, Camm AJ, Borggrefe M, et al. ACC/AHA/ESC 2006 guidelines for management of patients with ventricular arrhythmias and the prevention of sudden cardiac death: a report of the American College of Cardiology/American Heart Association Task Force and the European Society of Cardiology Committee for Practice Guidelines: developed in collaboration with the European Heart Rhythm Association and the Heart Rhythm Society. *Circulation* 2006;5:e385-484.
8. Shah CP, Thakur RK, Xie B, et al. Clinical approach to wide QRS complex tachycardias. *Emerg Med Clin North Am* 1998; 16:331-60.
9. Baerman JM, Morady F, DiCario LA, et al. Differentiation of ventricular tachycardia from supraventricular tachycardia with aberration: value of the clinical history. *Ann Emerg Med* 1987;16:40-3.
10. Tchou P, Young P, Mahmud R, et al. Useful clinical criteria for the diagnosis of ventricular tachycardia. *Am J Med* 1988;84:53-6.
11. Morady F, Baerman JM, DiCarlo LA Jr, et al. A prevalent misconception regarding wide-complex tachycardias. *JAMA* 1985;254:2790-2.
12. Spice C, Stewart K. Misdiagnosis of ventricular tachycardia. *Lancet* 1999;354:2165.
13. Brugada P, Brugada J, Mont L, et al. A new approach to the differential diagnosis of a regular tachycardia with a wide QRS complex. *Circulation* 1991;83:1649-59.
14. Eckardt L, Breithardt G, Kirchhof P. Approach to wide complex tachycardias in patients without structural heart disease. *Heart* 2006;92:704-11.

**For the challenge, see page 572.**

---

**Correspondence to:** Mr. Jason Mitchell, 50 Bears paw Way, Calgary AB T3R 1A4; jason.mitchell@med.ucalgary.ca

### **IMPORTANT ANNOUNCEMENT!**

*CJEM* is moving its submission and tracking system to Manuscript Central (Scholar One) and we plan to begin accepting submissions on January 5, 2009. More information and updates can be found on our website at [www.cjem-online.ca](http://www.cjem-online.ca).