

## Clinical Record

Ms L Robb takes responsibility for the integrity of the content of the paper

**Cite this article:** Robb L, Hey SY, Reid H, Nixon IJ. Introducing ethanol ablation as a treatment for thyroid cysts in the emergency setting. *J Laryngol Otol* 2023;**137**:467–470. <https://doi.org/10.1017/S002221512200189X>

Accepted: 9 August 2022  
First published online: 17 August 2022


### Key words:

Otolaryngology; Thyroid Diseases;  
Ablation Techniques

### Author for correspondence:

Ms Lydia Robb, Plastic Surgery Department,  
NHS Tayside, Ninewells Hospital,  
Dundee DD1 9SY, Scotland, UK  
E-mail: [Lydia.robbs@doctors.org.uk](mailto:Lydia.robbs@doctors.org.uk)

# Introducing ethanol ablation as a treatment for thyroid cysts in the emergency setting

L Robb<sup>1</sup> , S Y Hey<sup>2</sup>, H Reid<sup>3</sup> and I J Nixon<sup>2</sup>

<sup>1</sup>Department of Plastic and Reconstructive Surgery, Ninewells Hospital, NHS Tayside, Dundee, Scotland, UK,

<sup>2</sup>Department of Otolaryngology, St John's Hospital at Howden, NHS Lothian, Livingston, Scotland, UK and

<sup>3</sup>Department of Radiology, St John's Hospital at Howden, NHS Lothian, Livingston, Scotland, UK

## Abstract

**Background.** Ethanol ablation for the treatment of thyroid cysts has been well documented in the literature as a safe, effective treatment option in the elective setting. This study demonstrates the use of ethanol ablation in the emergency setting.

**Methods.** Three patients presenting with airway-threatening compressive symptoms secondary to a thyroid cyst were treated with ethanol ablation within 24 hours of presentation to hospital.

**Results.** All patients had symptom resolution at a median of nine months follow up post procedure. Sixty-six per cent of patients required only one treatment. There was a median of 100 per cent radiological resolution of the cystic component. The median Glasgow Benefit Inventory score was +27.7, similar to that for tonsillectomy.

**Conclusion.** Ethanol ablation is a safe, cost-effective and efficient treatment option for thyroid cysts in the acute setting.

## Introduction

Thyroid cysts account for 25 per cent of thyroid nodules and are generally benign. However, they can cause compressive symptoms because of local enlargement and some cases require intervention. Although aspiration of a cyst improves symptoms, this is short-lived, with an estimated 90 per cent re-accumulation rate.<sup>1</sup> Recurrent thyroid cysts are definitively managed with surgical intervention, with the associated complications of thyroid surgery and general anaesthesia.<sup>2</sup>

New techniques have been adopted for minimally invasive management of thyroid lesions, which have been well explored by Hegedüs *et al.*<sup>3</sup> and Papini *et al.*<sup>4</sup> Percutaneous ethanol ablation is a technique that allows convenient, safe and cost-effective out-patient management of thyroid cysts.<sup>5,6</sup> High purity ethanol is injected into the cystic lesion to induce coagulative and ischaemic necrosis, resulting in fibrosis and atrophy of the nodule.<sup>7</sup> Ethanol ablation has been demonstrated to have a high success rate for a relatively low cost (£91.91 per unit), and its use reduces length of hospital stay through a day-case service. The cost of surgical intervention for benign thyroid nodules is estimated at £3689, which could be avoided if patients were managed successfully with ethanol ablation.<sup>6</sup>

The literature suggests that ethanol ablation can provide a recurrence rate as low as 6.5–20 per cent,<sup>8,9</sup> in comparison to a recurrence rate of over 80 per cent with aspiration alone,<sup>10</sup> which is currently the first-line treatment. Ethanol ablation has demonstrated a 95 per cent volume reduction of cystic thyroid nodules, with reported high therapeutic success (in terms of symptoms and cosmetic score).<sup>11</sup> The use of ethanol ablation as a first-line treatment could have benefits in terms of minimising cost, and reducing patient attendances and length of hospital stay, and it is minimally invasive.

Despite the clear benefits of ethanol ablation, its demonstrated success has only been described in the elective or semi-elective setting. To our knowledge, no study has described the use of ethanol ablation in the emergency setting. This case series aimed to present the benefits of adopting ethanol ablation as a first-line treatment, by demonstrating the efficiency of its use within semi-emergent cases.

## Our service

Our centre introduced an ethanol ablation service within the otolaryngology head and neck surgery department, working closely with the radiology team. Patients referred to this service between 2017 and 2020 were treated as out-patients, providing they met pre-agreed inclusion criteria.

Ethanol ablation is currently offered on an elective basis. The results from our introduction of this service have been published, demonstrating this technique as safe, effective, well-tolerated and economical.<sup>12</sup> Within that larger cohort of 26 patients treated in our unit with ethanol ablation on a semi-elective basis, the average volume reduction from baseline was 80 per cent.

Since our introduction of this service, the unit has also offered this treatment to patients who present in the acute setting with compressive symptoms. This small case series demonstrates the use of ethanol ablation in three patients who presented with acute airway compromising symptoms.

### Materials and methods

Caldicott approval was obtained from NHS Lothian (reference number: 16113). All patients were admitted under the otolaryngology team, and then flagged to radiology and identified as potential candidates for emergency ethanol ablation. Patients were consented for the treatment-related risks, which include pain, haematoma, failure, numbness, injury to the recurrent laryngeal nerve and laryngeal necrosis.

### Technique

The technique for ethanol ablation involved infiltration of local anaesthetic using an ultrasound-guided aseptic single puncture method with a 19–21 G needle injected into the thyroid cyst. The cyst is aspirated to near dryness and then instilled with 100 per cent ethanol to a maximum of 20 ml. The technique was described in detail in our publication of the larger cohort of patients;<sup>12</sup> the technique for the emergency setting does not differ from that of the elective setting.

### Outcome measures

Patients were assessed clinically for the presence of ongoing symptoms. Radiological outcome measurements were obtained using serial ultrasound scanning of the cyst. The median follow-up duration was 24 weeks (range, 6 weeks to 10 months). Radiological imaging was conducted in the form of computed tomography and ultrasound imaging of the thyroid cyst prior to treatment, followed by ultrasound imaging following treatment with ethanol ablation (Figure 1).

Patient-reported outcome measurements were collected using the Glasgow Benefit Inventory, completed at a median of nine months post treatment. The Glasgow Benefit Inventory is a validated post-interventional questionnaire applicable to ENT procedures that assesses changes in health status, providing a comparable patient-reported outcome measurement.

### Participants

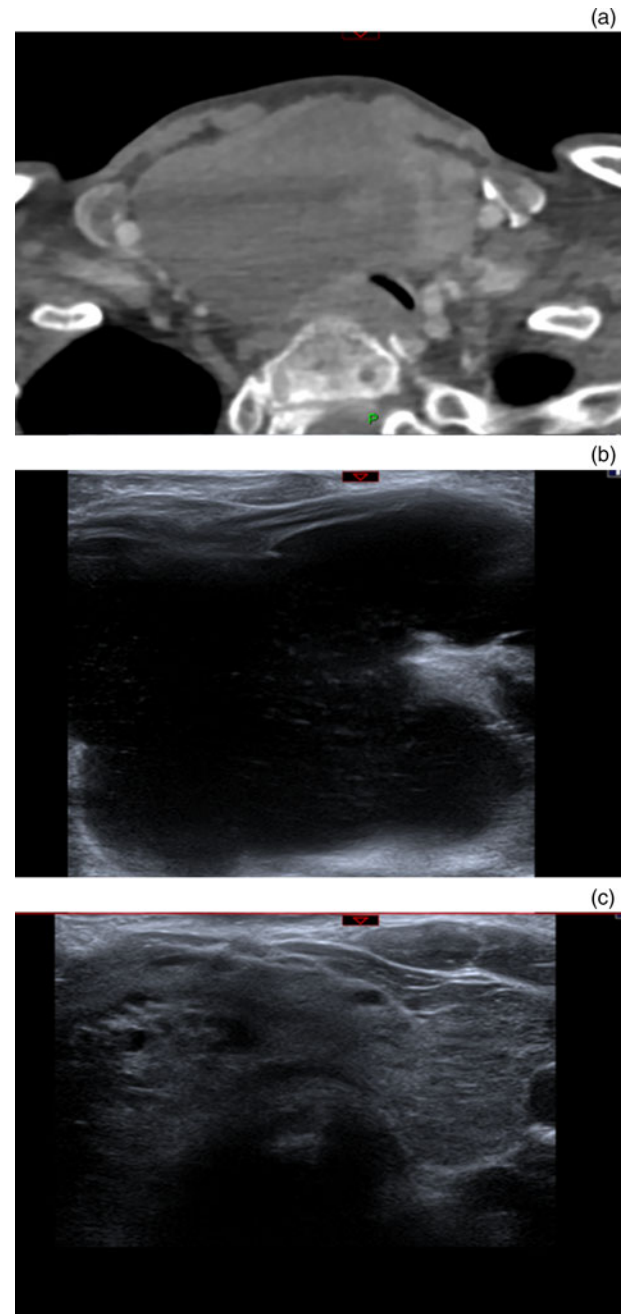
Since 2019, a total of three patients have been admitted under our department's care because of their presenting compressive symptoms secondary to a cystic thyroid nodule in the acute setting. All were offered treatment with ethanol ablation in the first instance.

### Results

Three patients (two females and one male) were treated with ethanol ablation during the study period. Their median age was 41 years (range, 23–85 years). The patients presented with acute dyspnoea, pain and swelling, with one patient also reporting dysphagia. All patients were treated with ethanol ablation within 24 hours of presentation in the acute setting (Table 1).

### Outcomes

The median pre-ablation volume was 97.5 ml (range, 12.8–172.9 ml). The median volume aspirated was 90 ml (range,



**Fig. 1.** (a) Computed tomography image of large thyroid cyst. (b) Ultrasound scanning image of large thyroid cyst prior to treatment with ethanol ablation. (c) Ultrasound scanning image of large thyroid cyst following ethanol ablation treatment, with trachea now in view. P = posterior

20–135 ml), varying depending on pre-ablation volume. The median volume of ethanol injected was 10 ml (range, 8–13 ml). Radiological measurements post procedure, at a median follow up of eight weeks, revealed a median cyst volume percentage change from baseline of 100 per cent (range, 4.45–100 per cent).

Follow up, via telephone consultation, was conducted a median of nine months post procedure. Of the patients, 100 per cent reported complete resolution of symptoms and no cyst presence.

### Complications

Two of the three patients, with simple thyroid cysts, required only one treatment. These patients were found to have 100

**Table 1.** Summary of patient findings

Parameter	Patient 1	Patient 2	Patient 3
Pre-ablation size (mm)	82 × 74 × 57	60 × 75 × 40	43 × 27 × 22
Pre-ablation volume (ml)	172.9	97.5	12.8
Volume aspirated (ml)	135	90	20
Type of fluid	Dark brown	Blood-stained	Blood-stained
Volume of ethanol used (ml)	13	10	8
Time from procedure to 1st follow-up USS	9 weeks	6 weeks	6 weeks
Size at 1st follow-up USS (mm)	55 × 54 × 39	48 × 63 × 53	No residual cystic component
Post-ethanol ablation % reduction in size at 1st follow-up USS	66.50	17.80	100
Repeated procedure required?	No	Yes	No (patient discharged)
Time from procedure to 2nd follow-up USS	10 months	2 months	–
Size at 2nd follow-up USS (mm)	No residual cystic component	50 × 63 × 61	–
Post-ethanol ablation % reduction in size at 2nd follow-up USS	100	4.45	–
Outcome	Patient discharged; symptoms resolved	2 further aspirations + 2 additional ethanol ablation treatments; symptoms resolved	Symptoms resolved
Time from procedure to GBI assessment	10 months	9 months	7 months
GBI score	+27.7	+30.5	+11
Cyst volume (% change from baseline)	100	4.45	100

USS = ultrasound scanning; GBI = Glasgow Benefit Inventory

per cent radiological resolution of the thyroid cyst at a median follow up of eight weeks post procedure (range, 6–40 weeks), with no complications reported.

The third patient, an older adult with multiple co-morbidities, was found to have a large goitre with a cystic component. This patient required multiple treatments with ethanol ablation because of the recurrence of symptoms and radiological evidence of persistent cyst volume. The patient received ethanol ablation treatment on three occasions, each two months apart. There has been no further radiological assessment of the cyst following the third cycle of ethanol ablation, because of the impact of the coronavirus disease 2019 pandemic. However, at five months post procedure, the patient reported complete resolution of her symptoms and the swelling. No further complications were noted.

### Glasgow Benefit Inventory

Glasgow Benefit Inventory scores were calculated for all patients at a median of nine months following the initial procedure. The median Glasgow Benefit Inventory score was +27.7 (range, +11 to +30.5). Ethanol ablation had a similar Glasgow Benefit Inventory score to that of tonsillectomy (range, +17 to +35).

## Discussion

### Synopsis of key findings

In this case series, all three patients presented with acute airway-compromising compressive symptoms secondary to a

cystic thyroid nodule. All received treatment with ethanol ablation within 24 hours of presentation, with no complications. All patients reported symptom resolution at 7–10 months' follow up, with a median Glasgow Benefit Inventory score of +27.7. The findings indicate that ethanol ablation is a safe, convenient, cost-effective and efficient treatment option for thyroid cysts in the acute setting.

### Strengths

This is the first study to describe the use of this technique in the acute setting, within a cohort of patients with airway-threatening compressive symptoms.

In our case series, there were varied presentations, ranging from simple cysts to a large multinodular goitre with a cystic component. All patients reported symptom resolution. Similarly, radiological findings revealed a median of 100 per cent resolution. This supports guidelines indicating that ethanol ablation can be used safely for simple thyroid cysts, and can arguably be employed as a first-line intervention in the acute setting in patients with airway compromise.

### Limitations

The low number of cases in this series limits the conclusions that can be drawn. There are clear limitations of ethanol ablation treatment to consider. Ethanol ablation has been shown to have less efficacy in terms of volume reduction when there is an associated solid component to the thyroid cyst. Jang *et al.*

reported a 49 per cent recurrence rate if the solid component was greater than 20 per cent.<sup>13</sup>

- Cystic thyroid nodules can be treated with several techniques
- Ethanol ablation is an efficient, safe, convenient and cost-effective treatment option for thyroid cysts
- Ethanol ablation is a safe treatment option in the acute setting for simple thyroid cysts causing compressive symptoms
- Ethanol ablation can produce successful outcomes in the acute setting
- Patients may require repeated ethanol ablation treatments for symptom resolution

One patient from our cohort was found to have a large multinodular goitre with a cystic component, and had poor results initially. Difficulties can arise whilst aspirating large cysts; the cyst can distort as it deflates, and the contours of the neck change, resulting in difficulty monitoring the tip of the needle. This can be further exacerbated if the cyst extends into the mediastinum, as was the case in one of our patients. This leads to difficulties aspirating an appropriate volume of contents, causing a dilutional effect on the injected ethanol, with the treatment therefore being less effective. Despite this, subsequent repeated treatments led to symptom resolution in our patient. Patients with more complex nodules with varying components should perhaps be considered for alternative therapy considering the poor immediate success rates.

## Conclusion

Our early experience of ethanol ablation for thyroid cysts which present as airway emergencies suggests that this is a rapid and safe technique for managing patients, with a durable response rate.

**Acknowledgements.** The authors would like to acknowledge the joint efforts of the radiology department and otolaryngology department within St John's Hospital in Livingston, Scotland, UK.

**Competing interests.** None declared

## References

- 1 Paschke R, Hegedüs L, Alexander E, Valcavi R, Papini E, Gharib H. Thyroid nodule guidelines: agreement, disagreement and need for future research. *Nat Rev Endocrinol* 2011;**7**:354–61
- 2 Papini E, Pacella CM. Diagnosis of endocrine disease: thyroid ultrasound (US) and US-assisted procedure: from shadows into an array of applications. *Eur J Endocrinol* 2014;**170**:133–46
- 3 Hegedüs L, Frasoldati A, Negro R, Papini E. European Thyroid Association survey on use of minimally invasive techniques for thyroid nodules. *Eur Thyroid J* 2020;**9**:194–204
- 4 Papini E, Pacella CM, Solbiati LA, Achille G, Barbaro D, Bernardi S *et al.* Minimally-invasive treatments for benign thyroid nodules: a Delphi-based consensus statement from the Italian minimally-invasive treatments of the thyroid (MITT) group. *Int J Hyperthermia* 2019;**36**:376–82
- 5 Nixon IJ, Angelos P, Shaha AR, Rinaldo A, Williams MD, Ferlito A. Image-guided chemical and thermal ablations for thyroid disease: review of efficacy and complications. *Head Neck* 2018;**40**:2103–15
- 6 National Institute for Health and Care Excellence. *Thyroid Disease: Assessment and Management. NICE Guideline 145 [NG145]*. London: NICE, 2019;53–5
- 7 Hahn SY, Shin JH, Na DG, Ha EJ, Ahn HS, Lim HK *et al.* Ethanol ablation of the thyroid nodules: 2018 consensus statement by the Korean Society of Thyroid Radiology. *Korean J Radiol* 2018;**20**:609–20
- 8 Del Prete S, Caraglia M, Russo D. Percutaneous ethanol injection efficacy in the treatment of large symptomatic thyroid cystic nodules: ten-year follow-up of a large series. *Thyroid* 2002;**12**:815–21
- 9 Suh CH, Baek JH. Ethanol ablation of predominantly cystic thyroid nodules: evaluation of recurrence rate and factors related to recurrence. *Clin Radiol* 2015;**70**:42–7
- 10 Bennedbaek F, Hegedüs L. Treatment of recurrent thyroid cysts with ethanol: a randomized double-blind controlled trial. *J Clin Endocrinol Metab* 2003;**88**:5773–7
- 11 Sung JY, Baek JH, Kim KS, Lee D, Yoo H, Kim JK *et al.* Single-session treatment of benign cystic thyroid nodules with ethanol versus radiofrequency ablation: a prospective randomized study. *Radiology* 2013;**269**:293–300
- 12 Hey SY, Robb L, Gammack P, Smith DA, Rodrigues MA, Summers D *et al.* Introducing an ethanol ablation service for recurrent symptomatic thyroid cysts within the NHS—a prospective study of twenty-six patients. *Clin Otolaryngol* 2021;**46**:645–9
- 13 Jang S, Baek J, Kim J. How to manage the patients with unsatisfactory results after ethanol ablation for thyroid nodules: role of radiofrequency ablation. *Eur J Radiol* 2012;**81**:905–10