



# Local pulmonary administration of factor VIIa (rFVIIa) in massive pulmonary haemorrhage in post-operative cardiac infant

## Brief Report

**Cite this article:** Hamadah HK and Kabbani MS (2023) Local pulmonary administration of factor VIIa (rFVIIa) in massive pulmonary haemorrhage in post-operative cardiac infant. *Cardiology in the Young* **33**: 835–837. doi: [10.1017/S1047951122003006](https://doi.org/10.1017/S1047951122003006)


Received: 8 January 2022  
Revised: 9 June 2022  
Accepted: 4 September 2022  
First published online: 26 September 2022

### Keywords:

Pulmonary haemorrhage; recombinant factor rFVIIa; cardiac surgery

### Author for correspondence:

H. K. Hamadah, Section of Pediatric Cardiac ICU, King Abdulaziz Cardiac Center, King Abdulaziz Medical City, Ministry of National Guard-Health Affairs, Mail Code: 1423, P.O Box 22490, Riyadh 11426, Saudi Arabia. Tel: 966118011111, ext 13621; Fax: 966118011111, ext 16773. E-mail: [Hamadahmo@ngha.med.sa](mailto:Hamadahmo@ngha.med.sa)

Hussam K Hamadah<sup>1,2</sup>  and Mohamed S. Kabbani<sup>1,2,3</sup>

<sup>1</sup>King Abdulaziz Cardiac Center, King Abdulaziz Medical City, Ministry of National Guard-Health Affairs, Riyadh, Saudi Arabia; <sup>2</sup>King Abdullah International Medical Research Center, Riyadh, Saudi Arabia and <sup>3</sup>King Saud bin Abdulaziz University for Health Sciences, Riyadh, Saudi Arabia

### Abstract

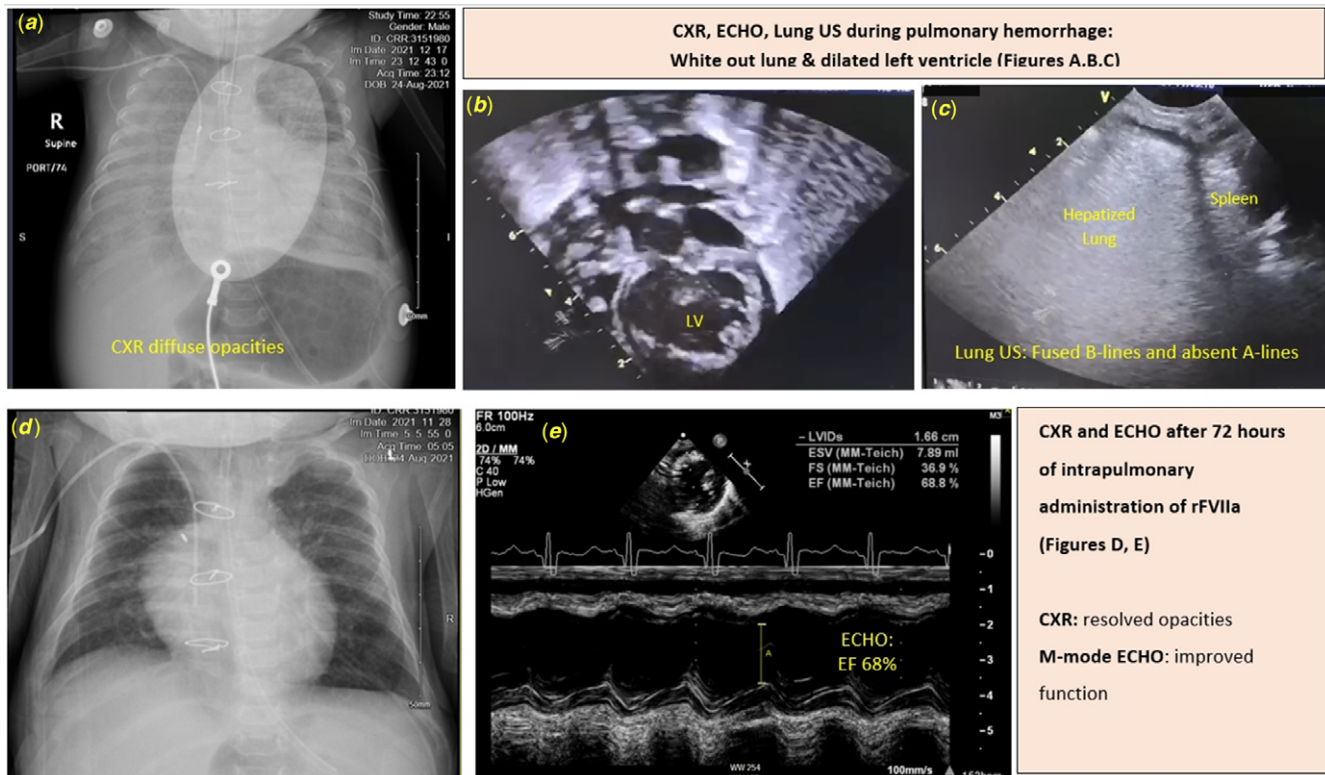
Diffuse pulmonary haemorrhage is an ominous condition that has a high paediatric mortality rate. Recombinant activated factor VIIa (rFVIIa) is a powerful haemostatic agent which has been used intravenously in life-threatening haemorrhage in variety of conditions in which conventional medical or surgical therapy are unsuccessful. We report off-label successful use of endotracheal rFVIIa for massive life-threatening respiratory haemorrhage following aspiration and cardiopulmonary resuscitation in a 3-month-old infant who was anticoagulated with enoxaparin following corrective cardiac surgery with other comorbidities. Off-label administration of endotracheal rFVIIa permitted rapid safe control of massive pulmonary haemorrhage and prevented further detrimental decline in respiratory function with satisfactory outcome.

Diffuse pulmonary haemorrhage in infants carries a poor prognosis and may lead to death. The conventional treatment is controversial and prompts aggressive multidisciplinary management.<sup>1,2</sup> Recombinant factor VIIa (rFVIIa) is a vitamin K-dependent glycoprotein that promotes hemostasis by activating the extrinsic pathway of coagulation cascade. This report describes the successful off-label lifesaving use of endotracheal (rFVIIa) for severe pulmonary haemorrhage and respiratory failure in an infant with repaired CHDs.

### Case report

A 3-month-old cardiac infant with Taussig-Bing anomaly post-neonatal corrected complex cardiac surgery with arterial switch operation, coarctation, and ventricular septal defect repair. He completed treatment of endo-vasculitis with antibiotics and was started previously on enoxaparin for multiple central vascular access thrombosis. On the day of hospital discharge, the patient had sudden milk aspiration followed shortly by cardio-pulmonary arrest. The patient received one cycle of cardiopulmonary resuscitation that led to the return of spontaneous circulation with observation of frothy bloody oral secretions before any attempt of device insertion in upper airway. The patient was intubated smoothly by direct laryngoscope and connected to conventional ventilation but continued to have isolated profuse frothy pulmonary haemorrhage with no other source of bleeding from oropharyngeal cavity.

While attempts were undertaken to control diffuse pulmonary haemorrhage, the infant demonstrated evidence of low cardiac output and required three inotropes to support compromised haemodynamic. Bedside echocardiography showed dilated left chambers with poor contractility (Fig 1). Patient developed sudden acute lung injury with mixed type of respiratory failure. Initial blood gas was consistent with mixed lactic metabolic and respiratory acidosis (pH 6.9, pCO<sub>2</sub> 60, HCO<sub>3</sub> 11, base deficit -20, O<sub>2</sub> saturation 30%, lactic acid 14) associated with a significant drop of haemoglobin from 10 to 6 g/dl. His initial CXR and lung ultrasound were consistent with white-out lung and interstitial lung disease, respectively (Fig 1). The patient continued to have massive airway bleeding for 2 hours that frequently obstructed his endotracheal tube and caused frequent sinus bradycardia episodes necessitated advanced cardio-pulmonary support with multiple doses of epinephrine through intravenous and endotracheal access. His initial coagulation profile showed mild abnormalities with INR 1.4 (range 0–0.5 seconds), PTT 50 (range 26–37 seconds), low molecular weight heparin (anti-factor Xa assay 0.35, range 0.4–1 units/ml), fibrinogen 1.2 (range 1.5–4.1 g/L), and D-dimer 1.8 (0–0.5 mg/L). As part of pulmonary haemorrhage management and resuscitation, multiple blood products were transfused including packed red blood cells (20 ml/kg) and fresh frozen plasma (10 ml/kg) in addition to intravenous vitamin K. Due to persistent unresolved life-threatening endotracheal bleeding, off-label rFVIIa (45 µg/kg) was injected in the lung through endotracheal tube while the infant was manually bagged with positive pressure ventilation. Administration of rFVIIa resulted in complete cessation of pulmonary bleeding within 15 minutes of its administration with no further episodes of bradycardia. The patient started to stabilise thereafter and connected to high frequency



**Figure 1.** Comparative CXR and point of care US imaging within 72 hours of administration of endotracheal rFVIIa following cardiac arrest and pulmonary haemorrhage, in 3-month-old infant with repaired congenital heart diseases. EF: ejection fraction; LV: left ventricle; US: ultrasound.

oscillator for 48 hours. CXR and Echocardiography showed dramatic improvement after 72 hours of life-threatening diffuse pulmonary haemorrhage event (Fig 1). Patient was extubated after 5 days and discharged home later with satisfactory condition and no sequel (Figs 1 and 2 outline patient progression).

## Discussion

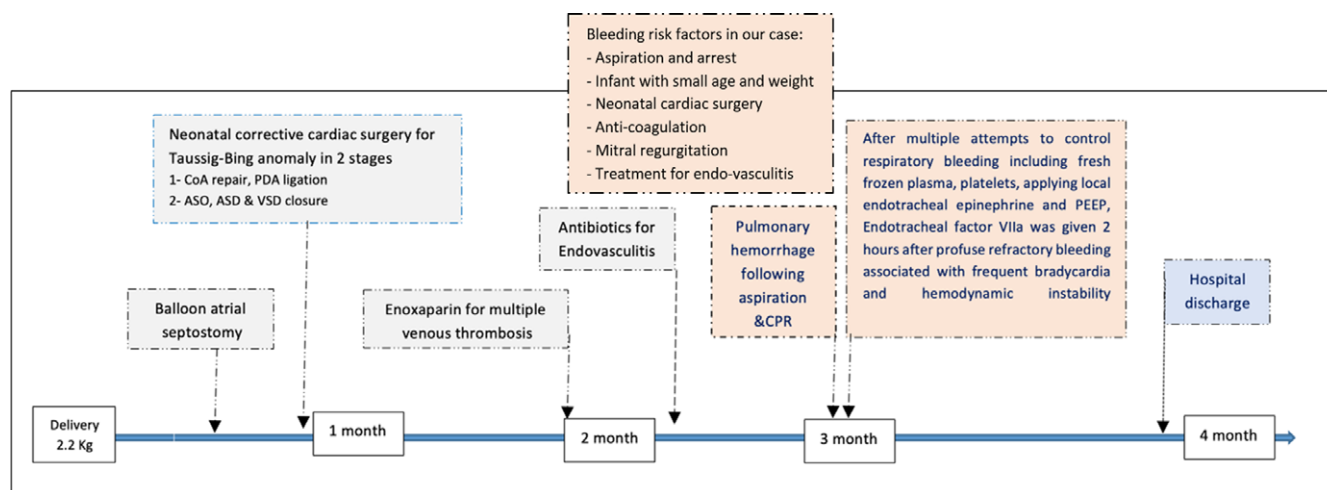
Recombinant activated factor VII (rFVIIa) has been primarily used in patients with haemophilia. The off-label use of rFVIIa has been increasing in non-haemophilic patients to treat uncontrolled bleeding in adults, children, neonates, and even preterm neonates.<sup>2</sup> Case reports and clinical studies have reported as well the effectiveness of rFVIIa in diffuse pulmonary haemorrhage mainly in haematology and oncology adult patients such as metastatic choriocarcinoma, haematopoietic stem cell transplantation, graft-versus-host disease, pneumonia, and sepsis;<sup>1-4</sup> However, many questions still remain pending regarding the formulations, doses, dosing regimens, and routes of administration either systemically or locally through endotracheal tube.<sup>1-4</sup> There are limited data on its intrapulmonary application in paediatric patients, and its benefit for neonates and infants less than 1 year of age remains unclear.<sup>1-3</sup>

rFVIIa promotes hemostasis by activating the extrinsic coagulation pathway by enhancing thrombin generation on the surface of activated platelets.<sup>5</sup> rFVIIa is a biological drug with a difficulty to pass the alveolo-capillary membrane if applied intravenously which necessitates a high systemic concentration with a higher risk of adverse systemic effects in compared to local application at the targeted site.<sup>6</sup>

Diffuse pulmonary haemorrhage in infants carries poor prognosis and may lead to death. The current treatment depends on treating possible aetiology and may include spectrum of interventions and medications such as avoiding local irritation, corticosteroids, antimicrobial agents, transfusions of different blood products to correct coagulopathy or anaemia, applying local vasoconstrictive agents, applying positive end-expiratory pressure and mechanical ventilation, extracorporeal membrane oxygenation, immunosuppressant, and exogenous surfactant. Surgical and bronchoscopy interventions can be considered in specific condition.<sup>1,2,6</sup> In our paediatric cardiac patient, we followed initially the traditional strategies to control pulmonary haemorrhage locally and systemically with no improvement. However, the bleeding persisted leading to cardio-respiratory embarrassment and life-threatening instability that justified in our judgment the off-label use of novel treatment with locally injected rFVIIa in endotracheal tube to control bleeding and to continue thereafter high frequency oscillator ventilation.

The exact duration needed for local rFVIIa injection to control pulmonary haemorrhage is difficult to define in the literature. However, we found immediate decline of pulmonary haemorrhage after local rFVIIa injection and total bleeding control within 15 minutes of local injection.

Multiple resuscitation doses of epinephrine through intravenous and endotracheal access were needed to manage symptomatic sinus bradycardia episodes in our patient. The bradycardia episodes were mainly due to severe hypoxia and poor gas exchange from pulmonary haemorrhage. With massive pulmonary haemorrhage intravenous epinephrine was more efficient to reverse frequent bradycardia than endotracheal epinephrine but both failed to control bleeding until endotracheal rFVIIa was administered.



**Figure 2.** Timeline diagram outlining patient's hospital clinical course over [4] months period in 4-month-old cardiac infant post neonatal corrected complex cardiac surgery with pulmonary haemorrhage treated with local endotracheal rFVIIa. ASO: arterial switch operation; ASD: atrium septum defect; CoA: CoArctiaon repair; CPR: cardiopulmonary resuscitation; PDA: patent ductus arteriosus; Peep: positive end expiratory pressure; VSD: ventricular septum defect.

Several risk factors have been associated with the development of pulmonary haemorrhage in infants, but the exact pathogenesis remains obscure. The association of massive alveolar haemorrhage with aspiration pneumonitis is unusual.<sup>7</sup> Pulmonary haemorrhage can be induced by local trauma such as tracheal suctioning or airway instrumentation or even feeding tube insertion. However, in our case, there was neither local trauma nor attempt for device insertion in upper airway prior to pulmonary haemorrhage. The bleeding that was noted only after the first cycle of resuscitation appeared as frothy oral bloody secretions and continued thereafter from endotracheal tube that was inserted by atraumatic intubation. Following insertion of advanced airway, no bleeding was noted from nasopharynx or oropharyngeal cavities by direct exam. Furthermore, the possibility of infectious causes of bleeding was excluded as tracheal aspirates cultures and nasopharyngeal swabs remained negative for bacterial and viral causes. Our patient was started 4 weeks before the event on enoxaparin for multiple thrombosis at sites of central venous accesses. The use of anti-coagulation can contribute to bleeding particularly with out of range values. The low molecular weight heparin assay of 0.35 IU/mL in our patient was in the lower limit of therapeutic range (0.4–1 IU/mL) and it is unlikely to be the cause of massive pulmonary haemorrhage. Other possible qualitative or quantitative hematological aetiologies for pulmonary haemorrhage were also excluded by extensive investigations.

Although it is understandable that the poor left ventricle function or mitral regurgitation can lead to dilated left chambers and offer a risk factor for pulmonary haemorrhage. However, the retrospective analysis of cardiac images in our case before the arrest showed mild mitral regurgitation and mild depressed cardiac function with mild dilatation of left chambers which could be seen in such surgeries. In our case, we attributed the pulmonary haemorrhage post cardiac surgery to multiple factors including aspiration, cardiopulmonary resuscitation, anti-coagulation, endo-vasculitis, and mild mitral regurgitation.

Pulmonary haemorrhage is known to be associated with comorbidity and mortality. In one published studies, the authors reported that death or survival with neurosensory impairment were at least doubled after serious pulmonary haemorrhage in infants.<sup>7</sup> We observed no major consequences after pulmonary

haemorrhage in our patient and was discharged home in satisfactory condition.

## Conclusion

Off-label use of local rFVIIa, in addition to standard measures, can help in achieving rapid control of severe pulmonary haemorrhage. Our report promotes an alternate local form of administration of pro-thrombotic agent (rFVIIa) in a novel fashion to control life-threatening pulmonary haemorrhage. It adds to the existing literature on the increasing use of rFVIIa in the paediatric cardiac surgical population.

**Acknowledgements.** This manuscript describes novel work and is not under consideration for publication/published by any other journal. All the author(s) have approved the manuscript and this submission.

**Financial Support.** This research received no specific grant from any funding agency or commercial or not-for-profit sectors.

**Conflicts of Interest.** None.

**Ethical Standards.** The manuscript was completed according to good clinical practice and approved by Institutional Research Board (IRB).

## References

1. Lauque D, Cadranel J, Lazor R, et al. Microscopic polyangiitis with alveolar hemorrhage: a study of 29 cases and review of the literature. *Medicine* 2000; 79: 222–233.
2. Park JA. Treatment of diffuse alveolar hemorrhage: controlling inflammation and obtaining rapid and effective hemostasis. *Int J Mol Sci* 2021; 22: 793.
3. Park JA. Diffuse alveolar hemorrhage and recombinant factor VIIa treatment in pediatric patients. *Korean J Pediatr* 2016; 59: 105–113.
4. Mandal SK, Sagar G, Sahoo M, et al. Recombinant activated factor VII for diffuse alveolar hemorrhage in microscopic polyangiitis. *Indian J Nephrol* 2012; 22: 130–132.
5. Monroe DM, Hoffman M, Oliver JA, et al. Platelet activity of high-dose factor VIIa is independent of tissue factor. *Br J Haematol* 1997; 99: 542–547.
6. Heslet L, Nielsen JD, Nepper-Christensen S. Local pulmonary administration of factor VIIa (rFVIIa) in diffuse alveolar hemorrhage (DAH) - a review of a new treatment paradigm. *Biologics* 2012; 6: 37–46.
7. Zahr RA, Ashfaq A, Marron-Corwin M. Neonatal pulmonary hemorrhage. *NeoReviews* 2012; 13: e302–e306.