

# A Retrospective Study of Multiple Sclerosis in Siriraj Hospital, Bangkok, Thailand

Sasitorn Siritho, Naraporn Prayoonwiwat

JOURNAL EXCHANGE. Published with permission from *Neurology Asia* 2006; 11: 55-61

**ABSTRACT:** *Objective:* To determine the demographic and clinical data of Thai multiple sclerosis (MS) patients. *Methods:* A retrospective study of 72 patients attending the MS clinic at Siriraj Hospital, Mahidol University, Thailand between January 1997 and June 2004. *Results:* Fifty-eight patients (81%) were classified as clinically definite MS, 5 (7%) as Devic's syndrome, and 9 (13%) as possible MS. There were 62 females (86%) and 10 males (14%). Age at onset was  $33 \pm 12$  years with a mean relapse rate of  $1.2 \pm 1.0$  attacks per annum. None had a family history of MS. Visual impairment (53%) was the most common manifestation. Only 16% had classic (western) form of MS. Positive oligoclonal bands were found in 21%, visual evoked potentials with a typical delayed latency in 28%. MRI brain lesions compatible with McDonald's criteria were seen in only 24%, and spinal MRI brain longer than 2 vertebral bodies in 62%. The mean Kurtzke's Expanded Disability Status Scale (EDSS) was 3.0. *Conclusions:* Thai MS patients had much more female occurrence, no family history, common optico-spinal form, long spinal MRI lesions and low positive CSF oligoclonal bands.

**RÉSUMÉ:** *Étude rétrospective sur la sclérose en plaques à l'Hôpital Siriraj de Bangkok, en Thaïlande.* *Objectif :* Décrire les données démographiques et cliniques des patients thaïlandais atteints de sclérose en plaques (SEP). *Méthodes :* Il s'agit d'une étude rétrospective de 72 patients fréquentant la clinique de SEP de l'Hôpital Siriraj de l'Université Mahidol en Thaïlande, entre janvier 1997 et juin 2004. *Résultats :* Chez cinquante-huit patients (81%) le diagnostic de SEP était certain, 5 patients (7%) avaient un syndrome de Devic et chez 9 patients (13%) le diagnostic de SEP était possible. Soixante-deux des 72 patients (86%) étaient des femmes et 10 étaient des hommes (14%) et l'âge de début était de  $33 \pm 12$  ans avec un taux de récurrence de  $1,2 \pm 1,0$  par année. Aucun des patients n'avait une histoire familiale de SEP. La manifestation la plus fréquente était l'atteinte visuelle (53%). Seulement 16% des patients avaient la forme classique de la SEP observée dans les pays occidentaux. Des bandes oligoclonales étaient présentes chez 21% des patients et les potentiels évoqués visuels démontraient la présence d'une latence retardée typique chez 28%. À l'IRM, des lésions cérébrales rencontrant les critères de McDonald ont été observées chez seulement 24% des patients et des lésions spinales s'étendant à plus de deux corps vertébraux chez 62%. Le score moyen à l'échelle Kurtzke's Expanded Disability Status Scale (EDSS) était de 3,0. *Conclusions :* Les patients thaïlandais atteints de SEP étaient surtout des femmes, sans histoire familiale de SEP, qui présentaient la forme la plus fréquente de SEP, soit la forme optico-spinale et de longues lésions spinales à l'IRM. Les bandes oligoclonales dans le LCR étaient peu fréquentes chez ces patients.

Can. J. Neurol. Sci. 2007; 34: 99-104

Multiple sclerosis (MS) among Eastern and Western countries differs in many aspects such as prevalence, MS types, clinical manifestations, magnetic resonance imaging (MRI) and cerebrospinal fluid (CSF) findings.<sup>1-10</sup> Moreover, the McDonald criteria which incorporates MRI for diagnosis, may not be practical in some Asian countries because of the inaccessibility.<sup>11-12</sup> The objective of our study is to determine the demographic data, symptoms and signs, associated diseases, investigations, treatment regimens in our MS patients in Bangkok, Thailand.

## METHODS

This is a retrospective study of 72 patients attending the MS Clinic, a tertiary referring MS clinic at Siriraj Hospital, Mahidol

University, Thailand; between January 1997 and June 2004. Baseline data included history, presenting symptoms and signs, investigations particularly MRI, visual evoked potentials (VEPs), CSF analysis; and treatments were collected. Multiple sclerosis diagnosis was based on Poser's criteria.<sup>13</sup> Acute

From the Division of Neurology, Department of Medicine, Faculty of Medicine, Siriraj Hospital, Mahidol University, Prannok Road, Bangkok, Thailand.

Reprint requests to: Naraporn Prayoonwiwat, Division of Neurology, Department of Medicine, Faculty of Medicine, Siriraj Hospital, Mahidol University, Prannok Road, Bangkok, 10700, Thailand.

transverse myelitis was defined as an acute illness with both sensory and motor impairment, the motor involvement being severe and bilateral with an onset less than four weeks.<sup>14,15</sup> Recurrent optico-spinal form of MS was defined as clinical relapses limited to the optic nerve and spinal cord. Western form of MS was defined as neurological deficits within as well as beyond the optic nerve and spinal cord.<sup>1,2,4,5</sup> Diagnostic criteria for Devic's syndrome modified from Kuroiwa et al, was defined as an illness with acute optic neuritis and transverse (severe) myelitis usually occurring consecutively within a period of less than several weeks.<sup>16</sup> The Siriraj Ethic Committee approved this study.

### Statistical Analysis

Analysis was done with Student t-test for quantitative data; Chi-square test and Fisher-Exact test for qualitative data. Kruskal-Wallis test was used to find a correlation between MS-type and the Extended Disability Status Score (EDSS),<sup>17</sup> Mann-Whitney-U test for a relationship between the outcome and the location of an attack; Spearman's correlation for an association between number of attacks and outcome. SPSS version 10.0 software was used to perform the statistical analysis.

## RESULTS

### Demographic data

Records from 76 patients were reviewed. Seven patients were from northern, 8 from southern, 8 from eastern and 53 patients from central parts of Thailand. Four patients were excluded; one with optic neuritis and later diagnosed as systemic lupus erythematosus (SLE); one had positive p-ANCA favoring an other systemic autoimmune process; one had MR angiography findings suggestive of vasculitis; one had atypical presentation of facial diplegia with Horner's syndrome.

From the remaining 72 patients, there were 62 female (86%) and 10 male (14%) patients with a female to male sex ratio of 6.2:1. The age at onset varied between 16 to 64 years (mean 33 ± 12 years; median 32 years); however, most of the patients had

initial symptoms between 20-40 years old (48 patients; 67%) (Table 1). None had a family history of MS. The mean duration of illness was 6.6 ± 5.9 years (range 0.5-32; median 4.5). The mean number of relapses was 5.5 ± 5.2; (range 1- 32; median 4). The mean relapse rate was 1.2 ± 1.0 attacks per annum (median 0.9).

Fifty-three patients attended the clinic regularly (74%), eighteen (25%) were referred to local hospitals or lost to follow up. One patient died at a local hospital after having a high cervical cord relapse; no autopsy was done.

### Clinical course and MS type

Clinical course was relapsing-remitting (RR-MS) in 54 patients (75%); secondary progressive type (SP-MS) in one (1%); three (4%) progressive relapsing (PR-MS). None had primary progressive (PP-MS). Of the remaining 14 patients, five (7%) had Devic's syndrome; nine (13%) had possible MS. Recurrent opticospinal form of MS was found in 28 patients (39%), followed by classic western form in 11 patients (15%) (Table 2).

### Symptoms and signs

The most common location of first attacks was visual pathway, predominantly the optic nerve (51%), followed by spinal cord 26%, brainstem 19%, cerebral hemisphere 1% and opticospinal 1% respectively. None presented with cerebellar involvement (Table 3). The most common initial presentations were visual impairment (51%), weakness predominantly paraparesis (38%), sensory loss (39%), diplopia (8%), gait ataxia (6%), and dysarthria (1%) respectively (Table 4). For the visual presentation, the optic neuritis was simultaneous or almost simultaneous in both eyes (19%). Paroxysmal symptoms such as painful tonic spasm, trigeminal neuralgia, abnormal sensation as burning sensation in the feet were seldom seen initially (1%).

All five patients with Devic's syndrome had visual impairment with subsequent paraparesis or vice versa within 30 days from the first symptom. Of the nine possible MS, six presented with optic neuritis and two transverse myelitis.

**Table 1: Age at onset according to clinical forms of disease**

Age at onset (years)	RR-MS	PP-MS	SP-MS	PR-MS	Devic's syndrome	Possible MS	Total
<20	4	0	0	0	0	1	5
20-29	24	0	0	1	2	3	30
30-39	12	0	1	2	2	1	18
40-49	9	0	0	0	1	2	12
50-59	4	0	0	0	0	2	6
≥60	1	0	0	0	0	0	1
Total	54	0	1	3	5	9	72

RR-MS: relapsing remitting MS, PP-MS: primary progressive MS, SP-MS: secondary progressive MS, PR-MS: progressive relapsing MS

Among the 58 clinical definite MS (CDMS) patients, a total of 110 relapses involved the visual pathway, 89 relapses (81%) had unilateral involvement. Twenty-one relapses (19%) presented with simultaneous or almost simultaneous bilateral optic neuritis. Paroxysmal tonic spasm was noted in 25 patients (35%). All but one patient had myelitis.

### Investigation

For their first attacks, sixty patients (83%) underwent lumbar puncture, neuroimaging by CT scan in 10 patients (14%) and MRI in 58 patients (81%). VEPs were performed in 38 patients (53%). Thirty seven patients (51%) received all three investigations.

### CSF analysis

Fifty-three patients (88%) had oligoclonal bands analysis at their initial presentation. Eleven patients (21%) were positive. Two patients had matched serum-CSF patterns, three additional patients showed positive oligoclonal band in subsequent relapses.

### MRI

Magnetic resonance imaging were available for review in 25 patients. They consisted of 21 brain and 14 spinal MRIs. Ten patients had both brain and spinal MRI. For the brain MRI, in T2 weighted images, most lesions were found at juxtacortical and

**Table 2: Clinical site of involvement**

	RR-MS	PP-MS	PR-MS	SP-MS	Possible MS
Optic	3	0	0	0	5
Spinal	4	0	0	0	3
Opticospinal	26	0	2	0	0
Western (optic-spinal and beyond)	9	0	1	1	0
Brainstem-spinal	4	0	0	0	0
Optic-brain	1	0	0	0	0
Brainstem-cerebellum-spinal	1	0	0	0	0
Brainstem-cerebellum	1	0	0	0	0
Optic-brainstem	3	0	0	0	0
Brain	0	0	0	0	1
Optic, brainstem, cerebellum	1	0	0	0	0
Optic, cerebellum	1	0	0	0	0
Total	54	0	3	1	9

RR-MS: relapsing remitting MS, PP-MS: primary progressive MS, SP-MS: secondary progressive MS, PR-MS: progressive relapsing MS

**Table 3: Clinical location of involvement during the first illness**

	RR-MS	PP-MS	SP-MS	PR-MS	Devic's syndrome	Poss MS	Total
Optic	24	0	1	2	4	6	37
Brain	0	0	0	0	0	1	1
Brainstem	13	0	0	1	0	0	14
Cerebellum	0	0	0	0	0	0	0
Spinal cord	16	0	0	0	1	2	19
Optic and spinal cord	1	0	0	0	0	0	1

RR-MS: relapsing remitting MS, PP-MS: primary progressive MS, SP-MS: secondary progressive MS, PR-MS: progressive relapsing MS, Poss MS: possible MS

**Table 4: Presenting symptoms according to clinical forms of disease**

	RR-MS	PP-MS	SP-MS	PR-MS	Devic's syndrome	Poss MS	Total
Blurred vision	23	0	1	2	4	7	37
Diplopia	5	0	0	1	0	0	6
Weakness	22	0	0	1	1	3	27
Stiffness	0	0	0	0	0	0	0
Abnormal sensation	1	0	0	0	0	0	1
Sensory loss	24	0	0	0	0	4	28
Ataxia	4	0	0	0	0	0	4
Dysarthria	1	0	0	0	0	0	1

RR-MS: relapsing remitting MS, PP-MS: primary progressive MS, SP-MS: secondary progressive MS, PR-MS: progressive relapsing MS, Poss MS: possible MS

periventricular regions. Six patients (38%) had  $\geq 9$  T2 lesions. Three patients (19%) had gadolinium-enhanced lesions. For the spinal MRI, eight patients (62%) had lesion longer than 2 vertebral body segments. Cord swelling was found in four patients (31%), atrophy in six patients (46%), three patients (23%) had normal studies. Whole cross-sectional cord involvement was found in six patients (46%). Only six patients (24%) fulfilled the McDonald's criteria for dissemination in space. The sensitivity of MRI was 24 % (Table 5).

### VEP

Thirty-nine patients underwent VEPs. Four (10%) demonstrated a decreased amplitudes while typical delayed P100 latency was seen in 10 patients (26%). Seven patients (18%) had both decreased amplitude and delayed P100 latency. Sixteen patients (41%) had no significant changes in amplitudes and velocities. Data was not available in 2 patients (5%).

### Other blood tests

ANA was positive in 20 of 50 patients (40%) with low titers varying from 1:40 to 1:640; 3 patients had a titer of 1:2560. Speckle type of ANA was the most common pattern (60%), followed by homogenous pattern (20%).

### Treatment

Sixty-two patients (86%) received intravenous methylprednisolone for an acute attack. Twenty-five patients (35%) had had  $\alpha$ -interferon at least once in the follow-up period. All had RR-MS. Eighteen patients (72%) terminated the treatment; 8 patients for financial reason, four patients had leukopenia of  $2,300 \text{ mm}^3$ , three patients gave the reasons of high fever and severe myalgia, and two patients because there was no response from the treatment. Common local side effects were tenderness and erythematous nodules at injection sites. One had severe skin necrosis; another developed focal lipodystrophy.

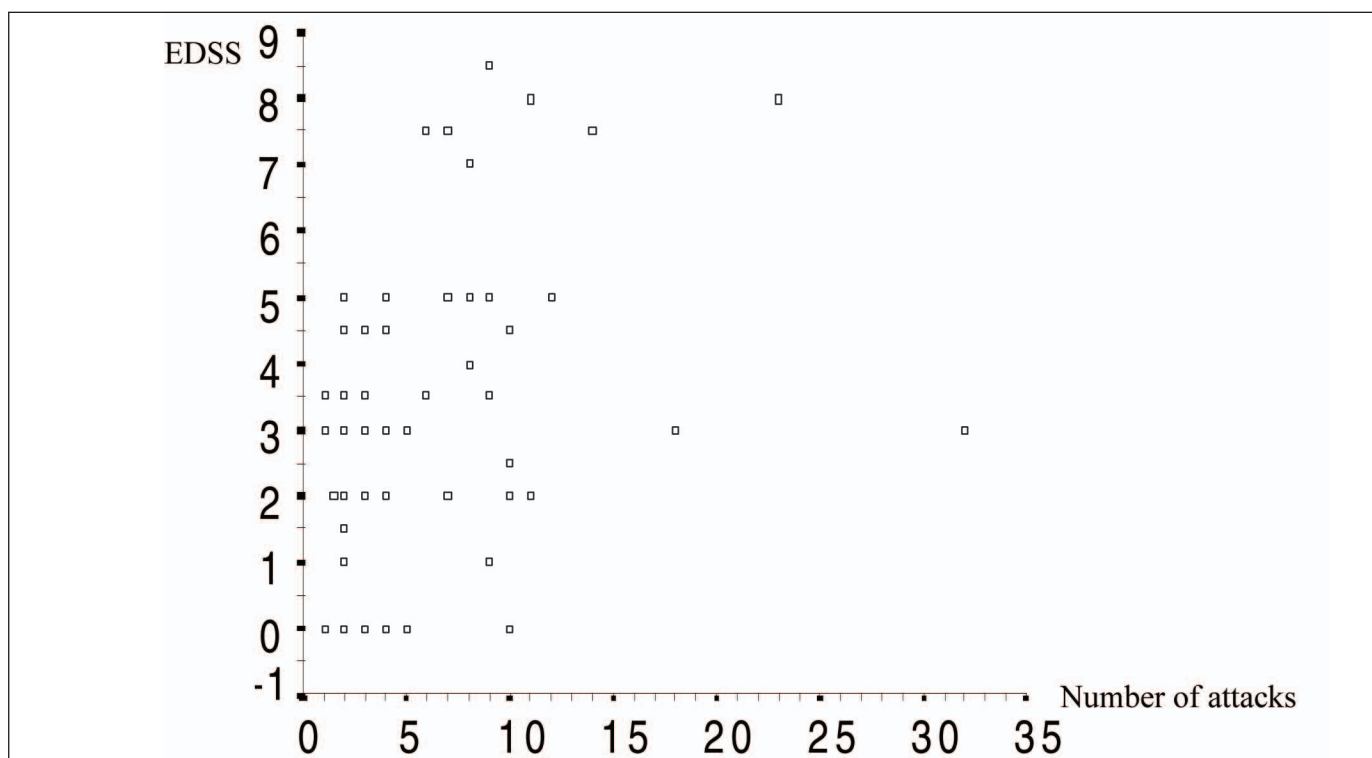
Azathiopine was used in 23 patients (32%) at a dose of 50-100 mg/day. One patient discontinued the drug due to persistent low white cell count despite dose adjustment.

### Outcome

The Kurtzke's Expanded Disability Status Score (EDSS) was available in 71 patients (99%). The median score was 3.0 ranging from 0.0-8.5 and 82% had  $\text{EDSS} \leq 5.5$ . EDSS shows no correlation neither with the location of attacks nor the sex of the patients, but a mild to moderate positive correlation with the number of attacks (Figure 1).

**Table 5: Number of studies fulfilling the Mc Donald's MRI criteria for dissemination in space**

McDonald criteria	Brain+spine MRI	Brain MRI	Spinal MRI	Total
Fulfilled	4	2	0	6
Not fulfilled	6	9	4	19
Total	10	11	4	25



**Figure:** Spearman's correlation showed mild to moderate correlation ( $.25 < .333 < .5$ ) between EDSS and number of attacks

## DISCUSSION

Our data confirmed the various differences in Asian as compared to MS in the Western countries. The number of MS patients in this referral university centre serving a large population confirmed the relatively low prevalence of MS among Asians.<sup>1-10</sup> However, when compare to the early case series from Thailand, 2-3 folds increase in number of MS patients was noticeable.<sup>18-20</sup> This apparent increase could reflect an increase in disease awareness, particularly when applying MRI as a diagnostic tool, although a genuine increase in the prevalence of MS cannot be excluded.

In this study, the female to male sex ratio was 6.2:1, higher than 2-3:1 in Western populations.<sup>1,2,21</sup> Similar to other reports of Asian MS, patients with lesions confined to the optic nerve and spinal cord were more common among our patients. On the other hand, unlike in Western countries, cerebellar involvement was relatively rare. In Japan, however, the proportion of patients diagnosed clinically as classic type MS is continuously increasing.<sup>22-23</sup> Chronic progressive disease course among our patients was also rare. No patient with primary progressive MS was found. Secondary progressive MS comprised only 1% of our patients, compared with 40-70% in Caucasian populations.<sup>4,21</sup> None of our patients has reported MS among their family members.

In our study, simultaneous or almost simultaneous optic neuritis in both eyes were common initial presentation occurring

in 19% of patients. This was different from findings in the Optic Neuritis Treatment Trial from North America, where almost all of the patients presented with unilateral optic neuritis.<sup>24,25</sup> Some of our patients fulfill the diagnostic criteria for Devic's neuromyelitis optica according to Wingerchuk et al<sup>26</sup> Paroxysmal tonic spasm was found in 35% of our patients. This is consistent with the common involvement of the spinal cord where all but one patient had myelitis. This high incidence is similar to other reports from Asian MS patients where paroxysmal tonic spasm may be the only clinical evidence of spinal cord involvement.<sup>18-19,27</sup>

Our MRI findings confirmed some distinct characteristics of Asian MS. The spinal cord involvement is common particularly in the cervical region. Almost two-thirds (62%) of cases had a lesion involving more than 2 vertebral body segments. Furthermore, swelling and atrophy of the involved segment were also common. These findings suggest a more severe disease in our population.<sup>10,11,28-30</sup> Typical MRI brain lesions fulfilling the Barkhof's criteria were found in a small proportion. Application of MRI criteria in McDonald's diagnostic criteria may need to be modified among Asians with MS.

Oligoclonal bands were positive in only 21% compared with 80-90% in western countries.<sup>6,7,18,31</sup> Oligoclonal bands is thus not a helpful test in the diagnosis of Asian MS with atypical presentations.

As for disability, we found mild to moderate correlation between EDSS and number of relapses suggesting that the

disability is primarily due to accumulation of the deficit incurred during relapses.

Most studies on disease modifying treatment for MS comprised of Caucasian populations.<sup>32-36</sup> Few long-term, randomized, controlled trials have been performed in Asian populations, and only beta interferon has been found to be effective in Asians with relapsing–remitting MS.<sup>36,37</sup> Optico-spinal type and classic MS patients seem to benefit equally from the medication.<sup>36</sup> There is high drop out rate in our patients who were given beta interferon, half were due to financial reason.

In conclusion, Thai patients in MS clinic, Siriraj Hospital differ from Western MS patients with no occurrence of family history, high female to male sex ratio, high incidence of bilateral optic neuritis on presentation, common occurrence of paroxysmal tonic spasm, less cerebellar involvement, rare presentation of PP-MS, more common optico-spinal form, longer spinal MRI lesions, fewer brain MRI abnormalities, and lower incidence of positive CSF oligoclonal bands.

#### ACKNOWLEDGEMENTS

This study would not be possible without the contribution from the patients and their doctors who kindly referred the patients to our service. We are greatly in debt for the expert assistance from our colleagues at Siriraj Hospital, particularly Associate Professor Orasa Chawalparit, our neuroradiologists and Associate Professor Wanicha Chuenkongkaew, our ophthalmologist. Special thanks to Mr. Leatchai Wachirutmanggur, Ms. Nopwan Sivasariyanonds for the CSF laboratory data and Ms. Panissara Tarunophas for her secretarial assistance.

#### REFERENCES

- Compston A, Coles A. Multiple sclerosis. *Lancet*. 2002; 359: 1221-31.
- Noseworthy JH, Lucchinetti C, Rodriguez M, Weinshenker BG. Multiple sclerosis. *N Eng J Med*. 2000; 343: 938-52.
- Weinshenker BG. Natural history of multiple sclerosis. *Ann Neurol*. 1994; 36(Suppl): S6-11.
- Lublin FD, Reingold SC. Defining the clinical course of multiple sclerosis: results of international survey. National Multiple Sclerosis Society (USA) Advisory Committee on Clinical Trials of New Agents in Multiple Sclerosis. *Neurology*. 1996; 46: 907-11.
- Shibasaki H, McDonald WI, Kuroiwa Y. Racial modification of clinical picture of multiple sclerosis. *J Neurol Sci*. 1981; 49: 253-71.
- Li PCK, Ong B, Lee KH, Prayoonwivat N, Tan CT, Tsai CP. Asia Pacific multiple sclerosis consensus. *Neurol J Southeast Asia*. 1999; 4: 89-90.
- Kira J, Kanai T, Nishimura Y, et al. Western versus Asian types of multiple sclerosis: Immunogenetically and clinically distinct disorders. *Ann Neurol*. 1996; 40: 569-74.
- Kuroiwa Y, Hung TP, Landsborough D, Park CS, Singhal BS. Multiple sclerosis in Asia. *Neurology*. 1997; 27: 188-92.
- Tan CT, Chong HT. Devic's disease and multiple sclerosis in Asia. *Neurol J Southeast Asia*. 1999; 4: 57-9.
- Chong HT, Li PCK, Ong B, Lee KH, Tsai CP, Singhal BS, Prayoonwivat N, Tan CT. Severe spinal cord involvement is a universal feature of Asians with multiple sclerosis: A joint Asian study. *Neurol J Southeast Asia*. 2002; 7: 35-40.
- Barkhof F, Filippi M, Miller DH. Comparison of MR imaging criteria at first presentation to predict conversion to clinically definite MS. *Brain*. 1997; 120: 2059-69.
- McDonald WI, Alistair C. Recommended diagnostic criteria for multiple sclerosis Guideline from the International Panel on the Diagnosis of Multiple Sclerosis. *Ann Neurol*. 2001; 50: 121- 7.
- Poser CM, Paty PW, Scheinberg L. New diagnostic criteria for multiple sclerosis: guideline for research protocols. *Ann Neurol*. 1983; 13: 227-31.
- Fukazawa T, Kikuchi S, Niino M, Yabe I, Hamada T, Tashiro K. Multiphasic demyelinating disorder with acute transverse myelitis in Japanese. *J Neurol*. 2003; 250: 624-6.
- Kim KK. Idiopathic recurrent transverse myelitis. *Arch Neurol*. 2003; 60: 1290-4.
- Kuroiwa Y. Neuromyelitis optica (Devic's disease, Devic's syndrome). In: Koetsier JC, ed: *Handbook of Clinical Neurology Vol 3 (47): Demyelinating disease*. Elsevier Science Publishers B.V. 1985:397-408.
- Kurtzke JE. Rating neurological impairment in multiple sclerosis and expanded disability status scale (EDSS). *Neurology*. 1983; 33: 1444-52.
- Vejjajiva A. Some aspects of multiple sclerosis in Thai patients. In Kuroiwa Y, Kurland LT, eds: *Multiple Sclerosis East and West*. Fukuoka: Kyushu University Press. 1982: 117-21.
- Jitpimolmard S, Vejjajiva A. Clinical features and clinical course of multiple sclerosis in Thai patients: a report of 50 cases. *J Med Assoc Thai*. 1994; 77: 239-43.
- Vejjajiva A. Multiple sclerosis in Thailand. *Neurol J Southeast Asia*. 1997; 2: 7-10.
- Baun HM, Rothschild BB. The incidence and prevalence and the risk of relapse in multiple sclerosis. *N Eng J Med*. 2001; 344: 319-26.
- Kira J. Multiple sclerosis in the Japanese population. *Lancet Neurol*. 2003; 2: 117-27.
- Misu T, Fujihara K, Nakashima I. Pure optic-spinal form of multiple sclerosis in Japan. *Brain*. 2002; 125: 2460-8.
- Optic Neuritis Study Group: Visual function 5 years after optic neuritis. experience of the optic neuritis treatment trial. *Arch Ophthalmol*. 1997; 115: 1545-52.
- Optic Neuritis Study Group: The 5 years risk of MS after optic neuritis. experience of the optic neuritis treatment trial. *Neurology*. 1997; 49: 1404-13.
- Weinshenker BG. Neuromyelitis optica: What it is and what it might be. *Lancet*. 2003; 361: 889-90.
- Shibasaki H, Kuroiwa Y. Painful tonic seizure in multiple sclerosis. *Arch Neurol*. 1974; 30: 47-51.
- Francis GS, Evans AC, Arnold DL. Neuroimaging in multiple sclerosis. *Neurol Clin*. 1995; 13: 147-71.
- Tintore M, Rovira A, Marty ´nez M J, et al. Isolated demyelinating syndromes: Comparison of different imaging criteria to predict conversion to clinically definite MS. *Am J Radiology*. 2000; 21: 702-6.
- Chong HT, Ramli N, Lee KH, et al. Magnetic resonance imaging of Asians with multiple sclerosis was similar to that of the West. *Neurol Asia*. 2004; 9: 47-53.
- Nakashima I, Fujihara K, Misu T, Fujimori J, Sato S. A comparative study of Japanese multiple sclerosis patients with and without oligoclonal IgG bands. *Mult Scler*. 2002; 8: 459-62.
- Jacobs LD, Cookfair DL, Rudick RA. Intramuscular interferon beta-1a for disease progression in relapsing multiple sclerosis. The Multiple Sclerosis Collaborative Research Group (MSCRG). *Ann Neurol*. 1996; 39: 285-94.
- PRISMS Study Group and the University of British Columbia MS/MRI Analysis Group: Long term efficacy of interferon beta-1a in relapsing remitting multiple sclerosis. *Neurology*. 2001; 56: 1628-36.
- PRISMS Study Group. Randomised double-blind placebo-controlled study of interferon beta-1a in relapsing remitting multiple sclerosis. *Lancet*. 1998; 352: 1498-504.
- Goodin DS, Frohman EM, Garmany GP, et al. Disease modifying therapies in multiple sclerosis. *Neurology*. 2002; 58: 169-78.
- Saida T, Tashiro K, Itoyama Y, et al. Interferon beta-1b is effective in Japanese RRMS patients: a randomized, multicenter study. *Neurology*. 2005; 64: 621-30.
- Ashtari F, Chitsaz A, Khorvash F, Shaygannejad V. Efficacy of interferon beta-1a in Iranian multiple sclerosis. *Neurol Asia*. 2005; 10: 109-12.