

Endemic echinostome infections of candidate hosts

N.E. Davis*

Department of Zoology, University of Otago, PO Box 56, Dunedin,
New Zealand

Abstract

Wild *Lymnaea tomentosa* snails, recovered from Lake Wanaka, New Zealand, were established in the laboratory. Wild snails, naturally infected with echinostomes, provided metacercariae for infection of laboratory maintained snails. Metacercarial cysts from wild and laboratory snails were then used to attempt infection of definitive host candidates. Laboratory snails provided convenient packaging of known numbers of cysts. Metacercariae excysted in the small intestines of ducklings to mature in 6 days. Worms were expelled as they became gravid. Attempts to establish infections in experimental hosts other than ducklings were not successful. No worms were recovered from mice, white rats, guinea pigs, hamsters or immunosuppressed white rats.

Introduction

Echinostomes are hermaphroditic digenean parasites found worldwide in avian and mammalian definitive hosts. The number of collar-spines, indicating a particular genus, varies from 21 to 51. Huffman & Fried (1990) indicated that the 37-collar-spined species were studied most intensively. Routine maintenance of *Echinostoma caproni*, *Echinostoma revolutum* and *Echinostoma trivolvis* is possible in the domestic chick, golden hamster and laboratory mouse (Christensen *et al.*, 1980; Fried, 1985; Franco *et al.*, 1986; Fried *et al.*, 1988; Hosier *et al.*, 1988; Mucha *et al.*, 1990). Ducklings may be worth investigating because ducks, economically important as a food and game animal, are naturally infected with echinostomes, and both wild and domestic ducks may be a natural source of cercarial dermatitis (Fried & Sousa, 1990). A suitable laboratory definitive host is required to establish and maintain one of the wild echinostome species from Lake Wanaka.

Each echinostome species has its preferred hosts (Huffman & Fried, 1990). Their eggs are passed with host faeces into the water. Embryonation depends on environmental temperature. Miracidia hatch and seek out their snail hosts. They penetrate the snail in the head-foot region and transform into mother sporocysts

in the heart (primary infection). Mother sporocysts produce mother rediae which migrate from the heart and produce numerous daughter rediae in the digestive gland–gonad complex. Daughter rediae produce cercariae which either encyst in the original host snail or emerge to seek one of several different species of snail or tadpole as a secondary intermediate host (secondary infection). Cercariae enter these hosts, shed their tails and encyst as metacercarial cysts. Definitive host infection occurs when the intermediate hosts are eaten and metacercarial cysts excyst in the small intestine. Juvenile worms attach themselves to the intestinal mucosa where they mature in 6–8 days when egg production begins and continues until the worms are eventually expelled.

Metacercarial cysts harvested from primary or secondary infected wild or laboratory snails may be fed to candidate hosts (Fried *et al.*, 1995; Schmidt & Fried, 1996). Infection success may be determined by finding viable echinostome eggs in the host faeces. Selection of a particular parasite species for maintenance in the laboratory may then be made by selecting adult worms and harvesting their eggs for incubation, hatching and infection of laboratory snails. Successfully infected animals could then be maintained as a source of sufficient numbers of echinostome eggs for further studies.

The purpose of this research was to establish an endemic echinostome in a suitable laboratory definitive host for further study.

*Fax: +64 3 689 7867
E-mail: davisn@extra.co.nz

Materials and methods

Laboratory maintenance of host snails

Lymnaea tomentosa snails taken from Lake Wanaka (Davis, 1998) were placed individually in flat-bottomed glass tubes (25 mm of lake water) with pierced polythene closures to prevent escape. They were then placed on a bench incubator (21°C) under a 40 W incandescent light to induce shedding of cercariae. Snails that did not shed cercariae within a day were maintained two each per 21 plastic container with 1.8 l of stream or lake water plus a few strands of lake weed at room temperature (15–17°C) and fed a pinch (~1 g) of oven-dried lettuce. Water was changed every 4 to 7 days by washing container contents through a simple kitchen strainer to recover snails and weed. Container waterlines were cleaned of surface film by wiping with a paper towel dampened with a commercial disinfectant (SAVLON, 10% dilution in distilled water). Containers were rinsed twice and then filled with clean water. Algal growth below the waterline was allowed to remain as a supplementary food source. Snails and weed were then replaced. Fifteen, 30 and 45 days later, surviving snails were again induced to shed cercariae. Uninfected snails were maintained in the laboratory for future experiments. Snail eggs and weed to which they were attached were placed in separate containers maintained as above. As they hatched, juvenile snails were transferred six to a container for 2 weeks and then two to a container for maintenance.

Infection of snails with echinostome cercariae

Cercariae shed by wild snails were captured by pipette and placed into flat-bottomed glass tubes with individual snails and water as above to infect them with metacercarial cysts. These snails, with known numbers of cysts, were maintained for feeding to definitive host candidates. Metacercarial cysts were also dissected from wild snails and used to infect candidate hosts.

Maintenance and challenge infection of candidate definitive hosts

Animals (ducklings, chicks, mice, white rats, guinea pigs and hamsters) were maintained in plastic animal containers on commercial coccidiostat-free turkey mash. Ducklings and chicks were transferred to large sheltered poultry enclosures as they outgrew their containers. They were fed metacercarial cysts in water or 3% NaHCO₃ per os (dropper), and their faeces were investigated daily for echinostome eggs by sedimentation from day 7 p.i. for several weeks. They were then necropsied (cervical dislocation or decapitation) and examined for adult worms. The small and large intestine and caecae were placed in warm saline (21°C), cut into equal parts, slit lengthwise, and inspected for excysted live trematodes.

When no eggs or adult worms were found, day-old ducklings were challenged using four cyst packaging techniques to improve chances of infection: (i) live primary infected or secondary infected wild snails; (ii) cysts placed in snail shells within gelatin capsules; (iii) live laboratory snails with known numbers of cysts; (iv) cysts wrapped

in damp filter paper placed within gelatin capsules. Ducklings challenged in this manner were necropsied 1 day p.i. to determine if the cysts were, in fact, excysting. Ducklings were then fed 500 cysts each by method (iii) above and investigated at 24 h intervals p.i. to determine the fate of excysted worms.

Four Wistar rats, 12 weeks old, maintained aseptically, were injected subcutaneously daily with phosphated dexamethasone (0.26 mg kg⁻¹), an immunosuppressant, from 2 weeks prior to infection to 20 days p.i. Crushed infected laboratory snails (13 ± 3 cysts each) in water were administered by stomach tube. One rat received 13 ± 3 cysts, two rats received 26 ± 6 cysts each and one rat received 39 ± 9 cysts. Commencing with the 8th day post-infection and continuing for 10 days, 24 h faecal samples from all four rats were investigated for evidence of parasite eggs. Rats were then given a second challenge dose of 40 ± 4 cysts each followed 24 and 48 h later by necropsy and examination of the intestines for excysted worms.

Treatment of echinostome specimens

Worms were fixed in hot (80°C) AFA (85 parts 85% alcohol, 10 parts formalin, 5 parts glacial acetic acid solution) for 30 min and stored in 70% ethanol. Specimens in 70% ethanol were then placed in dilute Semichon's acetic carmine overnight at room temperature. They were differentiated in acid alcohol (1% HCl in 70% ethanol) under a binocular microscope, and dehydrated by placing in 85% ethanol for 30 min followed by three changes of 30 min duration in 100% ethanol. Worms were examined in cedar oil, rinsed in xylene and mounted in D.P.X. (Gurr - BDH). Specimens stored in 70% ethanol were also taken through decreasing concentrations of ethanol to distilled water prior to staining with Lillie-Mayer acid haemalum, diluted with 20 parts potassium alum for progressive staining. They were stained overnight at room temperature. Excess stain was rinsed off in several changes of 35% ethanol, and the specimens were then placed for at least an hour each in concentrations of 50% and then 70% ethanol. Differentiation followed in acid alcohol (1% HCl in 70% ethanol). The differentiation process was stopped by transfer briefly to alkaline alcohol (0.25 ml ammonium hydroxide in 250 ml 70% ethanol). Dehydration and mounting was accomplished as for carmine staining.

For scanning electron microscope work, worms were fixed in 5% glutaraldehyde (EM grade) for several weeks, dehydrated through a graded ethanol series: 35% through to 95%, 4 h or more in each, then into 100% ethanol, three changes over 24 h. Worms were critical-point dried directly from ethanol via liquid carbon dioxide in a Polaron E3000 apparatus. Dried specimens were mounted on aluminium stubs with double-sided cellulose tape. Where possible, a fillet of balsa cement (Humbrol) was added to ensure good support and a proper foundation for earth return. Specimens were coated with gold (Polaron E5100 Sputter coater) and examined using a Cambridge Stereoscan S360.

Results

Wild snails were found with echinostome primary infections of 10 to 100 rediae and > 500 cysts each. One snail was found with > 300 rediae and 3000 metacercarial

cysts. Snails with purely secondary infections harboured from 1 to 20 cysts – most had 5 cysts. Primary infected snails were a source of cercariae for establishing metacercarial cysts in laboratory snails.

Exposure of snails (in four different size groups ranging from 3.0 mm to 4.9 mm) to 20 ± 2 cercariae each (table 1) resulted in the establishment of 16 ± 3 cysts (80%). Snail size appeared not to be a factor in cyst establishment at this challenge level.

Experimental infections of ducklings were marginally successful. The administration of live infected wild (cyst number estimated at 500+ by inspection) or laboratory snails (cyst number estimated based on cercarial challenge) was more practical than the administration of cysts placed in snail shells and capsules (fig. 1). Consequently, all subsequent attempts at infection used live laboratory infected snails for cyst delivery.

Necropsy of ducklings following challenge with snails infected with 500 cysts resulted in 100 echinostomes on day 1 p.i., decreasing to zero by day 7 p.i. (fig. 2).

Challenge cyst diameter was either $147 \mu\text{m}$ and/or $110 \mu\text{m}$. Echinostomes (figs 3 and 4), tentatively identified as *Echinoparyphium recurvatum*, were found throughout the length of the small intestine one day p.i. Thirty two worms were found throughout the small intestine 2 days p.i. One worm was found in the mid small intestine and 14 in the lower small intestine 3 days p.i. Thirteen worms were found in the lower small intestine 4 days p.i. No worms were found on day 5 p.i. Four gravid adult worms were found in the lower small intestine 6 days post-infection. The gravid worms were 8 mm long and had approximately 25 eggs each *in utero*. No worms were found on day 7 or day 8 p.i. Further attempts at infecting 12 ducklings resulted in only two ducklings being infected. A total of 85 eggs ($98.3 \mu\text{m} \times 68.8 \mu\text{m}$) were recovered from daily faecal samples over a period of one month.

Attempts to establish infections in candidate experimental hosts other than ducklings were not successful. One excysted 1 day-old worm was recovered from one of 60 challenged chicks. No worms were recovered from mice, white rats, guinea pigs, hamsters or immunosuppressed Wistar rats.

Discussion

Metacercarial cysts of two echinostome species (37- and 45-collar-spined) were found in wild *L. tomentosa* snails from Lake Wanaka. Infections were often mixed and metacercariae moved within each cyst, making the sorting of individual cysts by collar-spine count impractical. Selection for a particular parasite species was intended following successful recovery of gravid adult worms from

Table 1. Echinostome secondary infection of *Lymnaea tomentosa* when challenged with 20 ± 2 echinostome cercariae.

Snail size (mm)	Number of snails	Mean no. of cysts per snail (\pm SE)
3.0–3.4	10	15.60 (0.86)
3.5–3.9	24	15.96 (0.60)
4.0–4.4	24	15.67 (0.64)
4.5–5.0	3	16.00 (2.08)

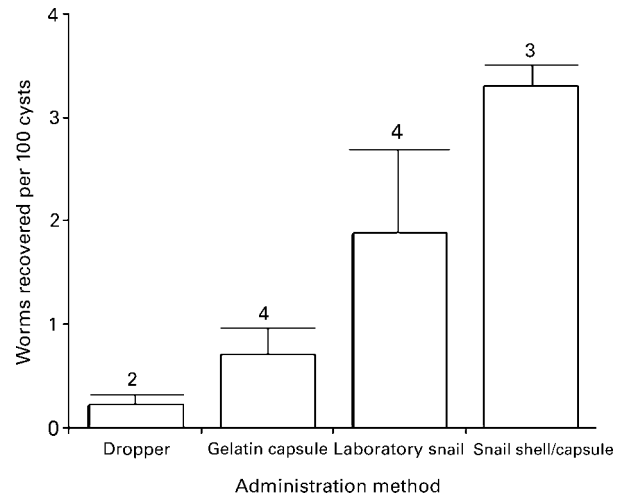


Fig. 1. Laboratory infection of ducklings, number of echinostomes recovered per duckling 1 day post-infection per 100 cysts administered by method indicated. T-bars indicate standard error. Numerals are duckling numbers.

experimental laboratory hosts. When feeding live infected wild snails to candidate hosts, estimation of cyst number was difficult due to the opacity of the snail viscera. Host candidates were challenged with laboratory snails (size range 3–5 mm) that had each been infected with known numbers of cercariae, allowing an accurate estimation of cyst numbers.

The establishment of Lake Wanaka echinostomes in ducklings was enhanced by packaging. Live laboratory snails infected with known numbers of echinostome cercariae provided natural packaging and an accurate challenge dose. These secondary infected snails were maintained in the laboratory until required. While some adult echinostomes were recovered from ducklings, very few hosts were infected and too few eggs were recovered from faeces to support further studies.

The size of the echinostome eggs ($98.3 \mu\text{m} \times 68.8 \mu\text{m}$) agrees with dimensions of eggs identified by Beaver (1937) as *Echinostoma revolutum*, but is also within the range of both *E. revolutum* and *E. recurvatum* as reported by Moravec *et al.* (1974), Kanev (1994) and Kanev *et al.* (1994).

Daily necropsy of ducklings for 8 days following challenge with 500+ metacercarial cysts in live snails showed that worms were excysting in the upper small intestine, moving to the lower small intestine and lasting no longer than 6 days in the host. Worms were expelled as they became gravid. The adult species found may be either *Echinoparyphium recurvatum* or *Echinoparyphium cinctum* (1. Kanev, personal communication).

The limited success in establishing the parasite in a laboratory definitive host prompted the decision to attempt host immunosuppression. The immunosuppressant dexamethasone (Yang & Healey, 1993) has a similar action to cyclosporin-A. Cyclosporin-A suppresses egg production of schistosome parasites in experimentally infected laboratory animals, and has an anthelmintic effect against tapeworms and roundworms in mice (Bolas-Fernandez *et al.*, 1988). While no experimental work has been done with immunosuppressants and

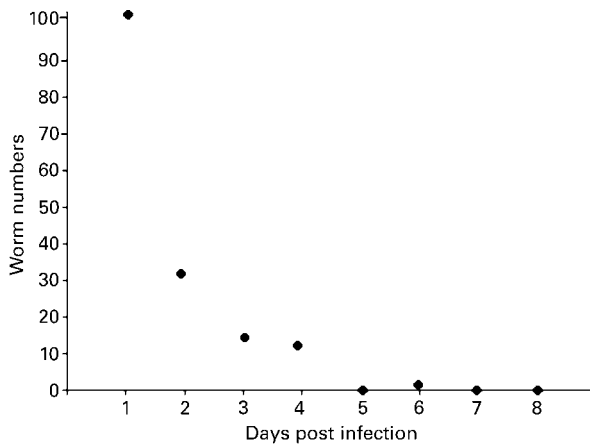


Fig. 2. Daily decline in excysted echinostome numbers in the intestines of domestic ducks following a challenge infection of 500 metacercarial cysts (day 0). Ducklings were necropsied on indicated days post-infection (six on day 6 and one on days 1–5, 7 and 8). Gravid worms were found on day 6. Standard error for 6 ducks on day 6 is ± 4 (within dot size).

echinostomes in Wistar rats, it was possible that dexamethasone would suppress egg production in established echinostomes or prevent the establishment of an experimental infection in the first place. If dexamethasone acts only to suppress egg production in established echinostomes, non-ovigerous 8 + mm long adult worms as well as recently excysted juveniles (superinfection) should have been found in the small intestine at necropsy. If dexamethasone prevents the establishment of echinostomes, no adult worms and no excysted worms from the second infection attempt would have been found. Since no worms were found, dexamethasone appears to be inappropriate for facilitating establishment of echinostome infections in Wistar rats.

Attempts to infect chicks, white rats, mice, guinea pigs and hamsters were unsuccessful. Fried & Grigo (1975) reported only a 2% infection rate in chicks following challenge with high numbers of *Echinoparyphium flexum* metacercarial cysts, and attempts to increase infectivity by treating cysts in various pretreatment solutions were unsuccessful. Howell

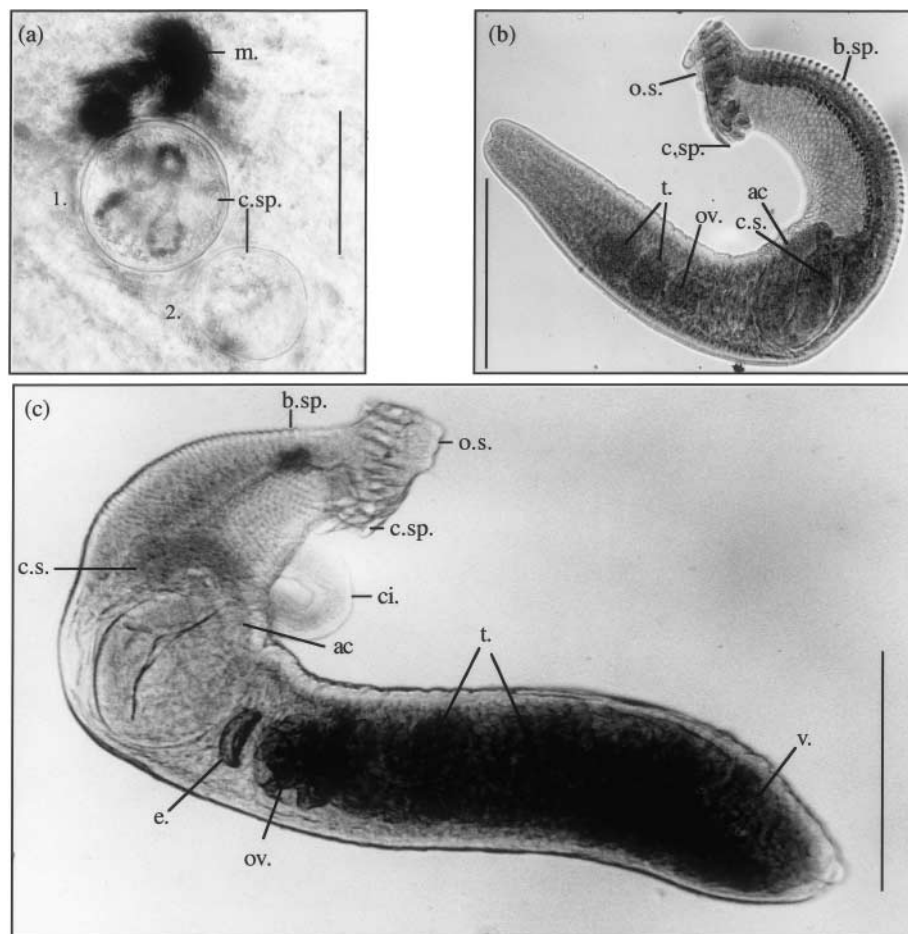


Fig. 3. Light photomicrographs of (a) two live echinostome metacercarial cysts in wild snail, (1. 147 μm cyst, 2. 110 μm cyst, bar = 145 μm .) and, (b) 4-day old juvenile worm of *Echinoparyphium* sp. from a duckling (bar = 2 mm); (c) 6-day old gravid adult worm from a duckling (bar = 2 mm). ac., acetabulum; b.sp., body spine; ci., cirrus; c.s., cirrus sac; c.sp., collar spine; e., egg; m., melanin; o.s., oral sucker; ov., ovaries; t., testes; v., vitellaria.

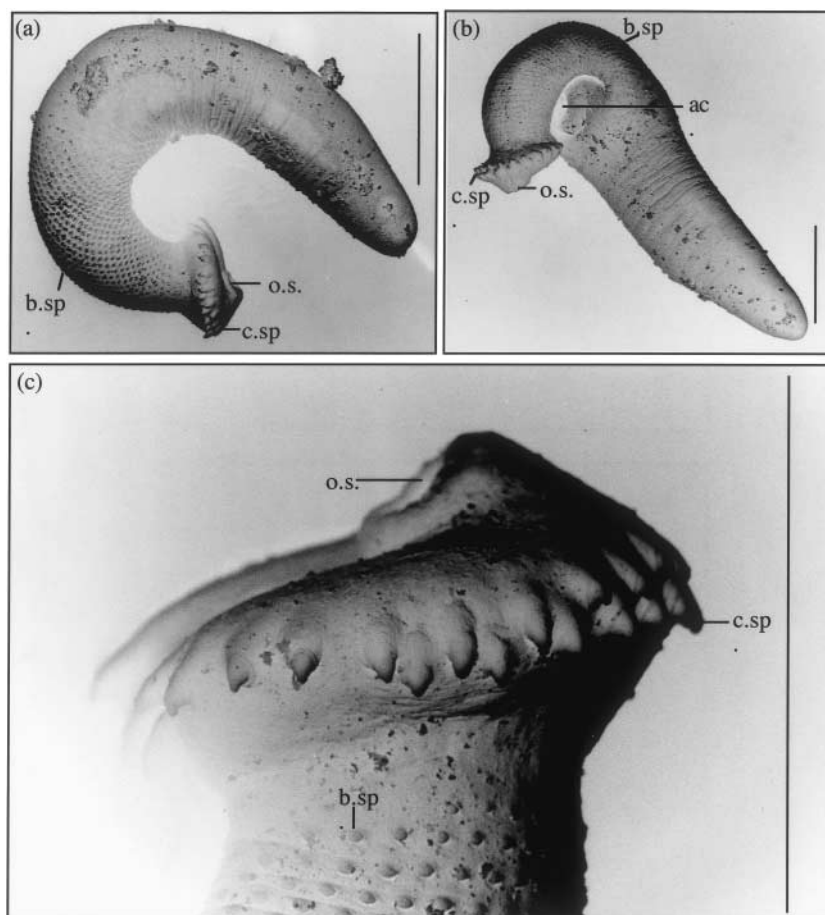


Fig. 4. Scanning electron microscope studies of a 45-collar-spined *Echinoparyphium* from ducklings experimentally infected with metacercariae from *Lymnaea tomentosa* snails experimentally infected with cercariae released by wild snails. (a) 4-day-old juvenile worm, (b) 6-day-old adult worm, (c) close up of head, showing collar spines and body spines. ac., acetabulum; b.sp., body spine; c.sp., collar spine; o.s., oral sucker. Bars = 2 mm.

(1968) reported success infecting ducklings with metacercariae of *Echinoparyphium serratum*, however only 1–3% of metacercariae fed to chickens became established and reached maturity. Budgerigars, white rats and white mice proved refractory.

None of the animals selected appear to be appropriate laboratory hosts for echinostomes endemic to Lake Wanaka. Consequently, a survey of waterfowl was planned to find a natural host and to recover adult 37-collar-spined echinostomes to harvest their eggs for further studies (Davis, 2000).

Acknowledgements

The author wishes to thank Annette Davis, Guy Davis, Mr Ken Miller, Dr Stuart Mitchell, Mr Chas Morris, Mr Dave Murphy, Dr Robert Poulin, Mr Stuart Thorne, Dr David Wharton, and Mr Phil Wilson for their support and assistance. This research was supported in part by grants from the Queenstown Lakes District Council and the New Zealand Lotteries Board.

References

- Beaver, P.C. (1937) Experimental studies on *Echinostoma revolutum* (Froelich), a fluke from birds and mammals. *Illinois Biological Monographs* **15**, 1–96.
- Bolas-Fernandez, F., Grecis, R.K. & Wakelin, D. (1988) Cyclosporin A and *Trichinella spiralis*: anthelmintic effects in immunosuppressed mice. *Parasite Immunology* **10**, 111–116.
- Christensen, N.Ø., Frandsen, F. & Roushdy, M.Z. (1980) The influence of environmental conditions and parasite-intermediate host-related factors on the transmission of *Echinostoma liei*. *Zeitschrift für Parasitenkunde* **63**, 47–63.
- Davis, N.E. (1998) Population dynamics and larval trematode interactions with *Lymnaea tomentosa* and the potential for biological control of schistosome dermatitis in Bremner Bay, Lake Wanaka, New Zealand. *Journal of Helminthology* **72**, 319–324.
- Davis, N.E. (2000) Cercarial dermatitis and the possibility of biological control in Lake Wanaka, New Zealand. A thesis submitted for the degree of Doctor

- of Philosophy at the University of Otago, Dunedin, New Zealand. Unpublished.
- Franco, J., Huffman, J. & Fried, B.** (1986) Infectivity, growth, and development of *Echinostoma revolutum* (Digenea: Echinostomatidae) in the golden hamster, *Mesocricetus auratus*. *Journal of Parasitology* **72**, 142–147.
- Fried, B.** (1985) Maintenance of *Echinostoma revolutum* (Trematoda) in the laboratory. *Proceedings of the Pennsylvania Academy of Science* **59**, 27–28.
- Fried, B. & Grigo, K.L.** (1975) Infectivity and excystation of the metacercariae of *Echinoparyphium flexum* (Trematoda). *Proceedings of the Pennsylvania Academy of Science* **49**, 79–81.
- Fried, B. & Sousa, K.R.** (1990) Single- and five-worm infections of *Echinostoma caproni* (Trematoda) in the ICR mouse. *International Journal for Parasitology* **20**, 125–126.
- Fried, B., Huffman, J. & Franco, J.** (1988) Single- and five-worm infections of *Echinostoma revolutum* (Trematoda) in the golden hamster. *International Journal for Parasitology* **18**, 179–181.
- Fried, B., Idris, N. & Ohsawa, T.** (1995) Experimental infection of juvenile *Biomphalaria glabrata* with cercariae of *Echinostoma trivolvis*. *Journal of Parasitology* **81**, 308–310.
- Hosier, D., Fried, B. & Szewczak, J.P.** (1988) Homologous and heterologous resistance of *Echinostoma revolutum* and *E. liei* in ICR mice. *Journal of Parasitology* **74**, 89–92.
- Howell, M.J.** (1968) The life-cycle of *Echinoparyphium serratum* sp. nov. (Digenea: Echinostomatidae). *Parasitology* **58**, 573–582.
- Huffman, J.E. & Fried, B.** (1990) *Echinostoma* and echinostomiasis. *Advances in Parasitology* **29**, 215–267.
- Kanev, I.** (1994) Life-cycle, delimitation and redescription of *Echinostoma revolutum* (Froelich, 1802) (Trematoda: Echinostomatidae). *Systematic Parasitology* **28**, 125–144.
- Kanev, I., Radev, V., Vassilev, I., Dimitrov, V. & Minchella, D.** (1994) The life cycle of *Echinoparyphium cinctum* (Rudolphi, 1803) (Trematoda: Echinostomatidae) with re-examination and identification of its allied species from Europe and Asia. *Helminthologia* **31**, 73–82.
- Moravec, F., Barus, V., Rysavy, B. & Yousif, F.** (1974) Observations on the development of two echinostomes, *Echinoparyphium recurvatum* and *Echinostoma revolutum*, the antagonists of human schistosomes in Egypt. *Folia Parasitologica* **21**, 107–126.
- Mucha, K.H., Huffman, J.E. & Fried, B.** (1990) Mallard ducklings (*Anas platyrhynchos*) experimentally infected with *Echinostoma trivolvis* (Digenea). *Journal of Parasitology* **76**, 590–592.
- Schmidt, K. & Fried, B.** (1996) Experimental infection of *Helisoma trivolvis* (Colorado Strain) snails with cercariae of *Echinostoma trivolvis*. *International Journal for Parasitology* **26**, 287–289.
- Yang, S. & Healey, M.C.** (1993) The immunosuppressive effects of dexamethasone administered in drinking water to C57BL/6N mice infected with *Cryptosporidium parvum*. *Journal of Parasitology* **79**, 626–630.

(Accepted 26 January 2005)
© CAB International, 2005