

GENERAL NOTES

OLD ILLUSTRATION BLOCKS

It is our custom to destroy blocks after three years. It may be that some authors would like to have their blocks for possible future use. In such case would they write Headley Brothers, Ashford, Kent, as soon as possible, and in any case within three years of their first being used.

THE attention of members is drawn to the *EXCERPTA MEDICA* Section XI which is a most valuable international abstracting service as it gives each month abstracts of all the important papers in Oto-Rhino-Laryngology. The subscription is £4 8s. od. a year and the agents for Great Britain, the Dominions and the Commonwealth (excluding Canada) are E. and S. Livingstone Ltd., 16 and 17 Teviot Place, Edinburgh. We regret that in previous issues the price was incorrectly stated as five dollars or the equivalent.

BRITISH ASSOCIATION OF OTOLARYNGOLOGISTS

ANTERIOR POLIOMYELITIS AND EAR, NOSE AND THROAT OPERATIONS

THE attention of members is drawn to the Medical Memorandum on Poliomyelitis, No. 93222/7/63, dated July, 1954, issued by the Ministry of Health and Department of Health for Scotland. The relevant passages in this report, which are of interest to Otolaryngologists, are as follows :

I. EPIDEMIOLOGY.

(a) The present evidence suggests that the portal of entry is usually the mouth and that the primary site of infection is in the mucosa of the oropharynx or the small intestine.

(b) In bulbar poliomyelitis following tonsillectomy it seems that the virus most probably travels to the medulla along the cranial nerves supplying the pharynx.

(c) It is fairly generally accepted that specific trauma, especially tonsillectomy, may precipitate paralysis.

2. CONTROL MEASURES : AVOIDANCE OF CERTAIN TRAUMA.

(a) *Tonsillectomy.* The postponement of tonsillectomy when poliomyelitis reaches unusual proportions in a locality is strongly advised, particularly because when poliomyelitis follows recent tonsillectomy, serious illness, with bulbar involvement, appears to be more frequent. The Medical Officer of

General Notes

Health can assist by informing local hospital authorities when and where the incidence of the disease is unusually high, so that the surgeon may then take this hazard into account before deciding to operate.

(b) *Tooth Extractions.* There is very little evidence that tooth extractions may predispose to bulbar poliomyelitis. Nevertheless as with ear, nose and throat surgery the possibility should be kept in mind by dentists undertaking non-urgent extractions in areas of epidemic prevalence.

THE INSTITUTE OF LARYNGOLOGY AND OTOLOGY (UNIVERSITY OF LONDON)

330-332 GRAY'S INN ROAD, LONDON, W.C.1.

COMPLETE CLINICAL COURSE (whole-time) especially suitable for D.L.O. Part II students: June 20th to November 25th, 1955. Fee £31 10s.

PRACTICAL REVISION COURSE for Part II, D.L.O. students (whole-time) June 1st to 14th and November 14th to 26th, 1955. Fee £5 5s.

BASIC SCIENCES CLASS (whole-time) for Part I, D.L.O. students, with facilities for dissection: August 29th to November 25th, 1955. Fee £21.

ADVANCED REVISION COURSE for Final F.R.C.S. students: August 8th to October 22nd, 1955. Arranged as part-time course (mostly evenings) to meet circumstances of students holding appointments. Fee £21.

Detailed syllabus obtainable from the Dean.

THE INSTITUTE OF LARYNGOLOGY AND OTOLOGY

GRAY'S INN ROAD, LONDON, W.C.1

THE ACADEMIC BOARD announces the following SPECIAL LECTURES to be given in the Lecture Hall of the Institute at Gray's Inn Road. They are open to all members of the Specialty and to post-graduate students.

Friday, October 14th, 1955. 4.30 p.m.

Annual Address. The Association of Dermatology with Oto-Rhino-laryngology. MR. F. C. W. CAPPS.

Saturday, November 5th, 1955. 11 a.m.

Presentation of Cinematograph Film in Colour Illustrating Bronchoscopy and Esophagoscopy. DR. ANDRE SOULAS, DR. DUBOIS DE MONTREYNAUD (Paris).

Wednesday, November 16th, 1955. 5.30 p.m.

Plastic Surgery of the Middle Ear. PROFESSOR F. C. ORMEROD.

Wednesday, November 30th, 1955. 5.30 p.m.

Ulcerative Granulomatous Conditions of the Nose. DR. I. FRIEDMANN.

Wednesday, December 7th, 1955. 5.30 p.m. The Surgery of Pharyngeal Carcinoma
PROFESSOR F. C. ORMEROD.

POST-TONSILLECTOMY COMFORT

Immediate pain relief—Speedier Convalescence

The pain of traumatized tissues following tonsillectomy, demands its own relief—and points the need for analgesia that quickly reaches the irritated area.

ASPERGUM provides 'salivary analgesia' through the simple act of chewing — it brings pain-relieving acetylsalicylic acid into *intimate* and *prolonged* contact with the tonsillar

region, seldom reached even intermittently by gargling. The rhythmic stimulation of muscular action also aids in relieving local spasticity & stiffness: more rapid tissue repair is promoted. Each pleasantly flavoured chewing gum tablet provides $3\frac{1}{2}$ grains acetylsalicylic acid, permitting frequent use. Particularly suitable for children.

Aspergum

for more than two decades a dependable and welcome aid to patient-comfort

Ethically promoted. Prescription bottles of 36 tablets, dispensing bottles of 250.

WHITE LABORATORIES LTD., 428, SOUTHCROFT ROAD, LONDON, S.W.16

THE LARYNGOSCOPE

A Monthly Journal
devoted to the Diseases of the
EAR, NOSE AND THROAT

*Official organ for the American Laryngological,
Rhinological and Otological Society*

Price \$14.00 per year

Canada \$13.00 per year


MAX A. GOLDSTEIN, M.D.
FOUNDER

THEODORE E. WALSH, M.D.
EDITOR

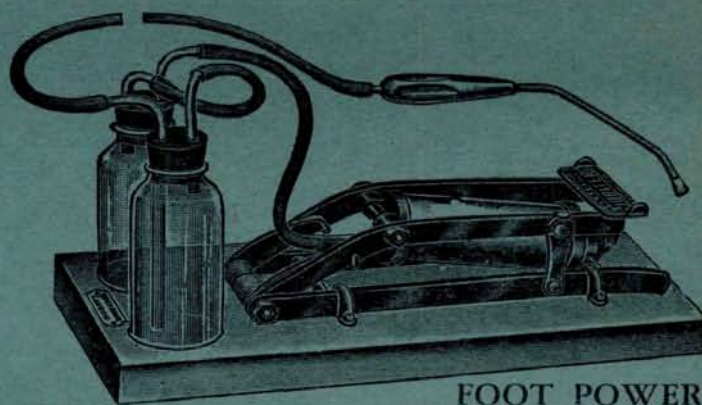
640 SOUTH KINGSHIGHWAY
SAINT LOUIS 10, MO.

Please mention *The Journal of Laryngology* when replying to advertisements

ELECTRIC 1954 model designed for use in explosion prone atmosphere.



Foot Model, in case of electric supply failure.



FOOT POWER

SUCTION APPARATUS

Particulars on application

DOWN BROS. & MAYER & PHELPS Ltd.

Head Office: 92-94 Borough High Street, London, S.E.1 HOP: 4141

Showrooms: 32-34 New Cavendish Street, London, W.1 WEL: 3764

Printed in Great Britain and published for the proprietors by
HEADLEY BROTHERS LTD 109 Kingsway London WC2 and Ashford Kent