

# Results of Proton MRS Studies in PVS and MCS Patients

*C Machado, R Rodríguez, M Carballo, J Perez, J Korein*

Can. J. Neurol. Sci. 2009; 36: 365-369

Proton magnetic resonance spectroscopy ( $^1\text{H}$ -MRS) is useful in monitoring biochemical changes in metabolic, traumatic, infectious, and oncologic disorders of the brain. N-acetyl aspartate (NAA) content is a measure of neuronal integrity, choline (Cho) content mirrors membrane turnover, and creatine (Cre) relates to energy dependent systems. A decrement of NAA concentration has been interpreted as a sign of neuronal loss or dysfunction. To reduce intra and inter-subject variability in MRS measurements, peak area ratios are also computed for, NAA/Cre and NAA/Cho. MRS may thus improve the efficiency and sensitivity of MRI, especially for the detection of functional lesions that are not visible in conventional imaging sequences.<sup>1-3</sup>

The persistent vegetative state (PVS) is one of the least understood and most ethically upsetting conditions because even modern high-technology does not restore function after brain damage. This term describes a unique condition in which patients who emerge from coma appear to be awake but show no signs of awareness. The diagnosis of PVS has been made more difficult by recognition of the minimally conscious state (MCS) as a transitional phase in the partial recovery of self-awareness or environmental awareness while a patient emerges from PVS, leading to a relative high proportion of errors.<sup>4-6</sup>

In this paper, we will describe metabolic changes assessed by MRS comparing two patients who evolved from PVS to MCS and two others who remained in PVS.

## METHODS

We studied four patients by MRS in January 2007. These patients had first been studied in our Institute in January 2005. At that time, all four fulfilled diagnostic criteria for PVS: no evidence of awareness of self or environment, no interaction with others, and no comprehension or expression of language. Often stimuli resulted in massive stretching or startle reactions, without habituation, sometimes with massive flexor responses. Occasionally grimacing followed stimulation. Nonetheless, external stimuli did not evoke purposeful or sustained and reproducible voluntary behavioral responses. Hence, we appropriately diagnosed PVS.<sup>6-8</sup>

To assess the level of consciousness in patients we used a scale described by the International Working Party on the Management of the Vegetative State (Table 1). This scale describes a comatose state, three vegetative sub-states, three non-vegetative sub-states, and a conscious state.<sup>8,9</sup>

Patients' clinical data is presented in Table 2. Patient 1 firstly had a score of 3 (PVS – reflexive state) and transited to score 6 (MCS – Inconsistent reactions); Patient 2 initially scored 3 (PVS

– Reflexive state) and changed to score 5 (MCS – Transitional state); Patient 3 first had a score of 2 (PVS – hyporesponsive) and changed to score 3 (PVS – Reflexive state); Patient 4 scored in both studies 3 (PVS – Reflexive state).

Patients were studied serially by magnetic resonance imaging (MRI) and  $^1\text{H}$ -MRS, as described elsewhere.<sup>10,11</sup> The MRI and MRS data were both obtained using a conventional 1.5 Tesla whole-body imaging system (Magnetom Symphony, Siemens Medical Systems, Erlangen, Germany). MRS was performed with the single voxel PRESS sequence provided by the manufacturer using a TE of 135 milliseconds and a TR of 1500 msec. Localized water-suppressed proton spectra were obtained using a stimulated echo acquisition mode (STEAM) sequence. Spectra were obtained from 2 x 2 x 2 cm volumes of interest (VOI) placed in cerebral cortex at the left frontal hemisphere and both thalami, and 1.5 x 1.5 x 3 cm VOI placed in the brainstem (Figure 1). These regions were selected because they are crucial for the pathophysiology of consciousness generation. Spectroscopy variables measured from  $^1\text{H}$ -MRS were N-acetyl aspartate (NAA) and creatine (Cre). Although other metabolites were also measured, we only included in this paper peak area ratios NAA/Cre.

## RESULTS

Figure 2 shows NAA/Cre changes from the first and second MRS studies in each of the four cases. A scale logarithmic transformation was applied to percent of changes to facilitate figure comprehension, which makes evident the great change of this ratio in the cortex, mainly in Patient 1 with a 788% of increment, and less but still important in Patient 2 (Figure 3), with a 205% of augmentation. Patients 3 and 4 showed NAA/Cre decrements. In the thalamus, Patients 1 and 2 showed decrement of NAA/Cre values, meanwhile Patients 3 and 4 attained augmentation of this ratio. In the brainstem Patient 2 only showed incremented values of NAA/Cre, meanwhile the three remaining cases reached a decrement of this ratio.

From the Institute of Neurology and Neurosurgery (CM), International Center for Neurological Restoration (RR, MC), Hermanos Ameijeiras Hospital (JP), Ciudad de La Habana, Cuba; Neurology (JK), New York University Medical Center, New York, NY, USA.

RECEIVED SEPTEMBER 4, 2008. FINAL REVISIONS SUBMITTED DECEMBER 11, 2008.

Correspondence to: Calixto Machado, Institute of Neurology and Neurosurgery, Apartado Postal 4268, Ciudad de La Habana, 10400, Cuba.  
Email: barind@infomed.sld.cu

**Table 1: Level of consciousness assessment scale from the International Working Party on the Management of the Vegetative State**

LEVELS OF CONSCIOUSNESS		
Global level	Score	Description of the levels
<b>COMA</b>		
	1	Eyes are closed all the time. No sleep–wake cycles present.  All major body functions such as breathing, temperature control, or blood pressure can be disturbed. Generally, no reactions are noticed after stimulation. Sometimes reflexes (stretching or flexing) can be observed as a reaction when strong pain stimuli have been applied. No other reactions present.
<b>VEGETATIVE STATE (VS)</b>		
	2	Patient has some sleep–wake cycles, but no proper day–night rhythm. Most of the body functions are normal. No further ventilation is required for respiration.  <u>Very little response (hypo-responsive)</u> Generally no response after stimulation. Sometimes delayed presentation of reflexes is observed.
	3	<u>Reflexive state</u> Often stimuli result in massive stretching or startle reactions, without proper habituation. Sometimes these reactions evaluate into massive flexing responses. Roving eye movements can be seen, without tracking. Sometimes grimacing occurs after stimulation.
	4	<u>High active level and/or reactions in stimulated body parts</u> Generally spontaneous undirected movements. Retracting a limb following stimulation. Orienting towards a stimulus, without fixating. Following moving persons or objects, without fixating.
<b>MCS</b>		
	5	Patient remains awake most of the day.  <u>Transitional state</u> Following and fixating of persons and objects. Generally more directed reactions to stimuli. Behavior is automatic, i.e. opening of the mouth when food is presented, or reaching towards persons or objects. Sometimes emotional reactions are seen such as crying or smiling towards family or to specific (known) stimuli.
	6	<u>Inconsistent reactions</u> Sometimes, but not always, obeying simple commands. Totally dependent. Patient has profound cognitive limitations; neuropsychological testing is impossible. Level of alertness is fluctuating, but in general low.
	7	<u>Consistent reactions</u> Patient obeys simple commands. The level of alertness is high and stable. Many cognitive disturbances remain. Patient is totally dependent.
<b>CONSCIOUSNESS</b>		
	8	Patient is alert and reacts to his/her environment spontaneously. Functional understandable mutual communication is possible, sometimes with technical support. As yet, cognitive and behavioral disturbances can be present.

## DISCUSSION

The mechanisms underlying the development of brain damage from all causes of hypoxic encephalopathy are complex, although resistance to anoxia among brain structures plays a fundamental role to explain the site and intensity of lesions.<sup>12,13</sup> Dubowitz et al stated that although MRI and MRS measure different aspects of hypoxia that are independent, both correlate with poor outcome in hypoxic encephalopathy.<sup>12</sup> Ricci et al reported that NAA/Cr in hypoxic encephalopathy were markedly lower than in the control subjects, in both frontal lobes.<sup>13</sup>

An important issue to consider is that in uni-voxel MRS at any brain location includes both gray and white matters.<sup>10–13</sup> Ammermann et al, studying patients who suffered from global cerebral anoxic damage caused by primary respiratory or cardiac arrest, reported that all patients exhibited cortical lesions of some

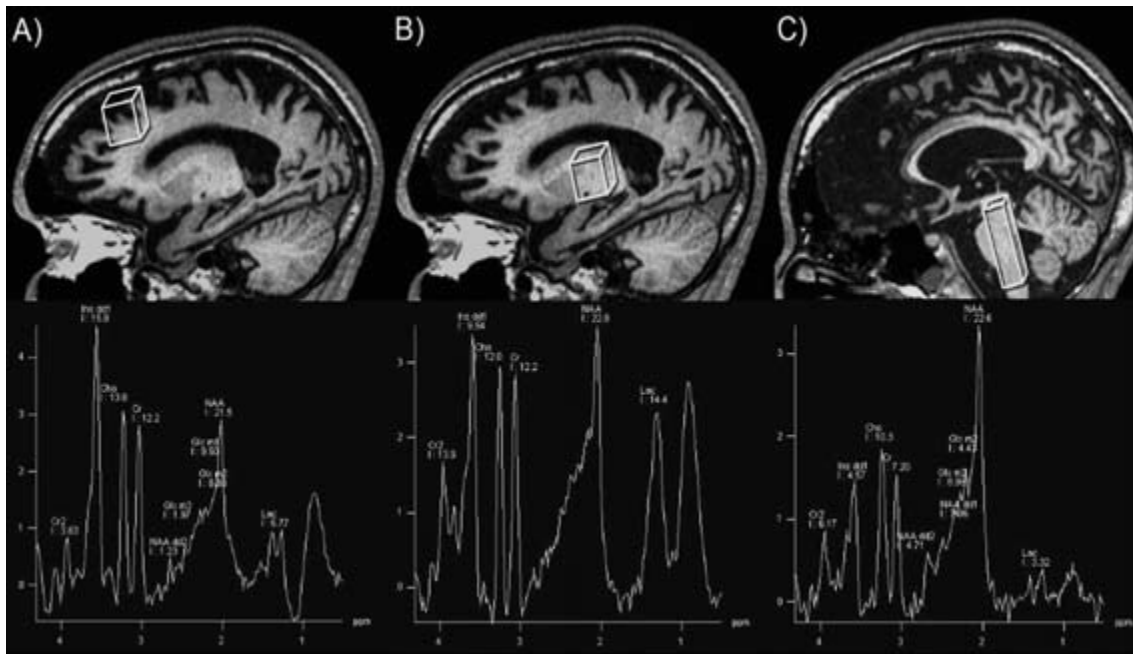
degree, generally most pronounced in the frontal and occipital lobes, and that patients with the worst outcomes showed a more widespread lesion pattern of cortical lesions.<sup>14</sup> In studies involving children, NAA and Cr in the frontal white matter correlated with performance on a working memory task.<sup>15</sup>

Our two patients who transitioned to MCS showed a decrement of the NAA/Cr ratio in the thalami, and one of them showed incremented values of NAA/Cr at the brainstem. Uzan et al reported that the NAA/Cr ratio was significantly lower in the thalami of two PVS patients who had suffered severe traumatic brain injury.<sup>16</sup> Carpentier et al reported that MRS detected severe functional damage of the brainstem in patients with normal morphological MRI.<sup>17</sup>

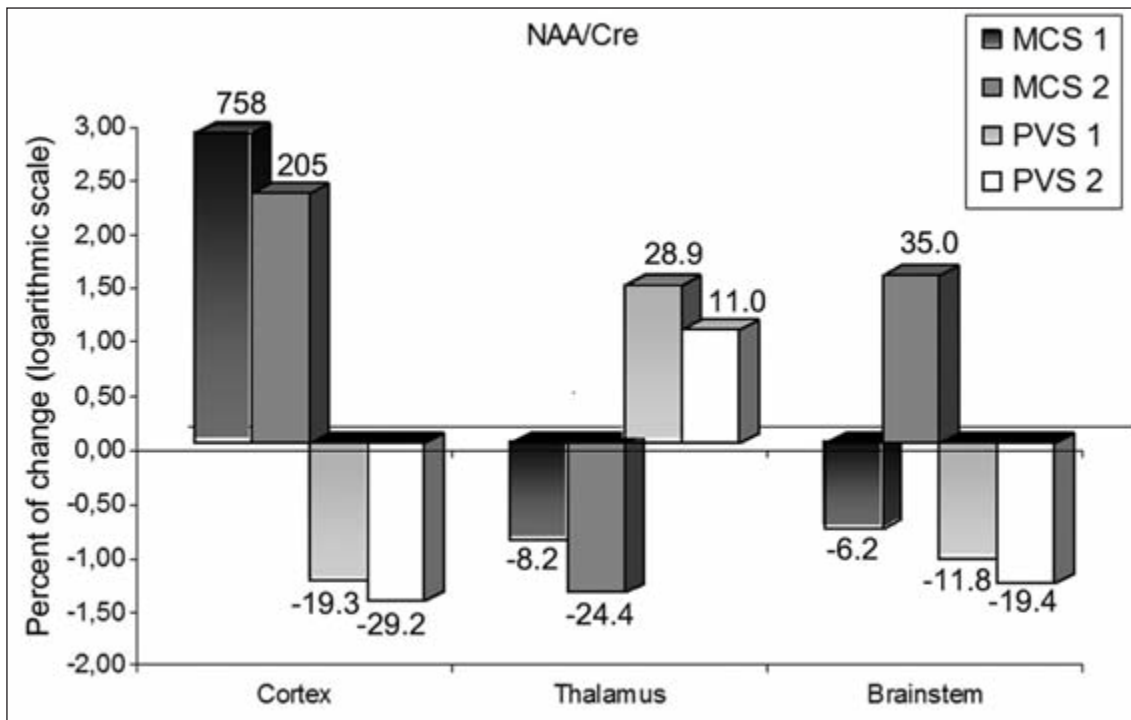
Hypoxic damage of the brain is complex and depends on several factors, such as resistance of the nervous system to anoxia at different levels of the brain, time of asystole,

**Table 2: Patient's clinical data and level of consciousness assessed by the International Working Party on the Management of the Vegetative State scale.**

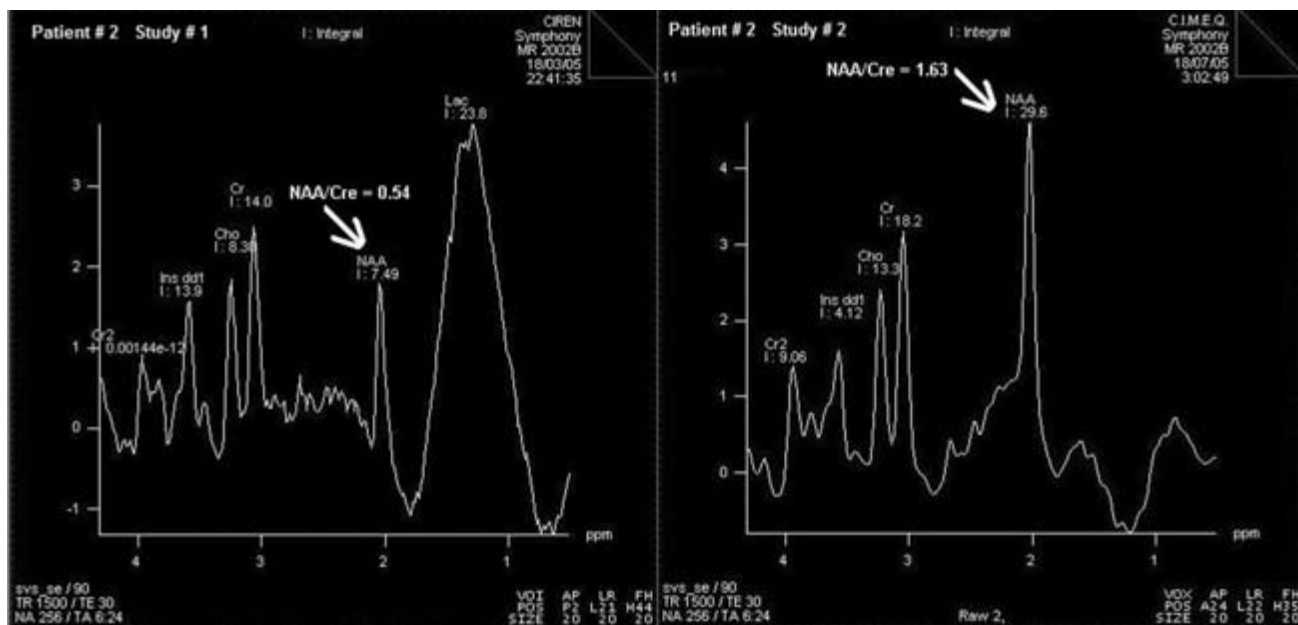
PATIENT	SEX	AGE	ETIOLOGY	CONSCIOUSNESS SCALE (STUDY 1)	CONSCIOUSNESS SCALE (STUDY 2)
1	F	28	Cardio-respiratory arrest during cesarean surgery	3	6
2	F	15	Near drowning	3	5
3	M	16	Cardio-respiratory arrest during orthopedic surgery	2	3
4	F	14	Near drowning	3	3



**Figure 1:** Spectra were obtained from 2 x 2 x 2 cm volumes of interest (VOI) placed in cerebral cortex at the left frontal hemisphere and both thalami, and 1.5 x 1.5 x 3 cm VOI placed in the brainstem. The VOI was localized in three dimensions using T1- and T2- weighted, multisection, spin-echo images.



**Figure 2:** This figure shows NAA/Cre changes among first and second MRS studies. A scale logarithmic transformation was applied to percent of changes for easing figure comprehension. Percent of changes are presented in the upper part of each column. Patient 1 shows a great increment of this ratio at the cortex (788%), the same as Patient 2 (225%). Patients 3 and 4 showed NAA/Cre decrements. At the thalami Patients 1 and 2 showed decrement of NAA/Cre values, meanwhile Patients 3 and 4 attained augmentation of this ratio. Patient 2 is the only one showing incremented values of NAA/Cre at the brainstem.



**Figure 3:** This figure compares MRS metabolites between first and second study in Patient 2. An increment of NAA occurs in the second study. Arrows indicate NAA peak values in studies # 1 and # 2. NAA/Cre ratios are also shown for each study.

effectiveness of resuscitation maneuvers, possible exposure to accidental hypothermia, etc.<sup>18</sup> Therefore, a great variety of lesions may characterize hypoxic encephalopathy. Hence, it is necessary to perform future studies including a greater sample of PVS cases who had suffered hypoxic encephalopathy, and to compare those results with other causes of brain damage, to explain our MRS findings in the brainstem and the thalami.

We believe the most important finding in our studies was the increment of the NAA/Cre ratio in the cortex in the two cases of transition of from PVS to MCS, while the pair who remained in PVS showed lower values of this MRS measure. Of course, due to our small sample of patients we were not able to apply a valid statistical analysis, but we consider that it is important to report cognitive recovery assessment in PVS cases, even in single or a few cases, as other authors have done.<sup>4,19,20</sup>

Hence, although it is necessary to carry out future studies with a larger sample of cases, MRS seems to be a useful technique to follow up cognitive recovery in PVS patients transiting to MCS.

## REFERENCES

- Rigotti DJ, Inglese M, Gonen O. Whole-brain N-acetylaspartate as a surrogate marker of neuronal damage in diffuse neurologic disorders. *AJNR Am J Neuroradiol.* 2007;28:1843-9.
- Stern AJ, Savostyanova AA, Goldman A, Barnett AS, van der Veen JW, Callicott JH, et al. Impact of the brain-derived neurotrophic factor Val66Met polymorphism on levels of hippocampal N-acetyl-aspartate assessed by magnetic resonance spectroscopic imaging at 3 Tesla. *Biol Psychiatry.* 2008;64(10):856-62.
- Yeo RA, Phillips JP, Jung RE, Brown AJ, Campbell RC, Brooks WM. Magnetic resonance spectroscopy detects brain injury and predicts cognitive functioning in children with brain injuries. *J Neurotrauma.* 2006;23(10):1427-35.
- Machado C, Korein J, Aubert E, Bosch J, Alvarez MA, Rodríguez R, et al. Recognizing a mother's voice in the persistent vegetative state. *Clin EEG Neurosci.* 2007;38(3):124-6.
- Owen AM. Disorders of consciousness. *Ann NY Acad Sci.* 2008; 1124:225-8.
- Giardino JT, Kalmar K. Diagnostic and prognostic guidelines for the vegetative and minimally conscious states. *Neuropsychol Rehabil.* 2005;15(3-4):166-74.
- Practice parameters: assessment and management of patients in the persistent vegetative state (summary statement). The Quality Standards Subcommittee of the American Academy of Neurology. *Neurology.* 1995;45(5):1015-8.
- Andrews K. International Working Party on the Management of the Vegetative State: summary report. *Brain Inj.* 1996;10:797-806.
- Wijnen VJ, van Boxtel GJ, Eilander HJ, de Gelder B. Mismatch negativity predicts recovery from the vegetative state. *Clin Neurophysiol.* 2007;118(3):597-605.
- Morales-Chacón L. Magnetic resonance spectroscopy and functional magnetic resonance images: non-invasive alternatives for identifying epileptogenic foci. *Rev Neurol.* 2001;32(3):234-6.
- Palmero Camejo R, Rodríguez Rojas R, Morales Chacón L, Carballo Barreda M, Machado Curbelo C. Espectroscopía protónica por resonancia magnética en la cirugía de la epilepsia del lóbulo temporal. Experiencia de los primeros 5 casos en Cuba. *Rev Mex Neuroc.* 2004;5(4):300-6.
- Dubowitz DJ, Bluml S, Arciniegua E, Dietrich RB. MR of hypoxic encephalopathy in children after near drowning: correlation with quantitative proton MR spectroscopy and clinical outcome. *Am J Neuroradiol.* 1998;19:1617-27.
- Ricci R, Barbarella G, Musi P, Boldrini P, Trevisan C, Basaglia N. Localised proton MR spectroscopy of brain metabolism changes in vegetative patients. *Neuroradiology.* 1997;39(5):313-9.
- Ammermann H, Kassubek J, Lotze M, Gut E, Kaps M, Schmidt J, et al. MRI brain lesion patterns in patients in anoxia-induced vegetative state. *J Neurol Sci.* 2007;260:65-70.
- Rae C, Lee MA, Dixon RM, Blamire AM, Thompson CH, Styles P, et al. Metabolic abnormalities in developmental dyslexia detected by 1H magnetic resonance spectroscopy. *Lancet.* 1998;351(9119):1849-52.

16. Uzan M, Albayram S, Dashti SG, Aydin S, Hanci M, Kaday C. Thalamic proton magnetic resonance spectroscopy in vegetative state induced by traumatic brain injury. *J Neurol Neurosurg Psychiatry*. 2003;74:33-8.
17. Carpentier A, Galanaud D, Puybasset L, Muller JC, Lescot T, Boch AL, et al. Early morphologic and spectroscopic magnetic resonance in severe traumatic brain injuries can detect "invisible brain stem damage" and predict "vegetative states". *J Neurotrauma*. 2006;23(5):674-85.
18. Safar PJ, Kochanek PM. Therapeutic hypothermia after cardiac arrest. *N Engl J Med*. 2002; 346(8):612-13.
19. Voss HU, Uluç AM, Dyke JP, Watts R, Kobylarz EJ, McCandliss BD, et al. Possible axonal regrowth in late recovery from the minimally conscious state. *J Clin Invest*. 2006; 116(7):2005-11.
20. Di HB, Yu SM, Weng XC, Laureys S, Yu D, Li JQ, et al. Cerebral response to patient's own name in the vegetative and minimally conscious states. *Neurology*. 2007;68(12):895-9.