

Dichorionic Pregnancy: Delayed Interval Delivery With Endoloop Ligation

D. Surico,¹ R. Amadori,¹ F. Ferrero,² A. Vigone,¹ L. Leo,¹ and N. Surico¹

¹Department of Obstetrics and Gynaecology, University of Eastern Piedmont, Novara, Italy

²Department of Neonatology, University of Eastern Piedmont, Novara, Italy

We describe two cases of delayed delivery in dichorionic, diamniotic pregnancies, where we used an Endoloop ligature to clamp the umbilical cord with excellent maternal and fetal long-term outcome.

■ **Keywords:** delayed interval delivery, twins, long term outcome, endoloop

The incidence of twin pregnancies has increased during the last 20 years. Preterm delivery and premature rupture of membranes of one fetus, especially in the second trimester, have become a common challenge for obstetricians worldwide. The birth of the first twin leads to the delivery of the second one contributing to perinatal mortality and morbidity: survival rates of twins are 11%, 23%, and 51% at 22–23, 24, and 25 weeks of gestation, respectively (Oleyese et al., 2005).

Despite the potential impact on perinatal outcomes, delayed delivery of one twin remains a rare event. The widest paper in literature concerns 50 cases of delayed interval delivery (DID) in twin and triplet pregnancies treated according to a four-step standard protocol (Arabin & van Eyck, 2009).

Absence of contractions, chorioamnionitis, fetal distress, congenital abnormalities, suspected placental abruption, and preterm rupture of the second twin amniotic sac are mandatory to defer the birth of the second twin. After the delivery of the first baby, the umbilical cord must be ligated as high as possible leaving the placenta in situ. This procedure is commonly carried out with a 0 suture positioned near the cervix (Kalchbrenner et al., 1998).

We describe two cases of DID in twin dichorionic, diamniotic pregnancies. In both cases, we used an Endoloop ligature (0 PDS II ligature; Ethicon Inc., Somerville, NJ) to clamp the umbilical cord as high as possible.

Case Report 1

A 27-year-old primigravid woman, who carried a diamniotic, dichorionic twin pregnancy after an in vitro fertilization procedure, was transferred to our Department for

premature membrane rupture at 24 weeks and three days of gestation. At pelvic examination, the cervix was dilated to 8 cm with protrusion of the first twin amniotic sac into the vagina.

The patient was afebrile; laboratory investigations showed white blood cell count of $24.78 \times 10^3 \mu/L$ and raised C reactive protein at 3.05 mg/dL. Computerized cardiotocography revealed normal cardiac frequency for both twins and regular contractions. Microbiological vaginal and urine cultures collected at admission were sterile. At ultrasound scan, the first twin was in breech presentation, the second one was in vertex presentation, the twins' biometry was concordant to gestational age, and there was a normal amount of amniotic fluid in the second twin sac whereas the first fetus wasn't surrounded by liquid.

Bed rest, tocolysis with intravenous atosiban and intramuscular 17-alpha-hydroxyprogesterone caproate (341 mg twice a week), and prophylactic antibiotic therapy with clarithromycin (500 mg iv bid) were initiated. Bethametasone (12 mg per day twice) was administered intramuscularly to induce fetal lung maturity. Twenty-one hours after admission, the first 550 gm female fetus was born with an Apgar score of 4 and 7 at 1 and 5 min respectively. The placenta was retained in utero. During the delivery, we didn't stop the atosiban infusion and administered antibiotic prophylaxis; episiotomy was avoided. After delivery, we took

RECEIVED 11 October 2011; ACCEPTED 1 March 2012.

ADDRESS FOR CORRESPONDENCE: Daniela Surico, Department of Obstetrics and Gynaecology, 'Maggiore della Carità' Hospital, Viale Mazzini 18, 28100, Novara, Italy. E-mail: daniela.surico@med.unipmn.it

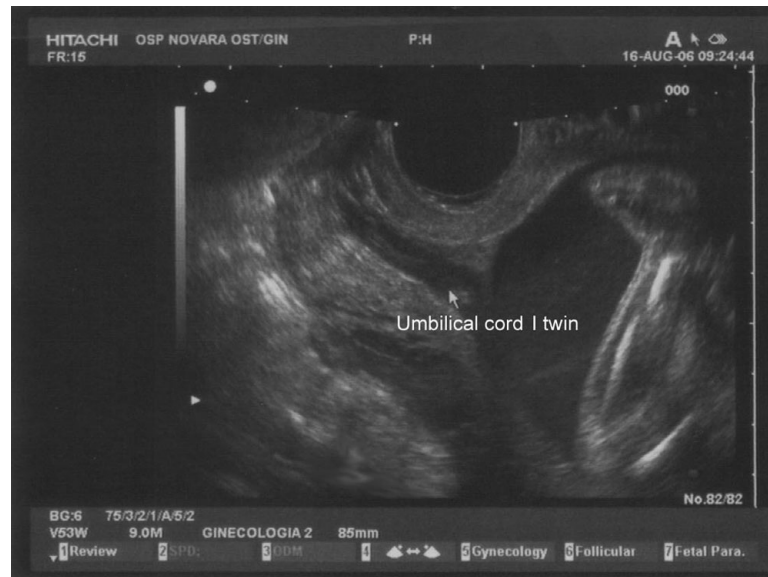

FIGURE 1

Ultrasound feature of patient 1 cervix after delivery of the first twin. The umbilical cord is protruding into the cervix.

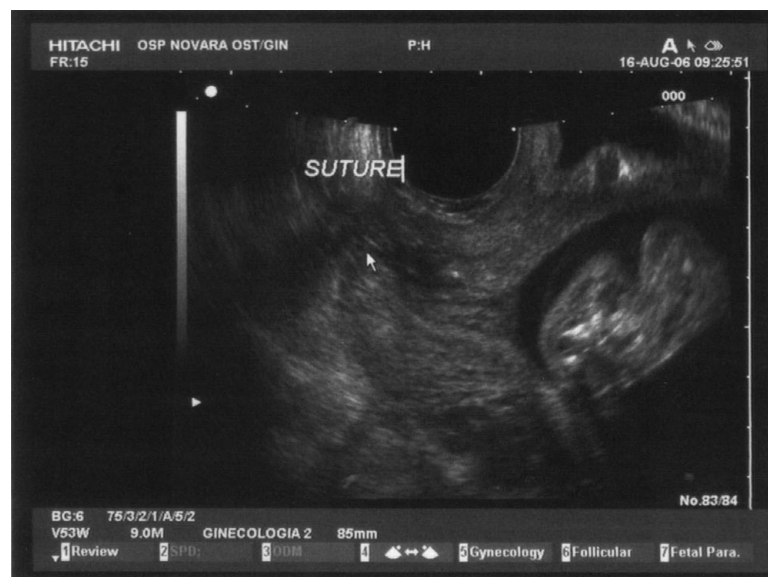


FIGURE 2

Ultrasound feature of patient 1 cervix 24 hours later umbilical cord ligation with endoloop.

cervical samples for microbiological examinations and made a vaginal washing with chlorhexidine. After one hour, contractions disappeared and ultrasound scan showed a normally inserted posterior placenta. Under ultrasound control, we proceeded to clamp the umbilical cord with Endoloop, which was positioned inside the internal os (Figures 1 and 2).

After two days, normalization of white blood cell count and C reactive protein occurred. The first twin needed resuscitation and immediate intubation. Bronchoaspiration and blood culture were negative. During hospitalization,

the newborn showed respiratory distress syndrome (RDS), patent ductus arteriosus (PDA), II–III stage retinopathy of prematurity (ROP), II stage intraventricular hemorrhage with cerebellar hemorrhage, and bronchopulmonary dysplasia. Extubation occurred 41 days after delivery and discharge after 121 days, when the baby weighed 2,640 g.

During the interval period, the mother was maintained on a regimen of broad spectrum antibiotics, 17-alpha-hydroxyprogesterone caproate, and orally administered nifedipine (Adalat LA 30 mg once daily). Blood samples were taken twice a week; vaginal and urine cultures were

collected weekly and persisted as negative. Fetal biometry, Doppler flow velocimetry, and amniotic fluid index were examined at regular intervals. Cardiocotography was performed twice a day.

After 14 days, contractions reappeared and the second female 870 gm twin was delivered. Apgar scores were 8 at 1 min and 6 at 5 min. Placental delivery occurred spontaneously. Laboratory investigations showed white blood cell count of $13.32 \times 10^3 \mu\text{L}$ and raised C reactive protein at 2.44 mg/dL. Histological examination of first twin's placenta showed chorioamnionitis whereas the second twin's placenta was negative.

The second twin needed resuscitation and immediate intubation. Gastric aspiration, broncoaspiration, and blood culture were negative. Ear, skin, and eye samples showed *Enterococcus fecalis* colonization, treated with ampicillin and netilmicin. During hospitalization were found PDA and II–III stage ROP. Extubation occurred 14 days after delivery and discharge occurred after 109 days, when the baby weighed 3,130 g.

At 40 months of follow up, both twins showed a normal neurologic and pulmonary development.

Case Report 2

A 31-year-old woman, with a diamniotic, dichorionic twin pregnancy after a FIVET procedure was admitted at 21 weeks' gestation for uterine contractions. Because of her past obstetrical history that included two miscarriages, a prophylactic cervical McDonald's cerclage was performed at 18 weeks and three days of gestation.

At admission, the cervix appeared 10 mm long and the amniotic sac of the first fetus was bulgy in the vagina. The twins were alive with biometry corresponding to gestational age. Laboratory investigations, urine analysis, and vaginal cultures were negative. We started antibiotic prophylaxis, bed rest, bethametasone, and tocolysis as described in Case 1, without a remission of uterine contraction activity. Two hours after admission, there was a premature rupture of the first twin's membranes. The cerclage was removed and the patient delivered a female weighing 380 g with no vital signs. During and after delivery, the same treatment as described in Case 1 was used. Under ultrasound control, with the help of an assistant, the surgeon applied the Endoloop as high as possible.

During the interval period, therapy with clarithromycin and nifedipine was orally administered. Blood, vaginal, and urine samples were regularly collected. Fetal biometry, Doppler flow velocimetry, and amniotic fluid index were examined at regular intervals. Because of the absence of signs of infection and of the patient history of cervical incompetence, at 22 weeks and two days a new cerclage was performed.

At 26 weeks and three days of gestation, contractions reappeared and we decided to reassume intravenous tocolysis with atosiban followed by orally administered nifedip-

ine with success. Bethametasone (12 mg per day twice) was again administered to accelerate fetal pulmonary maturation. At 27 weeks and five days of gestation, because of reappearance of regular uterine contractions, cerclage was removed and the patient delivered a male weighing 1,040 g with Apgar score of 7 and 8 at 1 and 5 min respectively. Initially, breathing was spontaneous, but after two hours RDS occurred and intubation was mandatory.

Broncoaspiration, blood cultures, and pharynx samples were negative. Ear and skin samples showed *Proteus vulgaris* colonization treated with ampicillin and netilmicin. The extubation occurred two days after delivery. The discharge occurred after 61 days, when the baby weighed 1,900 g. Histological examination of the placenta was negative. At 27 months of follow up, the baby showed normal development.

Discussion

Due to the rarity of DID, standard protocols for the management of these patients don't exist. In this paper, we report two cases of DID with Endoloop ligation of the umbilical cord, a new method that was first described in literature in 2009 and that we have used, at our institution, since 2006 (Raed & Eliezer, 2009). After delivery of the first twin, it is mandatory to tie the umbilical cord with absorbable thread placed as close as possible to the placenta. The aseptic ligation close to the placenta led to the possibility to cut off the umbilical cord stump, reducing infection risk due to maceration. The use of Endoloop allows us to place the suture higher in the birth canal, beyond the internal uterine os.

The Endoloop is routinely used to perform ligation of pedicles during laparoscopic procedures and it is easy to place. We can also suppose that the use of Endoloop can reduce slippage risk because of the knots' 'Roeder-like' shape.

Furthermore, synthetic absorbable monofilaments, like Endoloop, less frequently lead to infections, so we can perform this procedure minimizing chorioamnionitis risk. In both cases, we obtained good results, with no mother complications and long intervals between deliveries; the babies had no sequelae during the follow up.

Some authors routinely perform cervical cerclage immediately after the first delivery; others don't recommend it. Arabin and van Eyck (2009) suggest that it is better not to close the cervix by performing cerclage because of concern of chorioamnionitis. On the contrary, Zhang et al. (2003) support cerclage treatment, because it can minimize fetal membranes' exposure to vaginal bacteria and acidity, prolonging delay interval.

We performed cervical cerclage only in Case 2 because of the patient history of miscarriages due to cervical incompetence. At the pre-delivery assessment, there was no evidence of chorioamnionitis, vaginal, or urinary tract infections. White blood cell count and reactive C protein were within normal range. We supposed that the pathophysiological issue of this preterm labor wasn't related to infection but to cervical incompetence. Cerclage was not performed

immediately after delivery, but after a week, strictly monitoring infective parameters. The delivery interval was six weeks and five days, so we think that, in this case, the cerclage was a successful treatment.

We chose to avoid cerclage in Case 1 because of the presence of signs of chorioamnionitis (increased white blood cell count and raised reactive C protein). In this case, the delivery interval was only two weeks. During the interval period, we paid attention to avoid digital examination, minimizing the risk of iatrogenic infection diffusion. We monitored cervical length modifications by transvaginal ultrasound scan, coating the probe with sterile gloves.

In our experience, all babies had good outcomes, and, after a median follow up of 35.6 months, all showed normal development. We believe that the good outcome is due to close observation of our protocol, which includes bed rest, antibiotic therapy, strict avoidance of routine vaginal examination, tocolysis, and lung maturation induction with bethametasone, but it is also related to the Endoloop ligation of umbilical cord that, allowing high cord ligation, could minimize infection risk and subsequent chorioamnionitis.

References

- Arabin, B., & van Eyck, J. (2009). Delayed-interval delivery in twin and triplet pregnancies: 17 years of experience in one perinatal center. *American Journal of Obstetrics and Gynecology*, *200*, 154.e1–154.e8.
- Kalchbrenner, M. A., Weisenborn, E. J., Chyu, J. K., Kaufman, H. K., & Losure, T. A. (1998). Delayed delivery of multiple gestations: Maternal and neonatal outcomes. *American Journal of Obstetrics and Gynecology*, *179*, 1145–1149.
- Oleyese, Y., Ananth, C. V., Smulian, J. C., & Vintzileos, A. M. (2005). Delayed interval delivery in twin pregnancies in the United States: Impact on perinatal mortality and morbidity. *American Journal of Obstetrics and Gynecology*, *192*, 439–444.
- Raed, S., & Eliezer, S. (2009). Endoloop ligation of the umbilical cord of an aborted fetus in a twin gestation. *International Journal of Gynecology and Obstetrics*, *105*, 270.
- Zhang, J., Johnson, C. D., & Hoffman, M. (2003). Cervical cerclage in delayed interval delivery in a multifetal pregnancy: A review of seven case series. *European Journal of Obstetrics & Gynecology and Reproductive Biology*, *108*, 126–130.
-