



Letter to the Editor: New Observation

Dermatomyositis Immunosuppression in Bacillus Calmette–Guerin-Treated Urothelial Cancer

Dennis Dimond¹ , Negar Tehrani¹, Athithan Ambikkumar², Julia Madill³, Karen Naert⁴, Kristopher D. Langdon⁴  and Carlos R. Camara-Lemarroy¹

¹Department of Clinical Neurosciences, University of Calgary, Cumming School of Medicine, Calgary, Alberta, Canada, ²Department of Surgery, Section of Ophthalmology, University of Calgary, Cumming School of Medicine, Calgary, Alberta, Canada, ³Department of Emergency Medicine, University of Calgary, Cumming School of Medicine, Calgary, Alberta, Canada and ⁴Department of Pathology & Laboratory Medicine, University of Calgary, Cumming School of Medicine, Calgary, Alberta, Canada

Keywords: Dermatomyositis; transition cell carcinoma; immunosuppression; bacillus calmette-guerin

Dermatomyositis (DM) is a rare inflammatory myopathy that presents with characteristic dermatologic lesions in addition to progressive motor weakness and myalgia. While classically idiopathic, there are numerous reports of DM occurring secondary to infectious triggers and malignancies.^{1,2} Treatment is typically with corticosteroids, though immunosuppression can pose risks in the context of concordant management of an underlying cancer. Here, we report a case study of a patient with DM and the diagnostic and management considerations that arose in the context of recent intravesical Bacillus Calmette–Guerin (BCG) therapy for transition cell carcinoma (TCC).

A 71-year-old male presented with a 4-month history of ~15 lbs weight loss, myalgia, progressive weakness, dysphagia to solid foods, and a worsening erythematous rash. The patient's medical history was significant for TCC, diagnosed 4 months prior, and treated with two surgical resections and 6 weeks of intravesical BCG. Physical examination confirmed proximal muscle weakness and dermatologic findings consistent with DM (Fig. 1). Laboratory investigations revealed mildly elevated urea, but normal creatine kinase, C-reactive protein, creatinine, and glomerulus filtration rate. An autoimmunity panel was positive for anti-transcription intermediary factor 1 gamma (anti-TIF1- γ), an autoantibody highly suggestive of cancer-associated dermatomyositis (CAD).³ Further supporting a diagnosis of DM was electromyography findings of fibrillations and positive sharp waves with needle insertion, indicative of irritable myopathic units, and evidence of active myositis on magnetic resonance imaging (MRI; Fig. 2A and B). To confirm the diagnosis, muscle and skin biopsies were performed, which demonstrated characteristic pathological findings including perimysial lymphocytic inflammation and perifascicular myofiber atrophy and MHC Class I immunolabeling; myovasculopathy; and thin epidermis with vacuolar-type interface damage, sparse perivascular inflammation, and increased dermal mucin (Fig. 2C–H). Given the positive anti-TIF1- γ , a scrotal ultrasound and computed tomography (CT) of the chest,

abdomen, and pelvis was performed to screen for a secondary malignancy. Imaging did not identify any abnormalities suggestive of a new primary cancer, nor evidence of expansion or metastases of the known TCC. Further, there was no evidence of fibrosis or other findings on CT chest to suggest connective tissue disease-related interstitial lung disease.

First-line treatment with oral prednisone was initially withheld over concerns of BCG dissemination, and the patient was instead treated with IVIG, which was successful in halting symptom progression. After review with the multidisciplinary attending team, the decision was made to proceed with prednisone, as the risk of BCG dissemination was believed to be low. Prednisone (50 mg PO daily) was initiated, and the patient showed early improvement in weakness and myalgia and partial resolution of his rash. He was discharged from hospital with plans for an outpatient prednisone taper and 3–6 months of q30 day IVIG for DM maintenance therapy, and consideration of alternative treatment (e.g., intravesicular chemotherapy) for his TCC.

The association between cancer and DM is well recognized; prevalence of malignancy in DM ranges from ~9% to 60%.¹ DM has been linked with various cancers, including lymphoma, lung, ovary, colorectal, pancreatic, stomach, and breast cancer.^{1,4} Urothelial cancer is less common, though it has been reported as the fifth most common cancer type among CAD patients with anti-TIF1- γ positivity.³ In some such cases, DM manifestation acted as a clinical indicator of TCC recurrence, manifesting prior to cancer-related symptoms and prompting timely investigation to rule out cancer recurrence.² Together, these observations emphasize the importance of early screening for both primary and recurrent TCC in patients with DM, especially when anti-TIF1- γ is positive.

Regardless of the underlying cancer type, CAD is hypothesized to be the result of paraneoplastic processes inducing autoimmune myositis.¹ Of course, autoimmunity precipitating DM can manifest alongside but independent of cancer. Various environmental, pharmaceutical, and infectious triggers of DM have been

Corresponding author: D. Dimond; Email: dennis.dimond@ucalgary.ca

Cite this article: Dimond D, Tehrani N, Ambikkumar A, Madill J, Naert K, Langdon KD, and Camara-Lemarroy CR. (2024) Dermatomyositis Immunosuppression in Bacillus Calmette–Guerin-Treated Urothelial Cancer. *The Canadian Journal of Neurological Sciences* 51: 441–443, <https://doi.org/10.1017/cjn.2023.238>

© The Author(s), 2023. Published by Cambridge University Press on behalf of Canadian Neurological Sciences Federation. This is an Open Access article, distributed under the terms of the Creative Commons Attribution licence (<http://creativecommons.org/licenses/by/4.0/>), which permits unrestricted re-use, distribution and reproduction, provided the original article is properly cited.

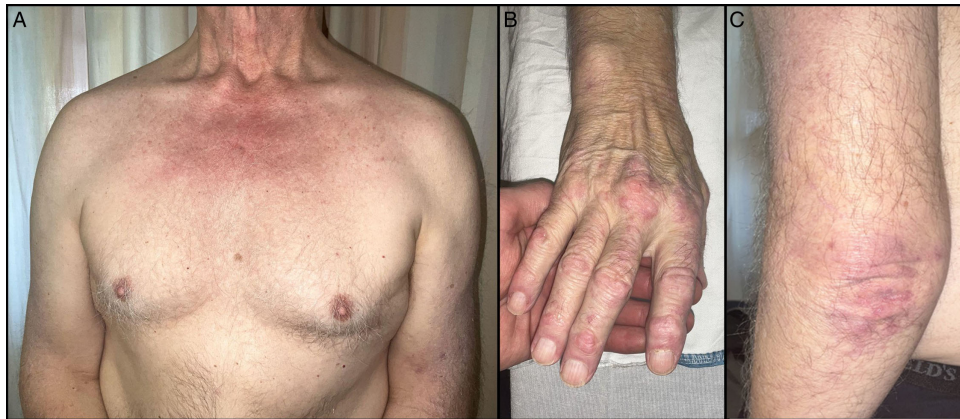

Figure 1: Dermatologic manifestations. patient's dermatologic findings characteristic of dermatomyositis, including heliotrope eruptions and V-sign (A), gottron's papules and capillary abnormalities (B), and gottron's sign (C).

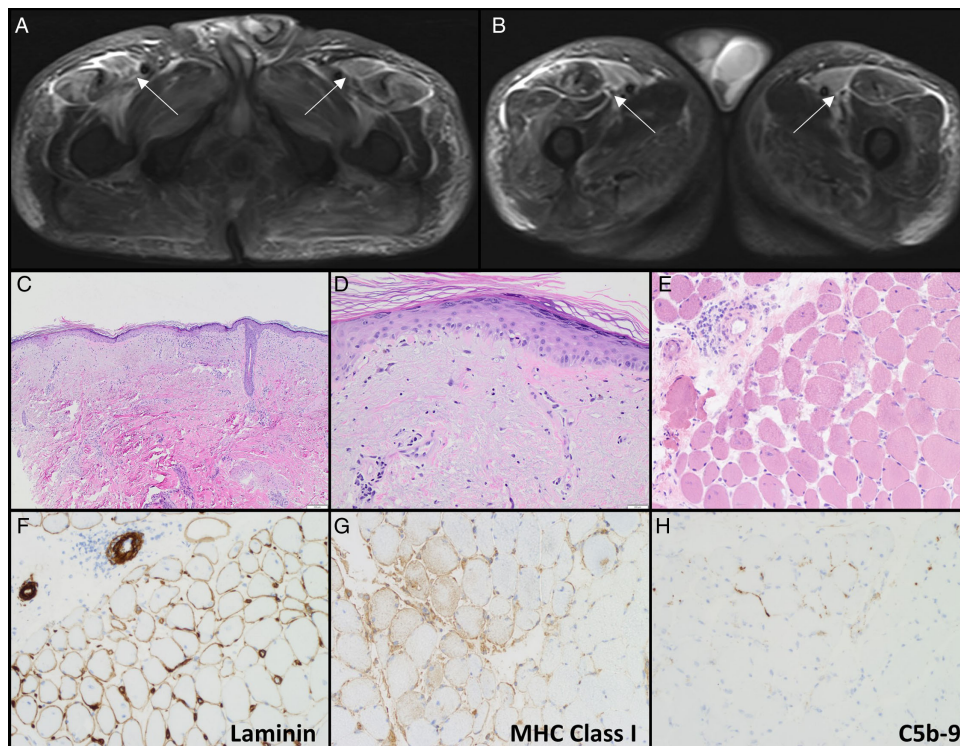


Figure 2: Imaging and biopsy findings. (A-B) axial MR images of the pelvis and proximal femur demonstrating T2 (A) and STIR (B) signal hyperintensity, indicative of active myositis, in the proximal sartorius, rectus femoris, and vastus lateralis muscles. (C-D) biopsy of brachial skin showing atrophic epidermis with sparse dermal inflammation (C), and pauci-inflammatory interface dermatitis and interstitial basophilic material in the dermis compatible with mucin (D). (E-H) biopsy of the vastus lateralis demonstrating perimysial and perivascular lymphocytic inflammation (E), perifascicular myofiber atrophy (E), myovasculopathy that includes focal perifascicular capillary loss (laminin) and labeling with complement (C5b-9) staining (F & H), and focal perifascicular MHC class I (HLA-ABC) myofiber staining.

identified. Interestingly, there are at least two reports of DM developing secondary to BCG vaccination.⁵ Also, intravesical BCG treatment for TCC has been reported to induce autoimmune conditions such as myasthenia gravis.⁶ Together these observations raise the possibility of BCG-induced DM in the current case, although CAD is more likely given the patient's known TCC, positive anti-TIF1- γ , and onset of early DM symptoms prior to BCG treatment. Still, this case illustrates the importance of entertaining external and iatrogenic precipitants of autoimmunity in DM, as this may influence treatment.

Mainstay therapy for sporadic DM is immunosuppression. Corticosteroids are considered first-line treatment, while second-line medications include azathioprine, methotrexate, and IVIG.¹ In CAD, symptoms have been shown to improve following treatment of the underlying malignancy,¹ suggesting this should be prioritized. Despite this, immunosuppressive therapy is often necessary to control DM symptoms, especially when its manifestation includes dysphagia or causes severe functional limitation. Immunosuppression in CAD poses potential risks, however, in that it may: (1) facilitate malignancy propagation,¹ (2) increase

risk of complications from concurrent cancer treatment, or (3) decrease efficacy of cancer therapy. These risks are exemplified by the case presented here, though in each case the benefits of steroids were felt to outweigh the risks after review of the literature. Firstly, while there is some evidence to suggest increased recurrence or propagation of TCC on immunotherapy, incidence is low even in cases of significant immunosuppression.⁷ Secondly, immunosuppression following intravesical BCG treatment theoretically increases the risk of dissemination. Likewise, however, there are few reported cases.⁸ Data is also lacking on the impact of immunosuppressants on intravesical BCG efficacy. As a result, immunosuppressant use is generally considered a relative, but not absolute, contraindication to intravesical BCG. Considering this, the decision was made in the current case to treat DM with IVIG and prednisone and resort to alternatives to intravesical BCG for the treatment of the patient's TCC. This case illustrates important considerations in immunotherapy use and the necessity for flexible treatment plans in the management of CAD.

Acknowledgements. We would like to thank the patient and their family for providing consent to share this case with the medical community.

Competing interests. Author KDL serves as a consulting neuropathologist for the "NEED" – a personalized cancer protection system. Otherwise, all included authors have no potential conflicts of interest to declare.

Statement of authorship. DD - Clinical management of the case, literature review, figure formatting, manuscript construction, and revision.

NT - Clinical management of the case, literature review, manuscript review, and input.

AA - Clinical management of the case, manuscript review, and input.

JM - Clinical management of the case, manuscript review, and input.

KN - Assessment and interpretation of pathology sample, figure generation, manuscript review, and input.

KDL - Assessment and interpretation of pathology sample, figure generation, manuscript review, and input.

CCL - Clinical management of the case (attending physician), project supervision, manuscript review, and input.

References

1. Chang L, Zhang L, Jia H, Nie Z, Zhang L. Malignancy in dermatomyositis: a retrospective paired case-control study of 202 patients from Central China. *Medicine*. 2020;99:e21733. DOI: [10.1097/MD.00000000000021733](https://doi.org/10.1097/MD.00000000000021733).
2. Bientinesi R, Ragonese M, Pinto F, Bassi PF, Sacco E. Paraneoplastic dermatomyositis associated with panurothelial transitional cell carcinoma: a case report and literature review. *Clin Genitourin Cancer*. 2016;14:e199–201. DOI: [10.1016/j.clgc.2015.11.010](https://doi.org/10.1016/j.clgc.2015.11.010).
3. Hida A, Yamashita T, Hosono Y, et al. Anti-TIF1- γ antibody and cancer-associated myositis: a clinicohistopathologic study. *Neurology*. 2016;87:87–3. DOI: [10.1212/WNL.0000000000002863](https://doi.org/10.1212/WNL.0000000000002863).
4. Qiang JK, Kim WB, Baibergenova A, Alhusayen R. Risk of malignancy in dermatomyositis and polymyositis. *J Cutan Med Surg*. 2017;21:131–6. DOI: [10.1177/1203475416665601](https://doi.org/10.1177/1203475416665601).
5. K ass E, Straume S, Mellbye OJ, Munthe E, Solheim BG. Dermatomyositis associated with BCG vaccination. *Scand J Rheumatol*. 1979;8:187–91. DOI: [10.3109/03009747909114454](https://doi.org/10.3109/03009747909114454).
6. Davalos L, Kushlaf H. New onset of seropositive generalized myasthenia gravis following intravesical bacille calmette-guerin treatment for bladder cancer: a case study. *Muscle Nerve*. 2019;59:e1–2. DOI: [10.1002/mus.26328](https://doi.org/10.1002/mus.26328).
7. Wang HB, Hsieh HH, Chen YT, Chiang CY, Cheng YT. The outcome of post-transplant transitional cell carcinoma in 10 renal transplant recipients. *Clin Transplant*. 2002;16:410–3. DOI: [10.1034/j.1399-0012.2002.01152.x](https://doi.org/10.1034/j.1399-0012.2002.01152.x).
8. M.A.P erez-Jacoiste As ın MA, Fern andez-Ruiz M, Lopez-Medrano F, et al. Bacillus calmette-gu erin (BCG) infection following intravesical BCG administration as adjunctive therapy for bladder cancer: incidence, risk factors, and outcome in a single-institution series and review of the literature. *Medicine*. 2014;93:236–54. DOI: [10.1097/MD.000000000000119](https://doi.org/10.1097/MD.000000000000119).