

cornerstones of management comprises early diagnosis with re-establishment of the airway, adequate oxygenation and application of positive airway pressure [1–4].

R. van Vugt, H. J. van Leeuwen, D. H. T. Tjan,
A. R. H. van Zanten
Department of Intensive Care
Gelderse Vallei Hospital
Ede, The Netherlands

References

1. Louis PJ, Fernandes R. Negative pressure pulmonary edema. *Oral Surg Oral Med Oral Pathol Oral Radiol Endod* 2002; 93: 4–6.
2. Koh MS, Hsu AA, Eng P. Negative pressure pulmonary oedema in the medical intensive care unit. *Intensive Care Med* 2003; 29: 1601–1604.
3. Deepika K, Kenaan CA, Barrocas AM, Fonseca JJ, Bikazi GB. Negative pressure pulmonary edema after acute upper airway obstruction. *J Clin Anesth* 1997; 9: 403–408.
4. Willms D, Shure D. Pulmonary edema due to upper airway obstruction in adults. *Chest* 1988; 94: 1090–1092.

Symptomatic atlantoaxial dislocation in Marfan's syndrome: anaesthetic considerations

doi: 10.1017/S0265021507000932

EDITOR:

Marfan's syndrome is a relatively uncommon familial disorder with an incidence of about 1:10 000 in most racial and ethnic groups [1]. It is characterized by widespread abnormalities of the skeletal, cardiovascular and ocular symptoms. Although cervical spine abnormalities including atlantoaxial dislocation are common in these patients, clinical problems associated with them are rare [2]. Clinically symptomatic cases of atlantoaxial dislocation in Marfan's syndrome are rarely reported in literature [3,4]. We describe a patient with Marfan's syndrome undergoing corrective surgery for atlantoaxial dislocation under general anaesthesia.

A 21-yr-old 174 cm male weighing 44 kg presented with a 4-yr history of progressive weakness of all four limbs following the fall of an object on his neck. Gradually, he developed difficulty in getting up from a squatting position without support. His past medical history was unremarkable. On examination, this tall patient revealed typical features of Marfan's syndrome: arachnodactyly, high arched palate, winging of scapula, ulnar deviation of metacarpophalangeal joints and bilateral congenital talipes equinovarus. There were no significant abnormalities on examination of the cardiovascular system. However, routine transthoracic echocardiography showed aortic root dilatation (42 mm) with

normal left ventricular function. The patient had diminished motor power in all four limbs (4/5). His gag reflex was impaired indicating involvement of lower cranial nerves. A magnetic resonance imaging of the cervical spine showed atlantoaxial dislocation with basilar invagination by an abnormally curved odontoid peg with significant cervical cord compression at the level of the atlas. The patient was diagnosed to have a craniovertebral junction anomaly associated with Marfan's syndrome. Surgical correction was planned, which included trans-oral odontoidectomy and posterior fixation. Two days before surgery, Gardner–Wells tong traction was attached under local anaesthesia to reduce the dislocation. The plan of awake fiberoptic intubation was discussed with the patient. On the day of surgery, he was premedicated with glycopyrrolate 0.2 mg intramuscularly, 1 h before induction. Awake intubation was performed after anaesthetizing the upper airway with lidocaine 4% viscous, bilateral superior laryngeal nerve blocks and a trans-tracheal injection of lidocaine 4%. Standard anaesthetic induction was followed using fentanyl, thiopental and rocuronium. Anaesthesia was maintained with O₂, N₂O (1:2) and isoflurane with intermittent bolus of rocuronium and fentanyl. Mean blood pressure (BP) was maintained at about 70–80 mmHg by titrating the inspired concentration of isoflurane along with boluses of fentanyl. Care was taken to prevent hypertensive episodes during various steps of anaesthesia and surgery with the use of an intravenous nitroglycerin infusion. Monitoring parameters included ECG, SpO₂, ETCO₂ and continuous arterial BP. The surgical procedure

Correspondence to: Girija P. Rath, Department of Neuroanaesthesiology, Neurosciences Centre, All India Institute of Medical Sciences, New Delhi 110029, India. E-mail: girijarath@yahoo.co.in; Tel: +91 9868398204; Fax: +91 11 26588663

Accepted for publication 15 May 2007 EJA 4555
First published online 22 June 2007

involved two stages. Transoral odontoidectomy was performed in the supine position followed by posterior fixation in the prone position on a Wilson frame. The intraoperative course was uneventful. At the end of surgery, the patient was turned supine and residual neuromuscular blockade was reversed. The trachea was not extubated but after observing movement in all four limbs, the patient was sedated with midazolam and fentanyl. He was taken to the neurosurgical ICU for overnight pressure-support ventilation, as routine [6]. The tracheal tube was removed on the first postoperative day, after ensuring satisfactory cough reflex and respiration. There was no change in echocardiography findings on the second postoperative day. At the 3-month follow up, the patient is doing well with improved motor power in all four limbs.

Marfan's syndrome is a connective tissue disorder caused by mutation in a gene (FBN1) on chromosome 15, which encodes the glycoprotein fibrillin1, the principal component of extracellular matrix microfibrils [5]. It is inherited as an autosomal dominant trait. Common manifestations of this disease include mitral valve prolapse, aortic root dilatation, dissection, lens dislocation and myopia, arachnodactyly, kyphoscoliosis, sternal deformities and dural ectasia. Scoliosis has been reported in 40–70% of patients. Radiological analysis of the cervical spine revealed increased prevalence of atlantoaxial dislocation, basilar invagination and increased odontoid height [3]. Such patients may present with features of dysfunction of brainstem, cerebellum, spinal cord and cranial nerves. They may also complain of pain, stiffness and restriction of neck movements, vertigo, confusion, transient attacks of unconsciousness, weakness and paraesthesiae of limbs and respiratory abnormalities [6]. Our patient presented with quadriplegia due to compression of bony structures in the upper cervical spinal cord. Securing of the airway in these patients may be challenging not only because excessive manipulation of the atlanto-occipital joint has to be avoided but also because of the associated airway abnormalities. Excessive traction during laryngoscopy for tracheal intubation should be avoided to prevent jaw dislocation due to associated joint laxity. Hence, it is appropriate to carry out fiberoptic intubation, preferably while being awake, in these patients.

Anaesthetic management in patients with atlantoaxial dislocation has rarely been described [6]. Its association with Marfan's syndrome even with a normal cardiovascular system makes these patients at risk for anaesthesia. The cardiovascular manifestations may include mitral valve prolapse, mitral regurgitation, enlargement of the aorta, aortic dissection, aortic rupture or aortic regurgitation. Cardiac arrhythmias

may be primary or secondary and are a potential cause of sudden death. Appropriate antibiotic prophylaxis for bacterial endocarditis is required.

As pulsatile flow is more important than steady-state hypertension in producing aortic dissection, it is appropriate to add a beta blocker to decrease myocardial contractility and aortic pressure rise. Prophylactic beta blockers have also been shown to decrease the size of aortic dilatation [7]. In our patient, as the aortic dilatation was 42 mm (normal 20–38 mm), a beta blocker was not used. Inhalational agents, which reduce the velocity of ventricular contraction, are ideal; however, no single anaesthetic agent or technique has demonstrated superiority. Control of BP alone by vasodilators may increase left ventricular ejection velocity, and, hence, it should be combined with beta blockade to prevent dissection.

Reduction in connective tissue elasticity makes all the joints prone to dislocation especially when the patient is anaesthetized, and careful positioning and handling is required. In our patient, surgery consisted of two steps performed in supine and prone positions, respectively. A mouth gag with tongue retractor is used to access the posterior pharyngeal wall, and here mandibular dislocation remains a possibility. The use of Gardner–Wells tong traction to reduce dislocation is questionable as it may further add to the problems in a cervical spine with lax joints. However, in our patient all these manoeuvres were uneventful.

Anterior chest deformity can contribute to a restrictive pattern of lung disease [1,7] and skeletal changes including kyphoscoliosis can lead to decreased pulmonary function [6]. Widening of distal airspaces with bullae or blebs predisposes to spontaneous pneumothorax, and this must be borne in mind during anaesthesia with positive pressure ventilation.

In conclusion, we successfully managed a patient undergoing corrective surgery for atlantoaxial dislocation with basilar invagination in Marfan's syndrome, under general anaesthesia. The possibility for acute airway, cardiovascular and respiratory complications in these subgroup of patients necessitates careful preoperative assessment and optimal anaesthetic techniques to avoid potential complications.

G. P. Rath, D. Singh, H. Prabhakar, P. K. Bithal
 Department of Neuroanaesthesiology
 Neurosciences Center
 All India Institute of Medical Sciences
 New Delhi, India

References

1. Prockop DJ, Kuivaniemi H, Tromp G. Inherited disorders of connective tissue. In: Fauci AS, Martin JB, Braunwald E,

- Kasper DL, Isselbacher KJ, Hauser SL, Wilson JD, Longo DL, Randolph T, eds. *Harrison's Principles of Internal Medicine*, 14th edn. New York: McGraw-Hill, 1998: 2183–2194.
- Hobbs WR, Sponseller PD, Weiss APC, Pyeritz RE. The cervical spine in Marfan syndrome. *Spine* 1997; 22: 983–989.
 - Herzka A, Sponseller PD, Pyeritz RE. Atlantoaxial rotatory subluxation in patients with Marfan syndrome. *Spine* 2000; 25: 524–525.
 - Place HH, Enzenauer RJ. Cervical spine subluxation in Marfan syndrome. A case report. *J Bone Jt Surg Am* 2006; 88: 2479–2282.

- Judge DP, Dietz HC. Marfan's syndrome. *Lancet* 2005; 366: 1965–1976.
- Rath GP, Bithal PK, Guleria R *et al.* A comparative study between preoperative and postoperative pulmonary functions and diaphragmatic movements in congenital Craniovertebral junction anomalies. *J Neurosurg Anesthesiol* 2006; 18: 256–261.
- Shores J, Berger KR, Murphy EA, Pyeritz RE. Progression of aortic dilatation and the benefit of long term beta-adrenergic blockade in Marfan's syndrome. *N Engl J Med* 1994; 330: 1335–1341.

Detecting intravascular injection during caudal anaesthesia in children

doi: 10.1017/S0265021507001020

EDITOR:

Caudal anaesthesia may be used as an adjunct to general anaesthesia to provide postoperative analgesia in infants. Since inadvertent intravascular injection can result in life-threatening cardiovascular complications, criteria have been defined for detecting intravascular injection. Besides careful aspiration before injection, an epinephrine containing test dose is commonly used [1]. An increase in amplitude of the T-wave on the electrocardiogram (ECG) by $\geq 25\%$ or an increase in heart rate (HR) of ≥ 10 beats min^{-1} reliably detected intravascular injection in simulated intravenous (i.v.) test dose experiments [1–3]. We present three cases to illustrate that multiple factors can influence the sensitivity of an epinephrine test dose in infants (Fig. 1).

Patient A, a 7-week-old male weighing 5.3 kg was scheduled for inguinal hernia repair. After induction of anaesthesia with sevoflurane, cannulation with a 24-G needle and placement of a laryngeal mask, he was placed in the lateral position. After introduction of a 25-G caudal needle (Epican Paed (Braun, Melsungen, Germany), 30 mm, short bevel) into the caudal space and negative aspiration, a test dose of 1 mL of bupivacaine 1.25 mg mL^{-1} containing epinephrine 2.5 $\mu\text{g mL}^{-1}$ was administered. No changes in T-wave or HR were seen after 20 s. During subsequent administration of the next 1 mL of the same solution, a rise in T-wave ampli-

tude occurred followed by a rise in HR from 149 to 156 beats min^{-1} . Blood could now be aspirated through the caudal needle. The ECG changes resolved within 1 min. The caudal needle was repositioned and, after negative aspiration and a further test dose, a total of 7 mL of bupivacaine 1.25 mg mL^{-1} with epinephrine was given without further sequelae. The surgery and recovery were uneventful.

Patient B, a 7-week-old female weighing 5.4 kg, was scheduled for inguinal hernia repair. Induction of anaesthesia was performed as described above. After insertion of a caudal needle and negative aspiration, 1 mL of bupivacaine 1.25 mg mL^{-1} with epinephrine 2.5 $\mu\text{g mL}^{-1}$ was injected as a test dose. After 25 s, there was no significant change in T-wave morphology or HR, and injection was continued until, after another 2 mL of the same solution, an increase in T-wave amplitude occurred without a rise in HR. Repeated aspiration was positive for blood. After repositioning the needle and negative aspiration and test dose, 7 mL of bupivacaine with epinephrine was administered without complications. Surgery was performed and recovery was uneventful.

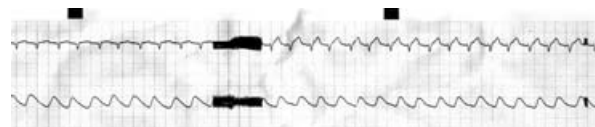


Figure 1. Electrocardiogram (ECG) and pulse oximetry record of patient B. Baseline ECG followed by T-wave changes after injecting 3.75 mg bupivacaine with 7.5 mcg of epinephrine (paperspeed 12.5 mm s^{-1}).

Correspondence to: Johanna HAM Megens, Department of Peri-operative Care and Emergency Medicine, University Medical Centre Utrecht, Wilhelmina Children's Hospital, PO Box 85090, 3508 AB Utrecht, The Netherlands. E-mail: j.h.a.m.megens@umcutrecht.nl; Tel: +31 0 30 250 9475; Fax: +31 0 30 250 5319

Accepted for publication 22 May 2007 EJA 4575
First published online 22 June 2007