

ON THE ASSOCIATION OF THE PLEUROPNEUMONIA-LIKE ORGANISM L3 WITH BRONCHIECTATIC LESIONS IN RATS

By EMMY KLIENEBERGER AND DOROTHY B. STEABBEN

From the Bacteriological Department, Lister Institute, London

(With Plate V)

IN 1937 Klieneberger & Steabben described the pleuropneumonia-like L3 organism isolated from the lungs of rats suffering from the "bronchopneumonia" common among laboratory rats. An attempt has since been made to establish an aetiological relationship between this organism and the pathological condition of the rat. No definite evidence either positive or negative, however, could be obtained because so large a percentage of the stock rats harboured the organism and developed the characteristic lung condition that the ordinary routine of experimental infection was precluded. Nevertheless, it may be of interest to record some of the information obtained on the occurrence of the pulmonary disease and the associated L3 organism in tame and wild rats, because what evidence there is goes to show that there may be a very close association between the presence of the L3 organism and the chronic pulmonary disease of the rat.

Of 268 rats examined, 251 were laboratory rats and seventeen wild rats. The lung lesions and the L3 organism were found in only one among the wild rats, and this was a young sewer rat. By contrast, the lung lesions were present in 108 of the laboratory rats, and the organism was recovered from 138. Though from the aetiological point of view the infection experiments were disappointing, the observations made in the course of the work are interesting, since they show how the degree of infection with the L3 organism increases directly with the severity of the lesions in the lung, from the stage at which injury to the lung is absent, or inconspicuous, and the L3 organism is absent, or scanty, to the stage where the whole lobe of a lung has become a mass of dry, caseous pus of which the smallest particle yields many thousands of L3 colonies. Table 1, showing the age distribution of the lung disease in 228 normal rats, makes this clear. Of the 251 laboratory rats examined, twenty-three were castrated or ovariectomized animals which had been discarded from experiments elsewhere in the Institute, because they had "pneumonia" or were not gaining weight. These rats were 1-3 months old, but eighteen of the twenty-three showed macroscopic lung lesions, and in twenty-two the L3 organism was demonstrated by cultures. In these animals, subjected to operation, the progress of the lung disease was greatly accelerated, and the

incidence of the L3 organism and the pulmonary disease is much more frequently demonstrable in such rats than in stock rats of the same age. These twenty-three rats form a selected group, and are, therefore, not included in Table 1. The remaining 228 rats were either stock animals, or had been used as control or experimental animals. As already mentioned, infection experiments had no detectable effect on the development of the lung condition, so that the data obtained from all these rats show the distribution of the lung disease in so-called normal rats. In Table 1 the 228 rats are divided into five age groups, and the number of rats with macroscopic lung lesions, and the number in which the L3 organism was found, are given for each group.

Table 1

Group	No. of rats examined	Ages in months	No. of rats with lesions	No. of rats with L3
1	14	Under 1 month	0	1
2	84	1-4	8 = 10 %	29 = 36 %
3	71	4-8	22 = 31 %	46 = 65 %
4	33	8-12	28 = 85 %	24 = 73 %
5	26	12-24	26 = 100 %	20 = 77 %

This table shows that both the number of rats with lung affections and the number containing the L3 in their lungs increase with age. Newborn rats never showed naked-eye lesions and never yielded the L3 organism. Among the fourteen small rats of the first group was only one that at the age of 3 weeks contained the L3 organism in its lungs, but it had not yet developed lesions. It is not surprising that the L3 organism is found before naked-eye lesions can be discovered, because if the L3 organism is really connected with the lung disease it is very likely to be present in the lungs before pathological changes occur. In agreement with this the number of rats from which an L3 can be recovered is in the first groups larger than the number of rats with lung lesions. In the second age group the ratio (number of rats with L3 : number of rats with lesions) is 3 : 1, in the third group it is 2 : 1. The older the rats the more frequently do the presence of the lesions and the isolation of the L3 coincide. Among very old rats none was found without the lesions in its lungs; but, as can be seen from the table, in old rats the number of animals from which L3 was isolated was slightly smaller than the number of animals which showed definite lesions. There are two reasons for this: (a) there are more secondary invaders or contaminations in the affected lungs of old rats than in the lungs of young animals and these may spread over the plates and render the demonstration of the L3 impossible; (b) there are always a few cases in which the L3 culture does not grow.

The rats examined were stock bred in this Institute. As it was hoped to procure animals free from the disease, a few animals of other London stocks were examined also, but they appeared to be infected in much the same way as the Lister rats. Table 2 gives the comparative figures for the stocks examined.

Table 2

Stock	No. of rats examined	No. of rats with lesions	No. of rats with L3	Ages in months
Lister	228	84	120	1-24
W.B.C.	6	0	0	Less than 2
B.C.	6	0	2	3
G.L.	10	4	5	3-4

It is to be noted here that the age incidence of the condition even in the small group of outside stocks examined corresponded very well with the figures in Table 1 relating to the Lister stock. Histologically also, similar changes were observed in the lungs of the outside stocks examined. Before any lesions are evident macroscopically pathological changes are to be found, particularly destruction of the columnar epithelium of the main bronchial tubes, and intense aggregation of lymphocytes round the lumen of the tubes, with, later, the passage of polymorphonuclear cells through the epithelium, and the accumulation of pus and fluid. It must be emphasized that these conditions occur in rats which appear to be quite active and healthy. In the youngest outside stock (W.B.C.), less than 2 months old, no macroscopic or microscopic lesions were found and no L3 organism was isolated. From the rats not more than 3 months old (B.C.), the L3 organism was isolated from two out of six rats, and differing degrees of the bronchiectasis were found histologically, from a slight peribronchial lymphocytic infiltration and some vacuolation of the columnar epithelium to a severe peribronchial and perivascular lymphocytic infiltration, with considerable destruction of the main bronchial tubes. Though there was some fluid in the bronchioles, the migration of the polymorphonuclear cells into the lumina, which appears to be the beginning of the abscesses which finally destroy the lung, had not begun. Here again it should be pointed out that the external surface of the lung at this stage shows no indication of the changes taking place within, and from a naked-eye examination it would be concluded that the lungs were normal. In the oldest rat examined (G.L.), 4½ months, the characteristic gelatinous nodules (Fig. 3) were present in the lung, the L3 organism was obtained in pure culture, and gross pathological changes were found histologically; large abscesses had developed from the bronchi (Fig. 4) and the columnar epithelium, which in some parts had become squamous in character, was largely destroyed.

While this pulmonary disease is chronic in character in most laboratory rats a few suffer from an acute form while still very young. The acute disease seems to be fatal. Figs. 1 and 2 show the lungs of two young rats, both weighing 50 g., 5 and 4 weeks old respectively. The rat of Fig. 1 was suffering from a severe, acute bronchopneumonia, while the lungs of the rat of Fig. 2 were healthy in appearance. Fig. 1 demonstrates the very considerable hypertrophy of the lungs which results from this infection. Those lungs shown in the photograph contained glairy exudate and yielded the L3 organism in culture.

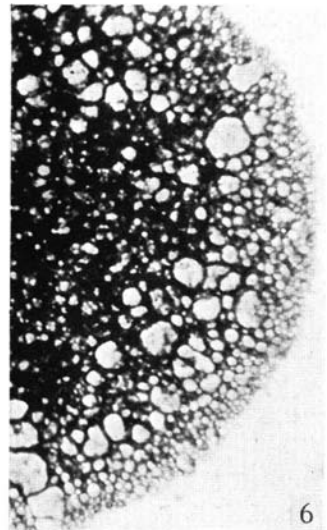
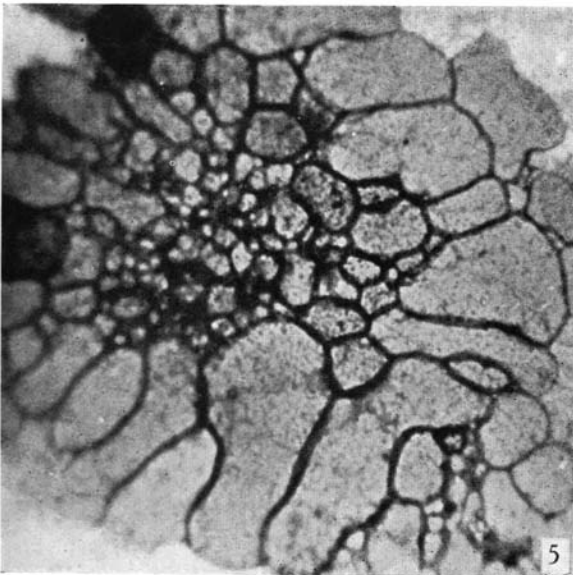
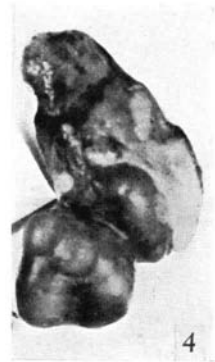
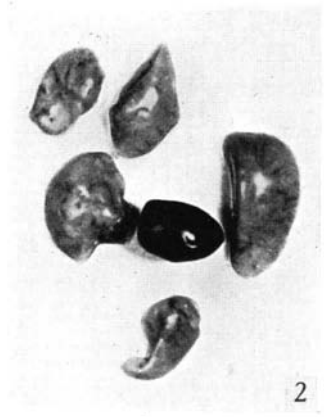
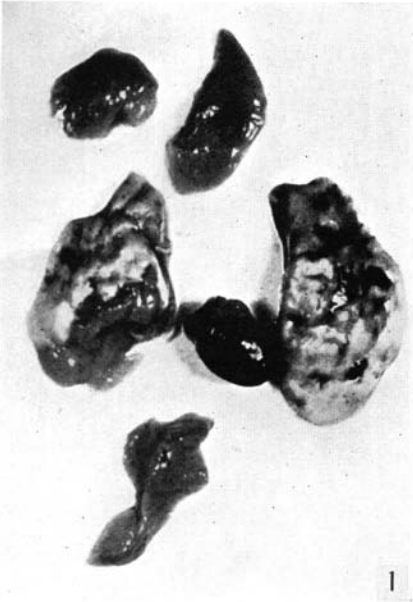The data given here demonstrate that there is a close connexion between the

presence of the L3 organism and the pulmonary lesions of the rat, though no positive evidence for the aetiological significance of the L3 organism has been obtained. The problem as to how the infection takes place has not yet been approached. In the well-known diseases of pleuropneumonia of cattle and agalactia of sheep, caused by organisms of the same group, the mode of infection has not yet been cleared up. From this point of view the publications of Daubney (1936) and Mettam & Ford (1939) are of very great interest. They obtained results resembling the spontaneous condition in cattle by thrusting an agar cylinder containing lymph from infected animals or culture into a blood vessel and so producing embolism. It seems that an additional factor is necessary to render pleuropneumonia-like organisms infective. The admixture of agar with a suspension of organisms has also been used with success by Findlay, Klieneberger, MacCallum & Mackenzie (1938) to produce "rolling disease" in mice with the L5 organism and by one of us (K.) to produce the lesions described by Woglom & Warren (1938*a, b*, 1939) in rats with L4 cultures (Klieneberger, 1939).

The morphology of the L3 organism was described by one of us (K.) in 1938. All strains grow in small colony clumps in the liquid and show the globular pattern very clearly on solid medium. The globules may be small or of medium size in one colony, as shown in Fig. 6, or of very large dimensions in another colony, as shown in Fig. 5. They often contain small granules staining pink with Giemsa; the membranes of the globules contain similar granules. Serologically, the L3 shows no relationship to the two other pleuropneumonia-like species from rats (L1 and L4); but the L3 serum has a slight influence on the organisms from mice (L5 and L6) and on *Asterococcus canis* type I. This can be seen from Table 3 in a paper by one of us (Klieneberger, 1940) which gives the cross-agglutination results of all the different pleuropneumonia-like organisms examined. The sera of rats showing pulmonary lesions were frequently tested with L3 suspensions; the results were always negative. It was attempted also to produce L3 immune sera in young rats by giving them four consecutive injections with increasing amounts of L3 culture. The sera so obtained did not agglutinate any of the L3 suspensions tested.

All kinds of injections of L3 cultures into rats with and without agar have so far not resulted in producing an acute pulmonary disease. It is probable, however, that the adjuvant factor may have to come into more direct contact with lung tissue as in the pleuropneumonia experiments cited above, and further attempts in this direction are contemplated.

As described in 1938, the L3 species is pathogenic for half-grown mice in which it produces abscesses if injected subcutaneously or intraperitoneally. If injected intracerebrally no symptoms result in mice. While 138 L3 strains have been isolated from rats (in most cases from their lungs, in a few cases from their spleens and once from a kidney) only one strain has been isolated from a mouse. This was found in the brain of a normal mouse which had been intracerebrally injected with a sterile starch solution.



SUMMARY

Data are presented which demonstrate a close connexion between the presence of the L3 organism and the pulmonary lesions of rats, but it has not so far been possible to produce the lung infection with the pleuropneumonia-like organism. The cultural and serological features of the L3 organism are given.

REFERENCES

- DAUBNEY, R. (1936). *J. comp. Path.* **48**, 83.
 FINDLAY, G. M., KLIENEBERGER, E., MACCALLUM, F. O. & MACKENZIE, R. D. (1938). *Lancet*, **2**, 1511.
 KLIENEBERGER, E. (1938). *J. Hyg., Camb.*, **38**, 458.
 — (1939). *J. Hyg., Camb.*, **39**, 260.
 — (1940). *J. Hyg., Camb.*, **40**, 204.
 KLIENEBERGER, E. & STEABEN, D. B. (1937). *J. Hyg., Camb.*, **37**, 143.
 METTAM, R. W. M. & FORD, J. (1939). *J. comp. Path.* **52**, 15.
 WOGLOM, W. H. & WARREN, J. (1938*a*). *Science*, **87**, 370.
 — (1938*b*). *J. exp. Med.* **68**, 513.
 — (1939). *J. Hyg., Camb.*, **39**, 266.

EXPLANATION OF PLATE V

- Fig. 1. Lungs and heart of a 5 weeks old rat (weight 50 g.) with acute "bronchopneumonia". Natural size.
 Fig. 2. Lungs and heart of a 4 weeks old rat of healthy appearance (weight 50 g.). Natural size.
 Fig. 3. Upper right lobe and heart of a fully grown rat suffering from "bronchopneumonia" showing the characteristic gelatinous nodules. Natural size.
 Fig. 4. Left lobe of an old rat showing large abscesses. Natural size.
 Fig. 5. L3 organism, strain "72 lung", isolated from lung lesions of a rat. One whole small colony composed of large globules. Agar fixation method, Bouin-Giemsa. Mag. 600.
 Fig. 6. L3 organism, strain "5254", isolated from lung lesions of a rat. Part of a stained colony showing many small globules. Agar fixation method, Bouin-Giemsa. Mag. 600.

(Received for publication 25. I. 40.—Ed.)