

# RETINAL RENAL DYSPLASIA AND ENCEPHALOPATHY IN A PATIENT WITH TRIGLYCERIDE STORAGE DISEASE

M. PHILIPPART, W. DEN TANDT, C. BORRONE, P. DURAND

III Medical Division, "G. Gaslini" Hospital, Genoa, Italy; and Neuropsychiatric Institute,  
University of California, Los Angeles, USA

---

*A 10-year-old girl with tapetoretinal degeneration, renal dysplasia similar to juvenile nephrophtisis, gradually increasing mental deterioration, walking incoordination, obesity, and ichthyosis is reported.*

*Histochemical analyses of the liver, spleen, intestine, lungs, myocardium, kidney, and brain, showed a glycolipid storage. A triglyceride storage in the liver was identified.*

*Triglyceride lipase activity was about 1% and acid lipase activity 10% with respect to normal controls.*

*A genetic factor, rather than a secondary metabolic inhibition of triglyceride lipase, is indicated by the normal activity of this enzyme in fatty liver from patients with Reye's syndrome and alcoholic cirrhosis. No inhibitor was found in triglyceride storage disease.*

---

## INTRODUCTION

The association of tapetoretinal degeneration (TRD) with chronic tubulointerstitial nephropathy (TIN) was described first by Contreras and Espinoza in 1960.

In 1961 Senior et al. reported a case and suggested to distinguish a new inherited disorder.

Since then, more than 20 patients with this disorder have been reported in the literature. The renal-retinal dysplasia was associated with hepatomegaly, mental and motor deterioration, deafness, seizures, and also with ichthyosis and skeletal dysplasia.

Fontaine et al. (1970) reported a patient in which were present cytoplasmatic vacuolation and ballooning cells in liver and retina. He had also hepatomegaly and hyperlipidemia.

It is more likely that three familial cases of Alström (TRD, deafness, obesity, diabetes mellitus, ichthyosis) with a TIN, may have a quite similar disease (Goldstein et al. 1971).

Martin et al. (1968) referred detailed studies of pathologic features and suggested that the disease is associated to an inborn error of metabolism. Schimke (1969), describing another case, emphasized that the responsible biochemical defect is a disorder of lipid metabolism.

In 1971 Durand et al. reported a young girl with the same disease. She died when 10 years and 3 months old. Histochemical analyses of the viscera showed a generalized lipid storage.

In the present paper we report the results of lipid analyses and the deficient activity of acid lipase in this previously reported case.

Proc. 4th Int. Congr. Neurogenet. Neuroophthalmol. (1973)

*Acta Genet. Med. Gemellol. (Roma)*, 23: 201-203

© 1974

## CASE REPORT

The patient (Maria D.) was admitted to the Gaslini Hospital at the age of 8 years and 4 months because of progressive motor and mental retardation, obesity, and ichthyosis.

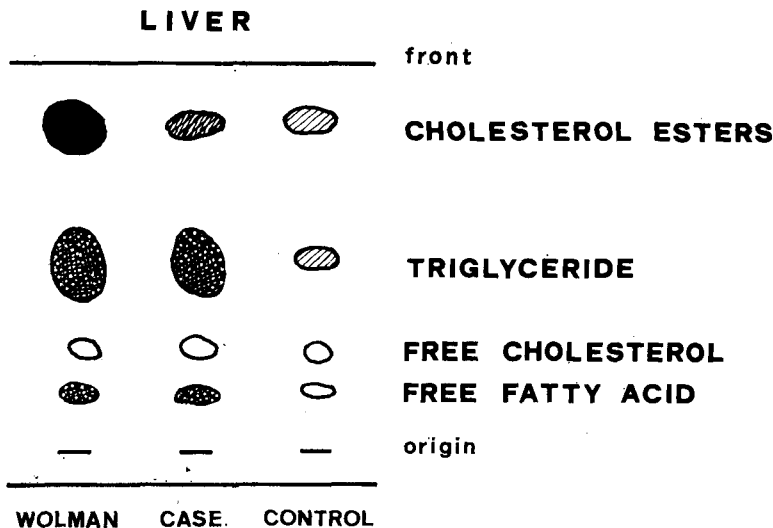
During the two hospitalizations she presented: decreased vision secondary to TRD, deafness, mental deterioration and incoordination, major seizures with EEG showing irregular activity, obesity, delay in growth and osseous development, hepatomegaly with hyperlipemia (22 g/l), and increased values of neutral fat (7.6 g/l) and cholesterol (3.6 g/l), diabetic glucose tolerance curve without ketonuria, ichthyosis, advanced renal disease characterized by progressive hyperazotemia, failure to concentrate and acidify the urine, hypertension, slight proteinuria, glycosuria, hyperphosphaturia, hyperaminoaciduria.

During the second hospitalization the patient continued to deteriorate. Frequent respiratory tract infections occurred. Furthermore, the liver became painful and jaundice developed. Abnormal liver function test with hyperbilirubinemia (5 g/l, 3.8 of which were of conjugated bilirubin) were present at this time. Depigmentation and partial loss of hair occurred. The renal failure, the mental and motor deteriorations, worsened progressively. The girl died at the age of 10 years and 3 months.

*Pathological Findings*

The macroscopic examination showed an unusual orange appearance especially of the liver, intestine, and the heart, and to a lesser degree of the other viscera.

The liver (1850 g), the heart (250 g), were considerably hypertrophied; the lungs (566 g) showed an



increased consistency; gross examination of the kidneys revealed a generalized atrophy, especially cortically (left 42 g and right 52 g).

Histological and histochemical examination of the liver showed lipid droplets in all hepatic parenchymal cells; the droplets were of different size. Foamy cells and vacuolisation occurred in all viscera, but especially lungs, myocardium, intestine, and kidneys showed lipid storage.

All cells stained intensely with neutral lipid stains, oil red O, and Sudan III; the Schultz stain for cholesterol was also strongly positive.

Various systemic degenerations of the optic pathways, neuronal losses in the cerebral cortex, and also lipidic retention in the cortical neurons, were found.

The histological examination of the kidneys showed that the glomeruli were partially or markedly

hyalinized with thickening of basal membrane. The tubules presented various degree of atrophy and cystic dilatation. Interstitial periglomerular and peritubular fibrosis with marked arteriolar sclerosis were present. The ultrastructural examination confirmed the thickening and coalescence of glomerular basal membrane.

On the whole, the histologic and ultrastructural findings were interpreted as an end-stage of interstitial nephritis with arteriolar and arterial nephrosclerosis, compatible with the clinical diagnosis of juvenile nephronophthisis.

#### *Biochemical Findings*

Fatty liver was obtained from the patient, and triglyceride storage was found. Control livers included normal autopsy material and cases of Reye's syndrome, alcoholic cirrhosis, Wolman's disease, and cholesterol ester storage disease.

Triglyceride lipase activity, using 1-14 C-trioleate, was about 1% of normal, and acid lipase activity, using o-nitrophenilpalmitate, was 10% of normal.

A genetic factor, rather than a secondary metabolic inhibition of triglyceride lipase, is indicated by the normal activity of this enzyme in fatty liver from Reye's syndrome and alcoholic cirrhosis. No inhibitor was found in triglyceride storage disease.

These findings suggest that this disease, except for the lack of overt accumulation of cholesterol esters, is very similar to Wolman's disease.

#### REFERENCES

- Contreras B.C., Espinoza S.J. 1960. Discussion clinica y anatomopatologica de enfermos que presentaron un problema diagnostico. *Pediatr. (Santiago)*, 3: 271.
- Den Tandt W.R., Philippart M., Nakatani S., Durand P. 1973. Triglyceride and acid lipase deficiency in triglyceride storage disease, a possible variant of Wolman's disease. *Pediatr. Res.*, 7: 346-118.
- Durand P., Bugiani O., Palladini C., Borrone C., Della Cella G., Siliato F. 1971. Néphropathie tubulointerstitielle chronique, dégénérescence tapéto-rétinienne et lipidose généralisée. *Arch. Fr. Pédiatr.*, 28: 915.
- Fontaine J.L., Boulesteix J., Saraux H., Lasfargues G., Grebet P., N'Ghiem-Minh Dung, Dhermy P., Roy C., Laplane R. 1970. Néphropathie tubulointerstitielle de l'enfant avec dégénérescence tapéto-rétinienne (Syndrome de Senior). A propos d'une observation. *Arch. Fr. Pédiatr.*, 27: 459.
- Goldstein J.F., Fialkow P.J., Fraser G.R., Striker G.E. 1971. Alström's syndrome: a heretofore unrecognized cause of hereditary nephropathy. *Rap. 4ème Congr. Int. Génétique Humaine, Paris 1971*. [p. 80]. Amsterdam: Excerpta Medica.
- Martin L., Martin J.J., Guazzi G.C., Lowenthal A., Maniewski J. 1968. Dégénérescence tapéto-rétinienne, surdité, myoclonies, démence, épilepsie avec présence d'ac.  $\alpha$ -amino-n-butirique en excès. Contribution à l'étude des angiomatoses leptomeningées avec leucodystrophie soudanophile et abiotrophies complexes. *J. Neurol. Sci.*, 6: 217.
- Schimke R.N. 1969. Hereditary renal-retinal dysplasia. *Ann. Intern. Med.*, 70: 735.
- Senior B., Friedman A.I., Braudo J.L. 1961. Juvenile familial nephropathy with tapeto-retinal degeneration. A new oculo-renal dystrophy. *Am. J. Ophthalmol.*, 52: 625.

Prof. Paolo Durand, Istituto G. Gaslini, Via 5 Maggio, 16147 Genova Quarto, Italy.