

# Pyogenic Ventriculitis as Clinical Presentation of Diverticulitis

Charlotte Dandurand, Laurent Letourneau, Chiraz Chaalala, Elsa Magro, Michel W. Bojanowski

**Keywords:** brain abscess, Diverticulitis, liver abscess, *Streptococcus anginosus*, *Streptococcus intermedius*, Ventriculitis

doi:10.1017/cjn.2016.4

Can J Neurol Sci. 2016; 43: 576-577

A 51-year-old male was brought to the emergency room with fever and depressed consciousness. The family reported a 3-day history of asthenia, myalgia, stiffness of the neck, chills, and confusion. His medical history was relevant for chronic alcohol abuse and gout. On physical examination, the patient was febrile (39.2°C), hypertensive, and tachypneic. He was unconscious with no focal neurological deficits.

Urgent noncontrast computed tomography (CT) scan showed hydrocephalus with trans-ependymal edema with sparing of the fourth ventricle. The patient was intubated and an external ventricular drain was urgently inserted, which drained obviously purulent cerebrospinal fluid (CSF). The patient was started on a broad-spectrum antimicrobial therapy, which was later readjusted because CSF and blood cultures grew *Streptococcus intermedius*. The brain magnetic resonance imaging (Figure 1) scan revealed severe ventriculitis evidenced by intraventricular debris, intense enhancement of the ependymal lining of the ventricles associated with periventricular cerebritis, and multiple bilateral brain microabscesses.

A chest and abdomen CT scan performed to search for a primary infection revealed a perforated diverticulitis complicated

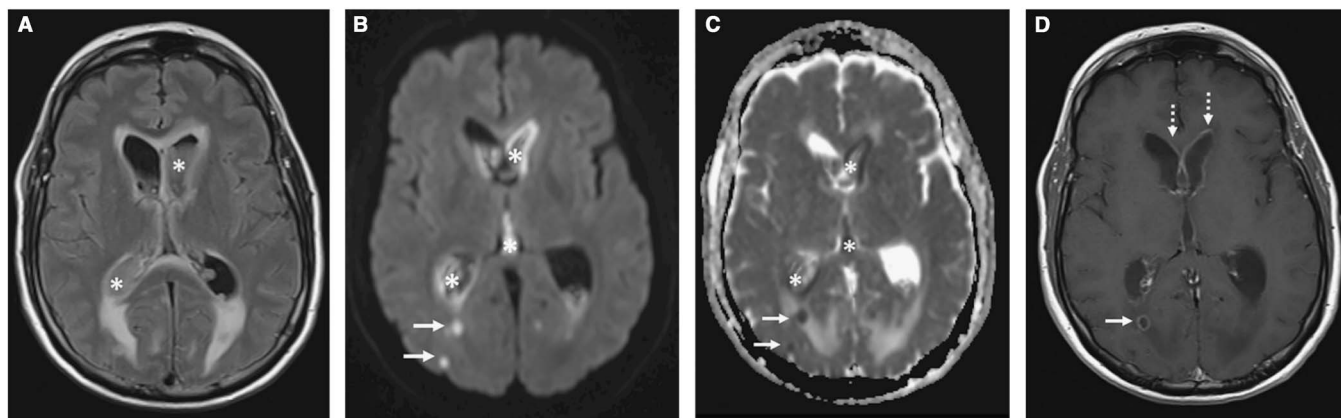
by multiple liver abscesses that were subsequently drained percutaneously.

During hospitalization, the patient eventually developed multiloculated hydrocephalus that required multiple drains and finally a ventriculopleural shunt after endoscopic fenestration of the ventricular septations. The patient improved remarkably and was awaiting rehabilitation when he suddenly died of a respiratory complication.

## DISCUSSION

Central nervous system infection is a very rare complication of diverticulitis.<sup>1-4</sup> To our knowledge, no case of purulent ventriculitis has been reported resulting from diverticulitis.

Although the *Streptococcus anginosus* group (*S. anginosus*, *S. intermedius*, and *Streptococcus constellatus*) is part of the normal gastrointestinal flora, it is rarely implicated in disseminated infections originating from a diseased colon.<sup>5</sup> When this is the case, multiple organs can be affected, most commonly the liver and the lungs.<sup>6</sup> Alcoholism is a risk factor for such dissemination.<sup>7</sup>



**Figure 1:** Brain magnetic resonance imaging; axial fluid-attenuated inversion recovery (FLAIR) (A), diffusion-weighted imaging (B), apparent diffusion coefficient map (C), and T1 postgadolinium (D) images reveal intraventricular purulent material with a higher signal than CSF in FLAIR and diffusion restriction (asterisks in A-C). Intraparenchymal abscesses were also identified as rim-enhancing lesions with diffusion restriction within their centers (arrows in B-D). Ependymal enhancement related to ventriculitis was better demonstrated within both frontal horns (dashed arrows in D).

From the Divisions of Neurosurgery (CD, CC, EM, MWB); Neuroradiology (LL), Division of Surgery, Centre Hospitalier de l'Université de Montréal, Québec, Canada.

RECEIVED MARCH 26, 2015. FINAL REVISIONS SUBMITTED NOVEMBER 23, 2015. DATE OF ACCEPTANCE NOVEMBER 25, 2015.

Correspondence to: Michel W Bojanowski, Division of Neurosurgery, Hôpital Notre Dame 1560 Sherbrooke Est, Montréal, Québec, Canada, H2L 4M1. Email: michel.bojanowski.chum@ssss.gouv.qc.ca

Even though the *S. anginosus* group is a common pathogen in brain abscesses,<sup>8,9</sup> it usually spreads contiguously from sinusitis or mastoiditis, which often develops into a single brain abscess. Only two cases of *S. anginosus* brain abscesses resulting from diverticulitis, though not ventriculitis, have been reported in the literature.<sup>1,3</sup>

*S. intermedius* has an apparent tropism for the brain and liver.<sup>6</sup> This characteristic can be explained by the difference of virulence factors produced by the *S. anginosus* group species.<sup>7</sup> *S. intermedius* produces the enzymes  $\alpha$ -N-acetylneuraminidase (sialidase), a growth factor, and hyaluronidase, which destroy host tissues. *S. constellatus* produces only hyaluronidase. *S. anginosus* produces neither. Also critical for the pathogenicity of *S. intermedius* is the involvement of hyaluronidase in the formation of biofilm that protects it from host defenses and antibiotics.<sup>7</sup>

### CONCLUSION

Purulent ventriculitis can be a complication of diverticulitis. *S. intermedius*, found in normal intestinal flora, has an affinity for invading the brain. Isolation of *S. intermedius* from CSF should raise suspicion for an abdominal source of infection. Consequently, this widens the spectrum of possible sources a neurosurgeon has to consider when a patient presents with ventriculitis.

### DISCLOSURES

None of the authors has anything to disclose.

### REFERENCES

1. Kamath V, Mishra N, Gunabushanam V, et al. Nervous system abscess: a rare complication of diverticulitis. *Color Dis.* 2011; 13:420-1.
2. Valero M, Parés D, Pera M, Grande L. Brain abscess as a rare complication of acute sigmoid diverticulitis. *Tech Coloproctol.* 2008;12:76-8.
3. Dixon a R, Holmes JT, Waters a. Intracranial abscess complicating diverticulitis with CT scan mimicking primary glioma. *Postgrad Med J.* 1989;65:565-7.
4. Brewer NS, MacCarty CS, Wellman WE. Brain abscess: a review of recent experience. *Ann Intern Med.* 1975;82:571-6.
5. Byrnes MC, Mazuski JE. Antimicrobial therapy for acute colonic diverticulitis. *Surg Infect.* 2009;10:143-54.
6. Giuliano S, Simone G, Rubini G, et al. Streptococcus anginosus group disseminated infection: case report and review of literature. *Le Infez Med.* 2012;20:145-54.
7. Mishra AK, Fournier P-E. The role of Streptococcus intermedius in brain abscess. *Eur J Clin Microbiol Infect Dis.* 2013;32:477-83.
8. Mofredj A. Streptococcus anginosus (milleri) septicemia: interest in systematically searching for parenchymatous abscesses. *Diagn Microbiol Infect Dis.* 1999;33:205-6.
9. Colnot F, Alexandre JL, Arnaudo JP, et al. [Parenchymatous abscesses in septicemia caused by Streptococcus anginosus (Streptococcus milleri); interest in systematically searching for them, report of 4 cases]. *Rev Med Interne.* 1994;15:715-9.